


CRANEOESTENOSIS VISION DEL RADIÒLOGO PEDIATRA

DR. LUIS FERNANDO GENTILE


CRANEOESTENOSIS

- ▶ Cierre prematuro de suturas sindrómico o no sindrómico
- ▶ Objetivos de las imágenes:
 - I. Sutura visible
 - II. Plan quirúrgico
 - III. Seguimiento




ROL DIAGNOSTICO POR IMAGENES

- ▶ RX CRANEO
- ▶ ECOGRAFIA CEREBRAL
- ▶ TC
- ▶ RM




IMÁGENES :

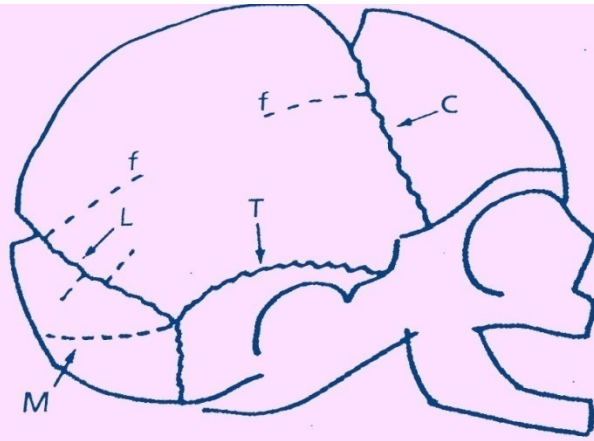
- ▶ Demostrar crecimiento paralelo o perpendicular a la sutura
- ▶ Rx : puente óseo o tabla interna festoneada.
- ▶ Medicina nuclear : baja sensibilidad y especificidad.
- ▶ TC : demuestra escafocefalia , trigonocefalia , plagiocefalia, braquicefalia, turricefalia , especialmente con la técnica de reconstrucción.



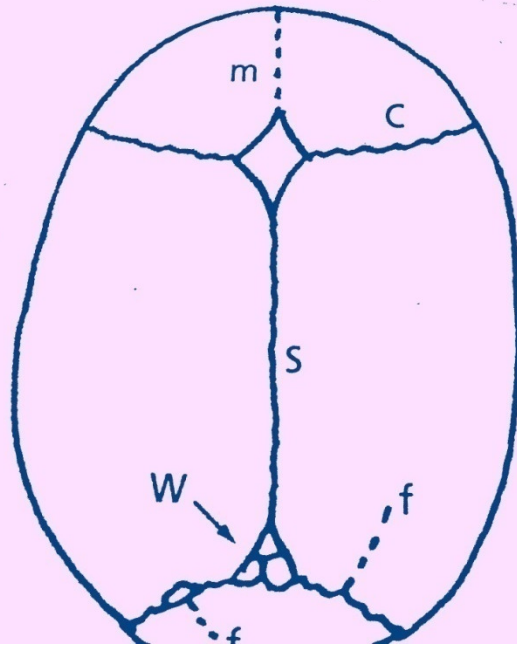
Cierre precoz

- ▶ Sutura sagital = Dolicocefalia
- ▶ Sutura lambdoidea = Braquicefalia
- ▶ Plagiocefalia



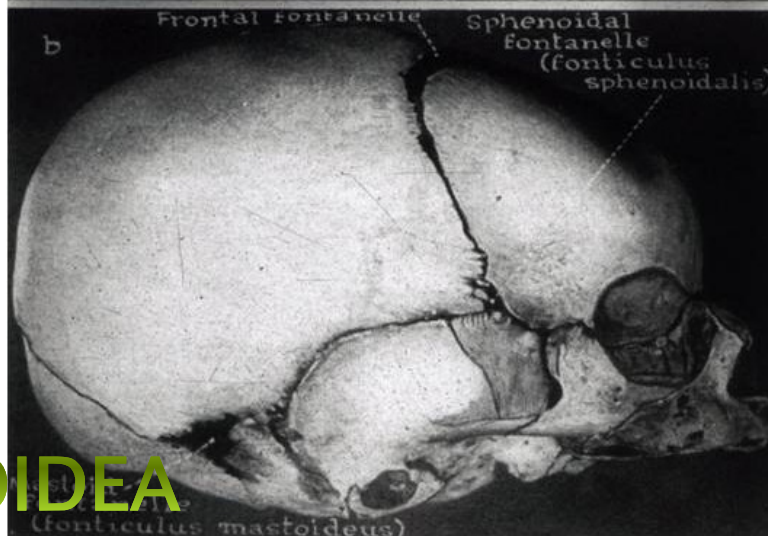
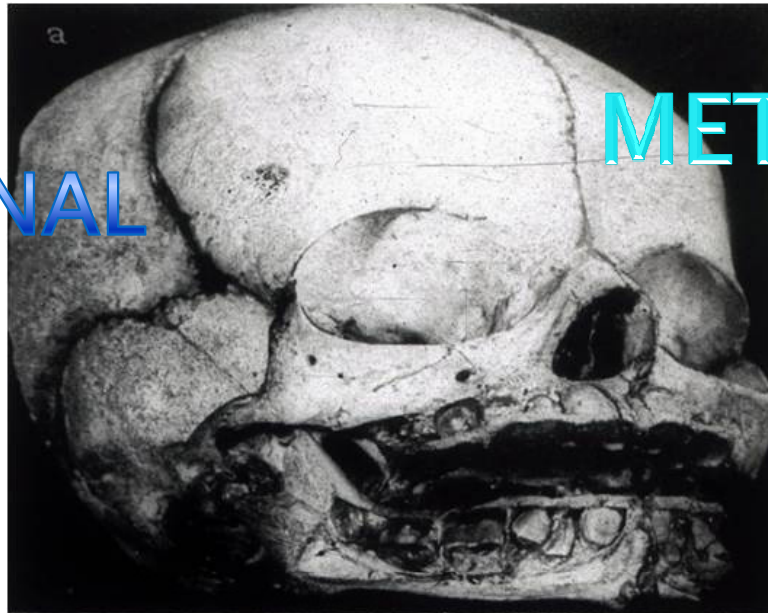

a




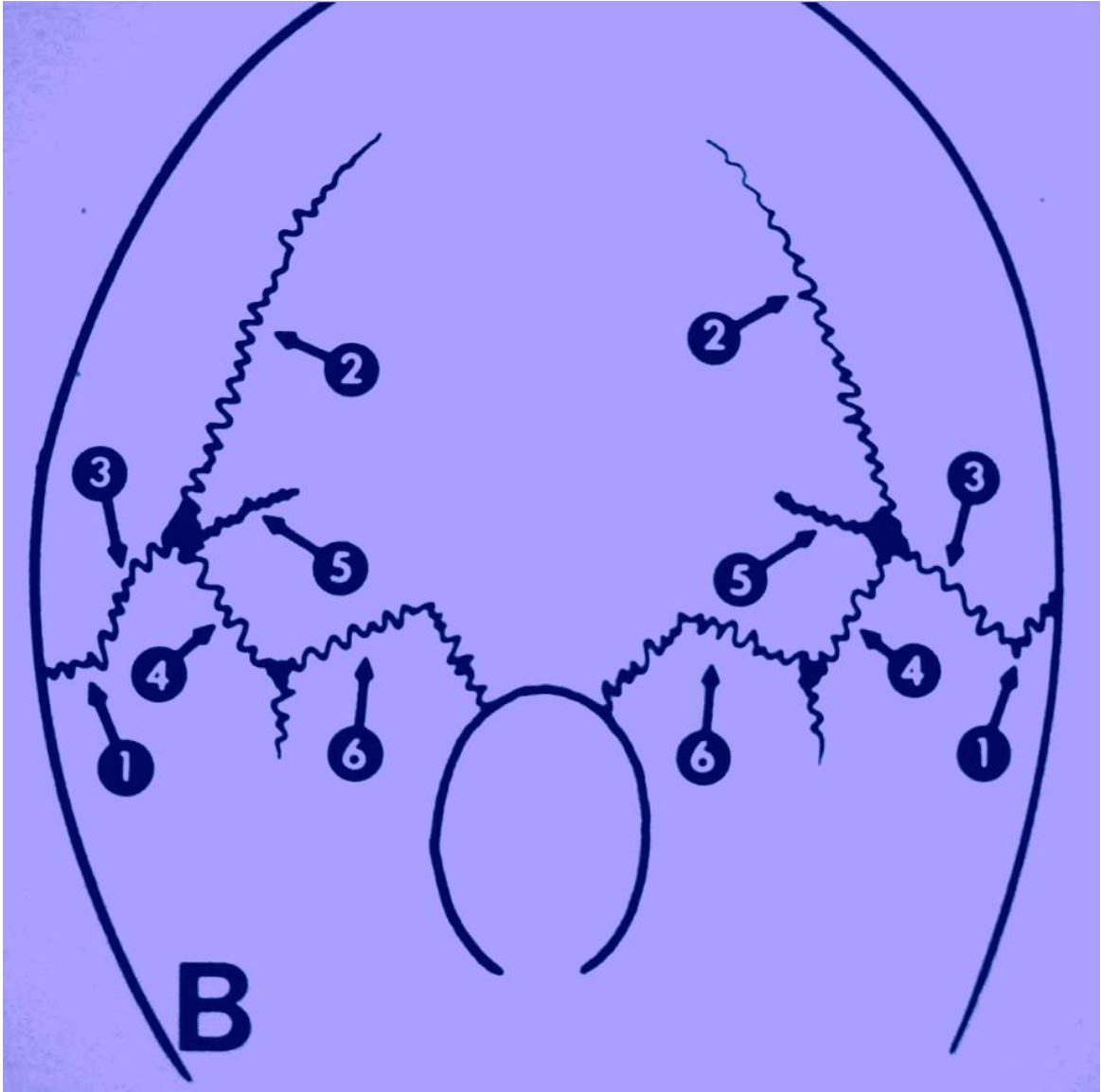
CORONAL


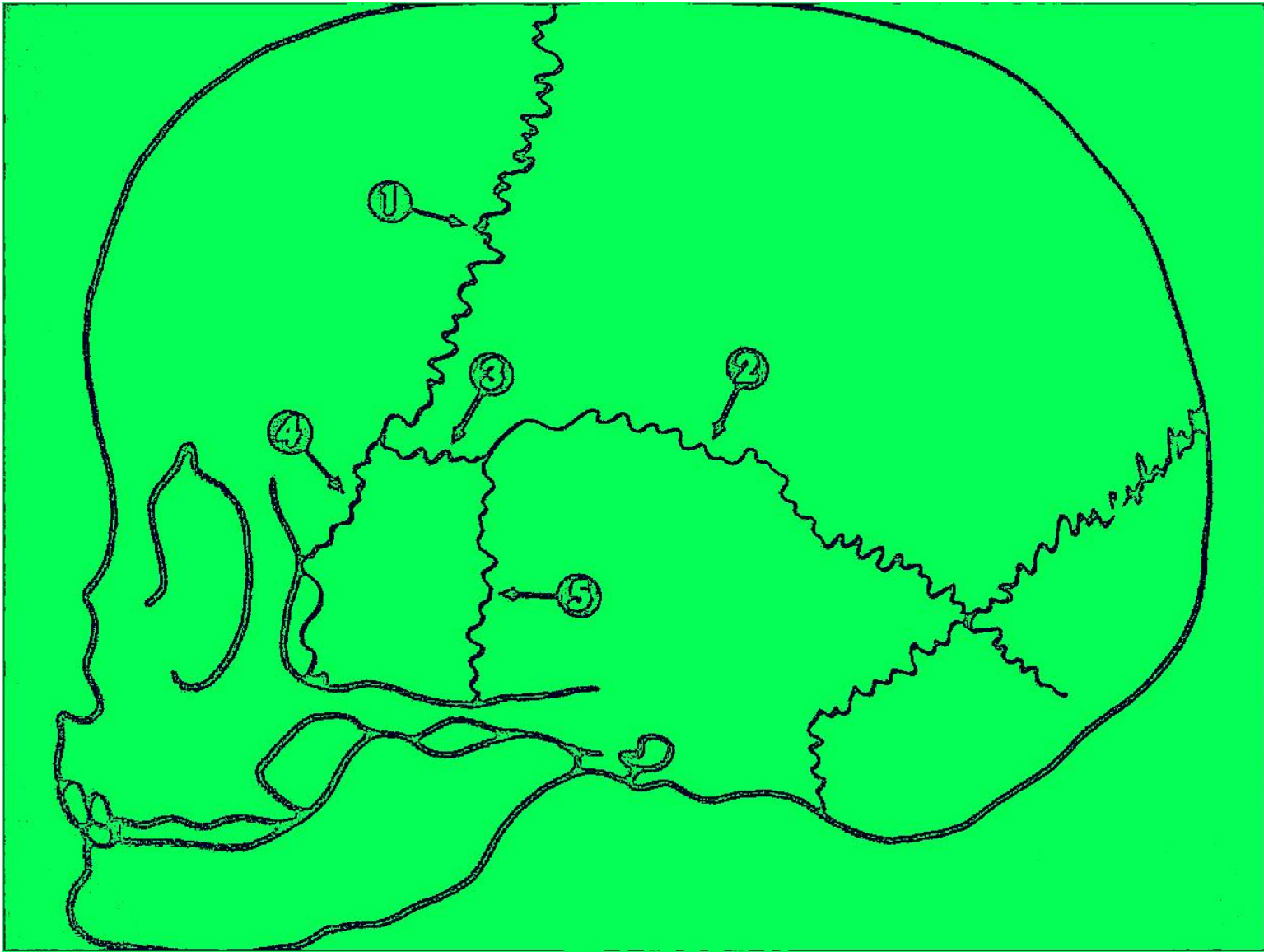
METOPICA



LAMBDOIDEA

SUTURAS





1 1/2 años - 2 años

ANTERIOR

POSTERIOR

3 meses

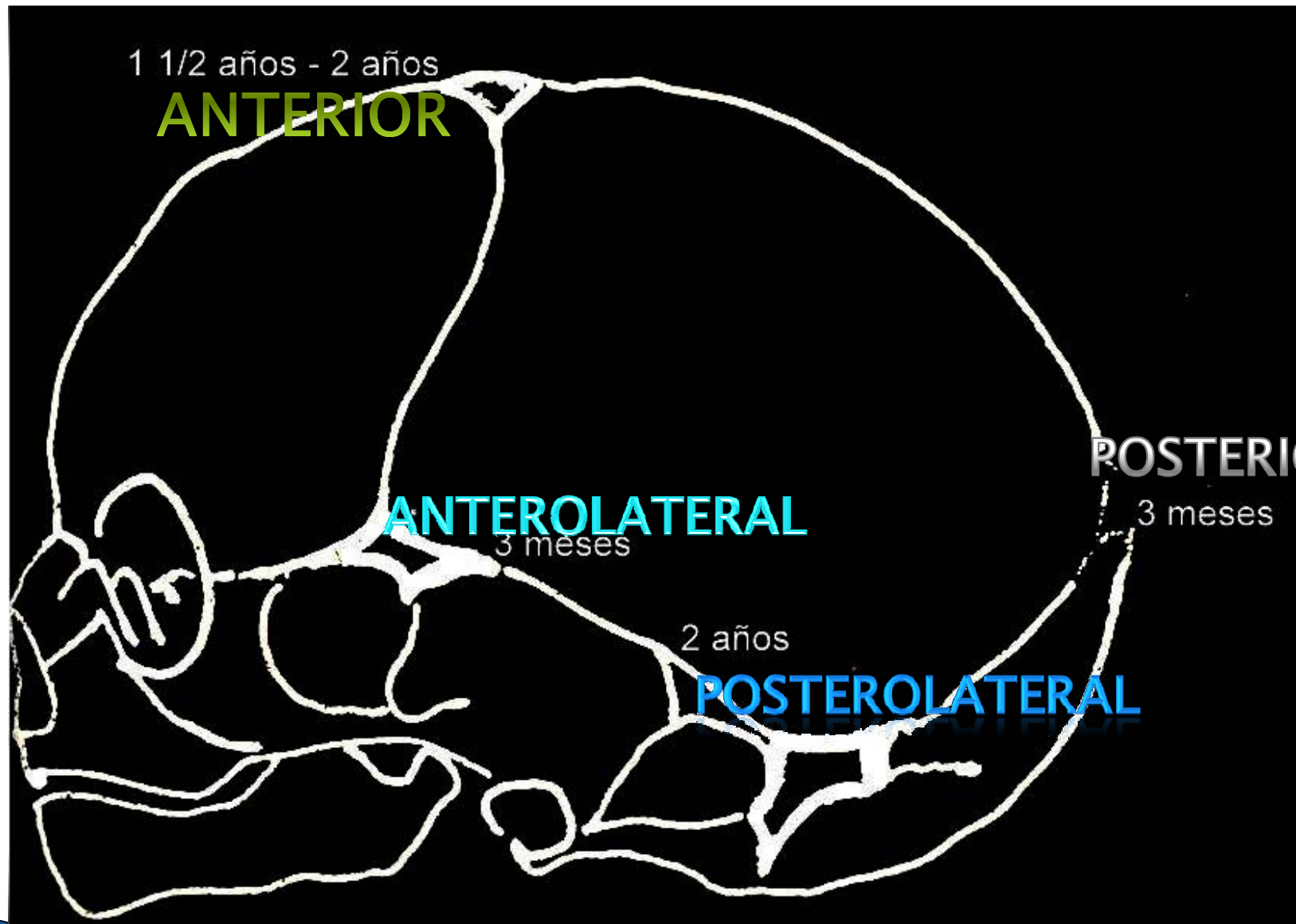
ANTEROLATERAL


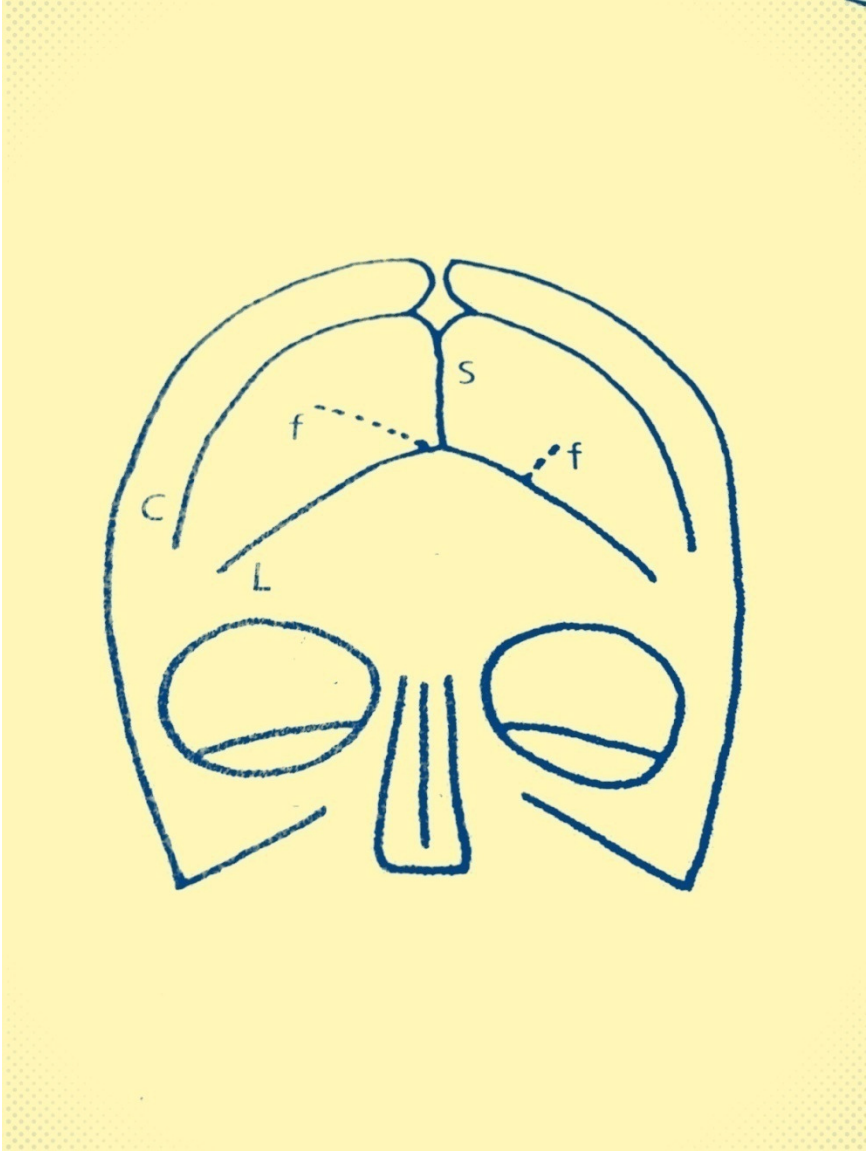
3 meses


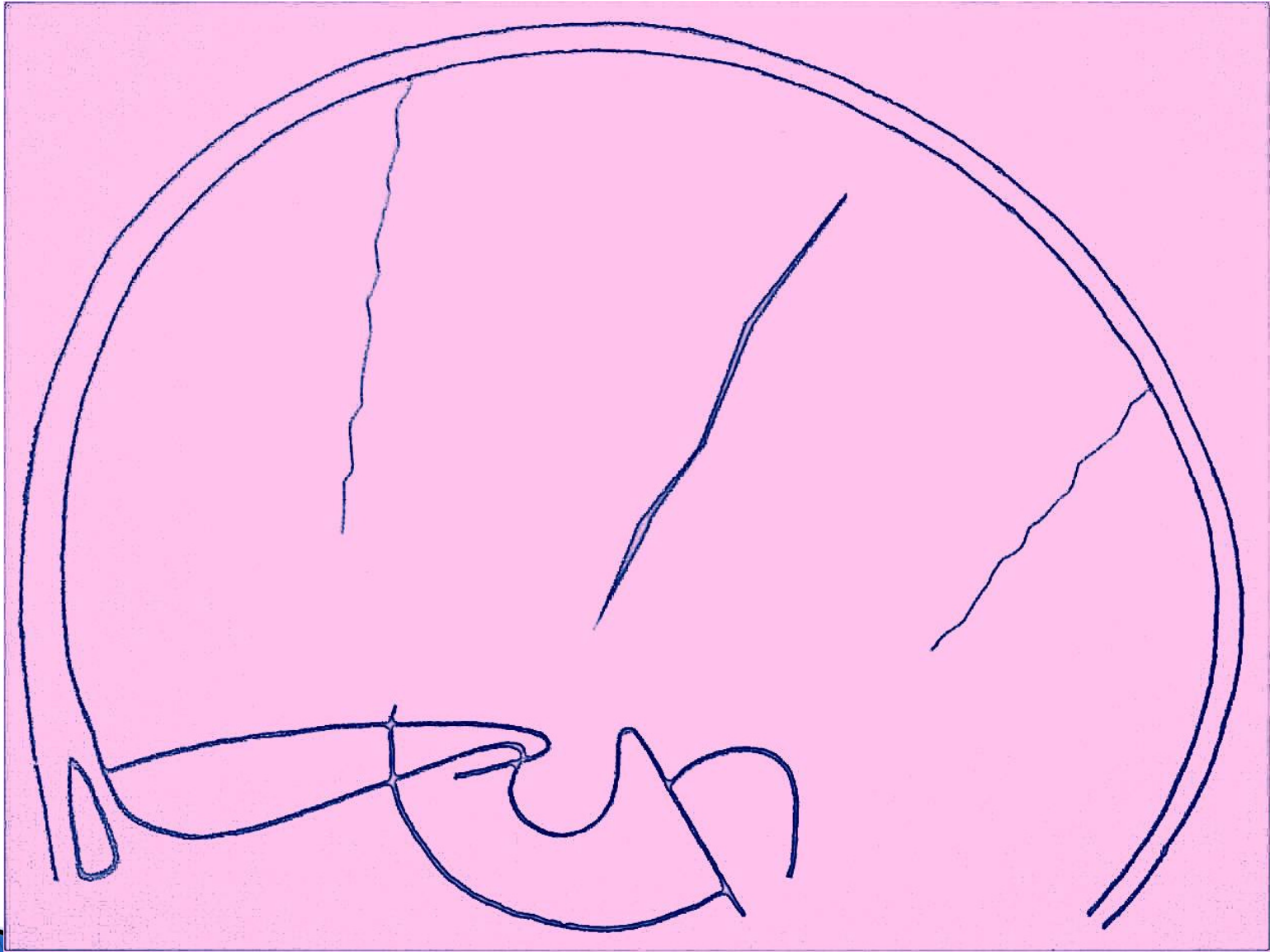
2 años

POSTEROLATERAL

FONTANELAS






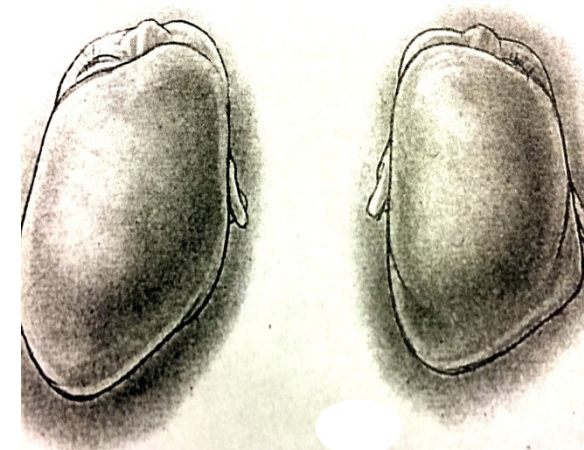


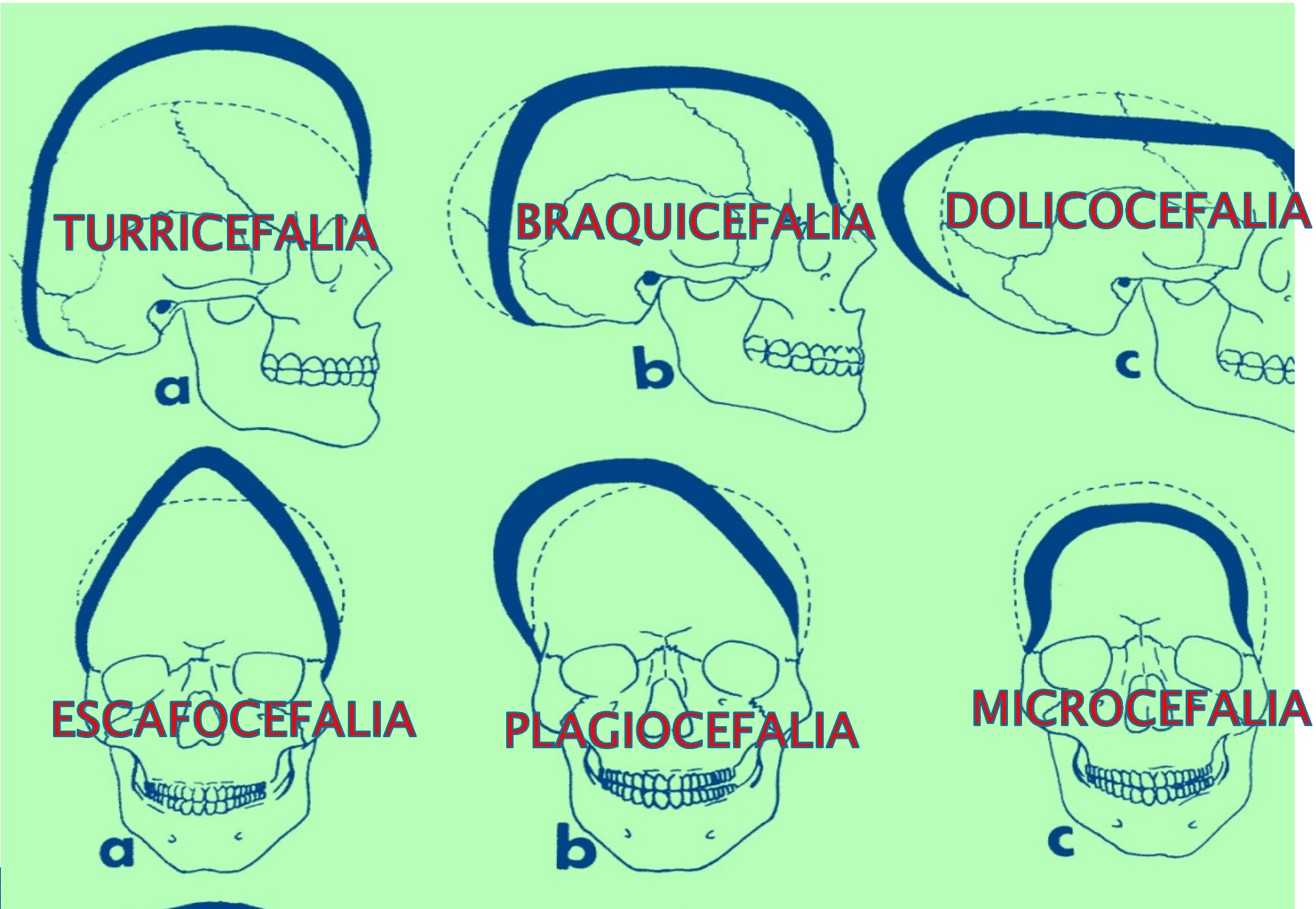
DESAFIO

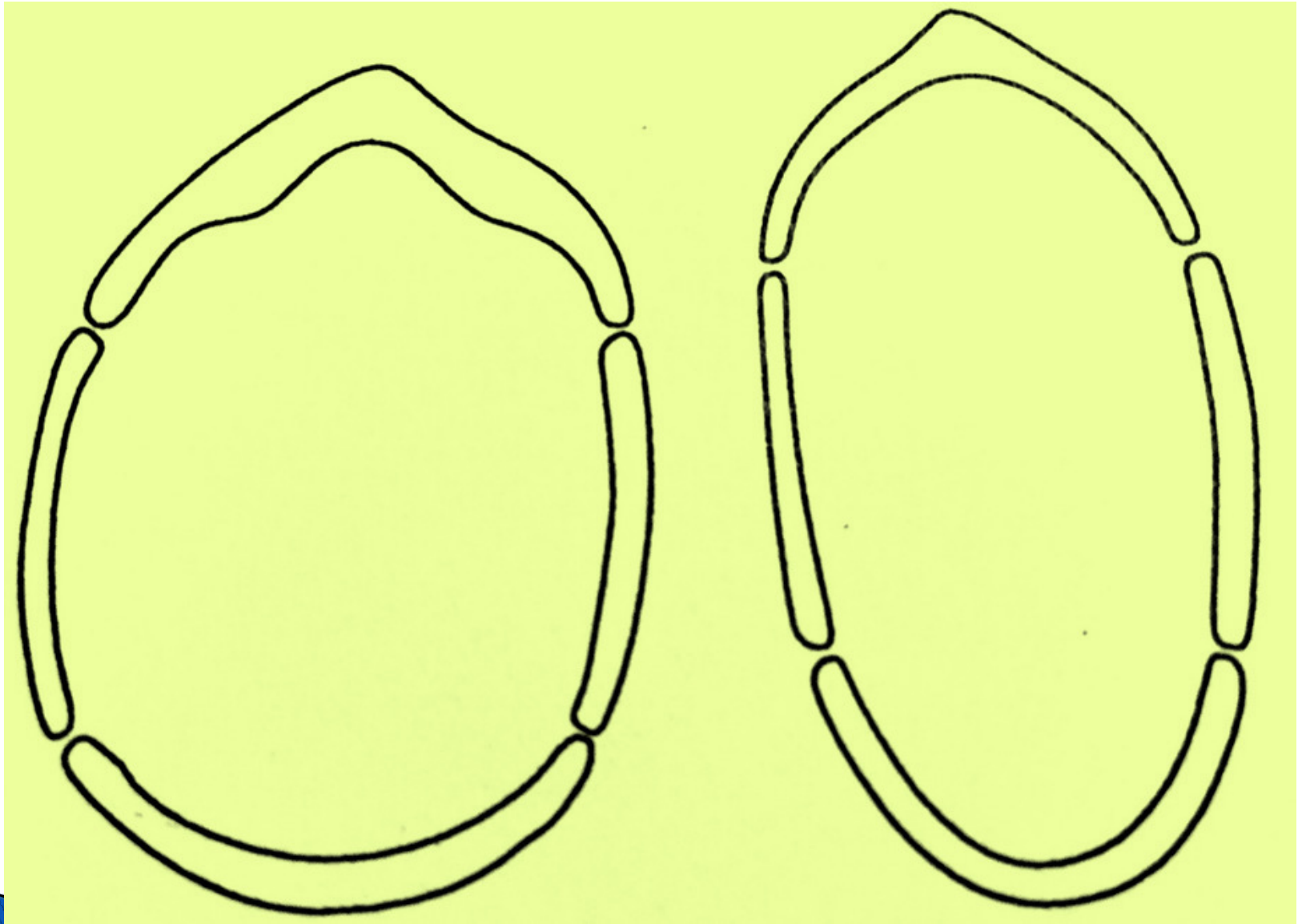
- ▶ Distinguir plagiocefalia posicional de
 - ▶ Anomalía por cierre de suturas

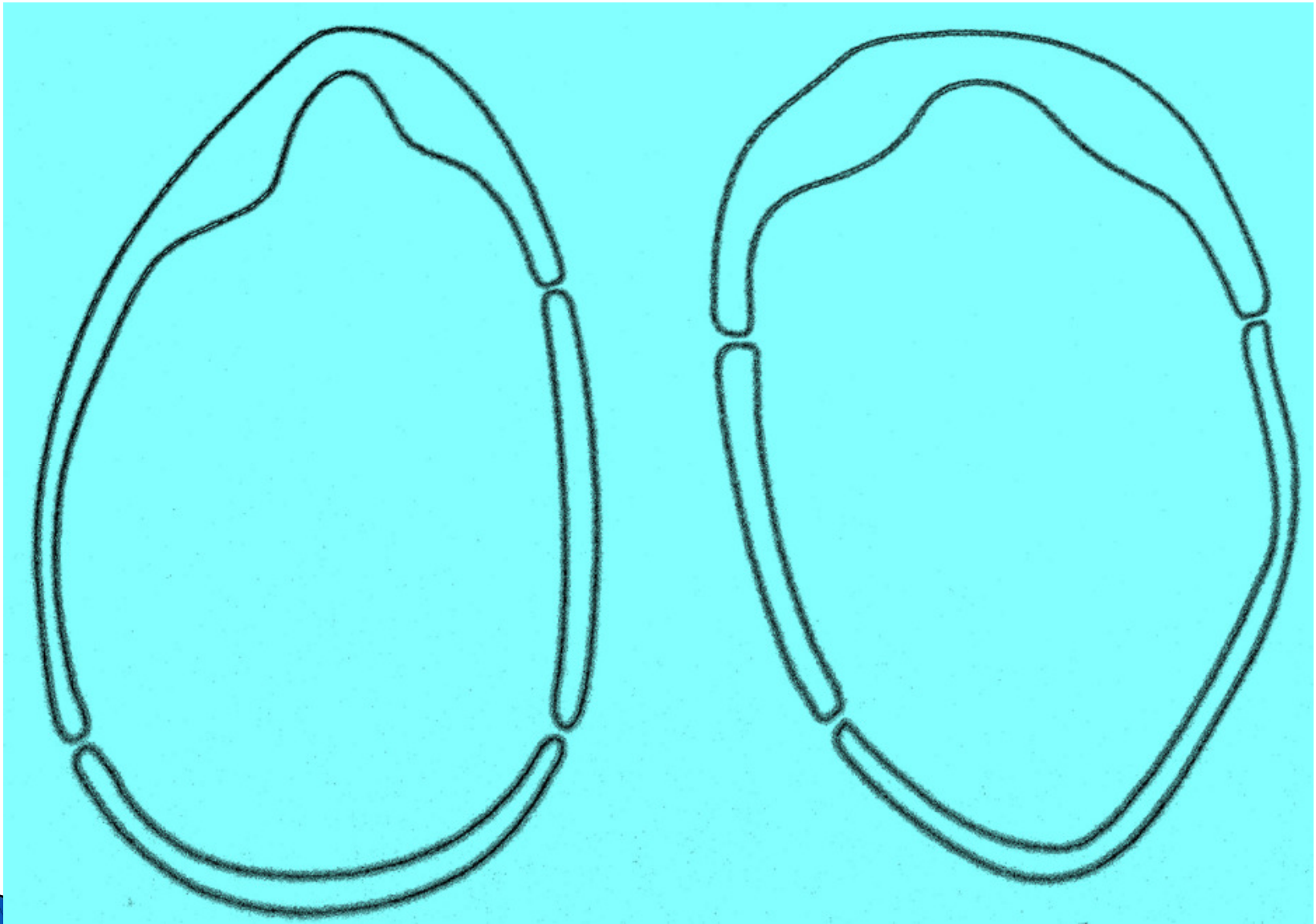


	PLAGIOCEFALIA POSICIONAL	CRANEOESTENOSIS
ABOMBAMIENTO FRONTAL	MISMO LADO QUE EL APLASTAMIENTO POSTERIOR	AUSENTE O CONTRALATERAL A APLASTAMIENTO POSTERIOR
ABOMBAMIENTO POSTERIOR	AUSENTE	CONTRALATERAL A APLASTAMIENTO POSTERIOR Y LOCALIZACION PARIETAL
OREJA DEL MISMO LADO	DESPLAZADA HACIA ADELANTE	DESPLAZADA HACIA ATRÁS, HACIA LA SUTURA CERRADA
PUENTE OSEO DENSO	AUSENTE	FRECUENTEMENTE PRESENTE


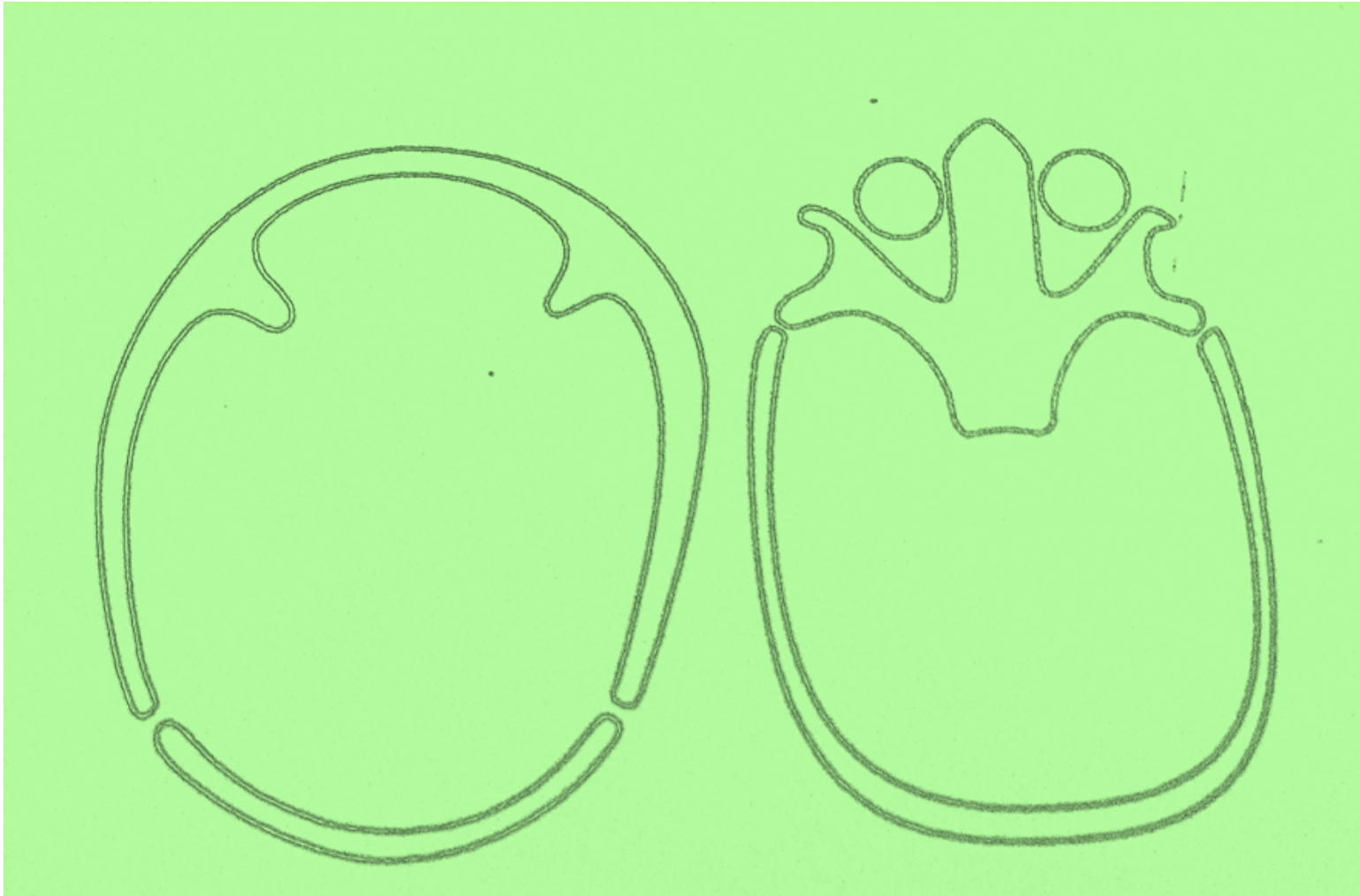











IMG_2890






- ▶ Plagiocefalia posicional = Orejas adelante
- ▶ Cierre de suturas = orejas atrás



Abombamiento frontal


- ▶ Del mismo lado = plagiocefalia posicional
- ▶ Opuesto a la sutura = cierre en los casos patológicos



SINDROMES

- CROUZON

- APERT



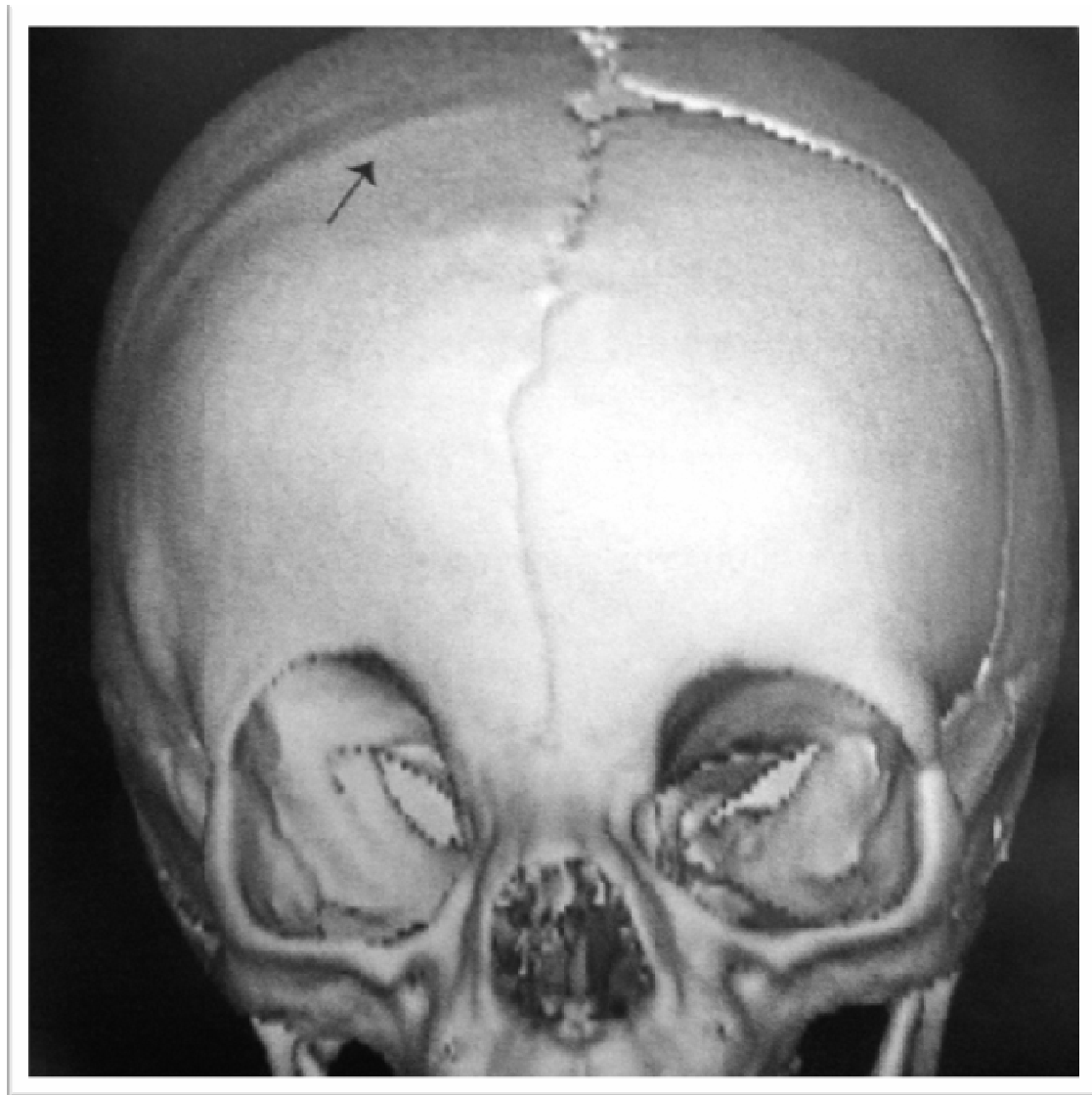

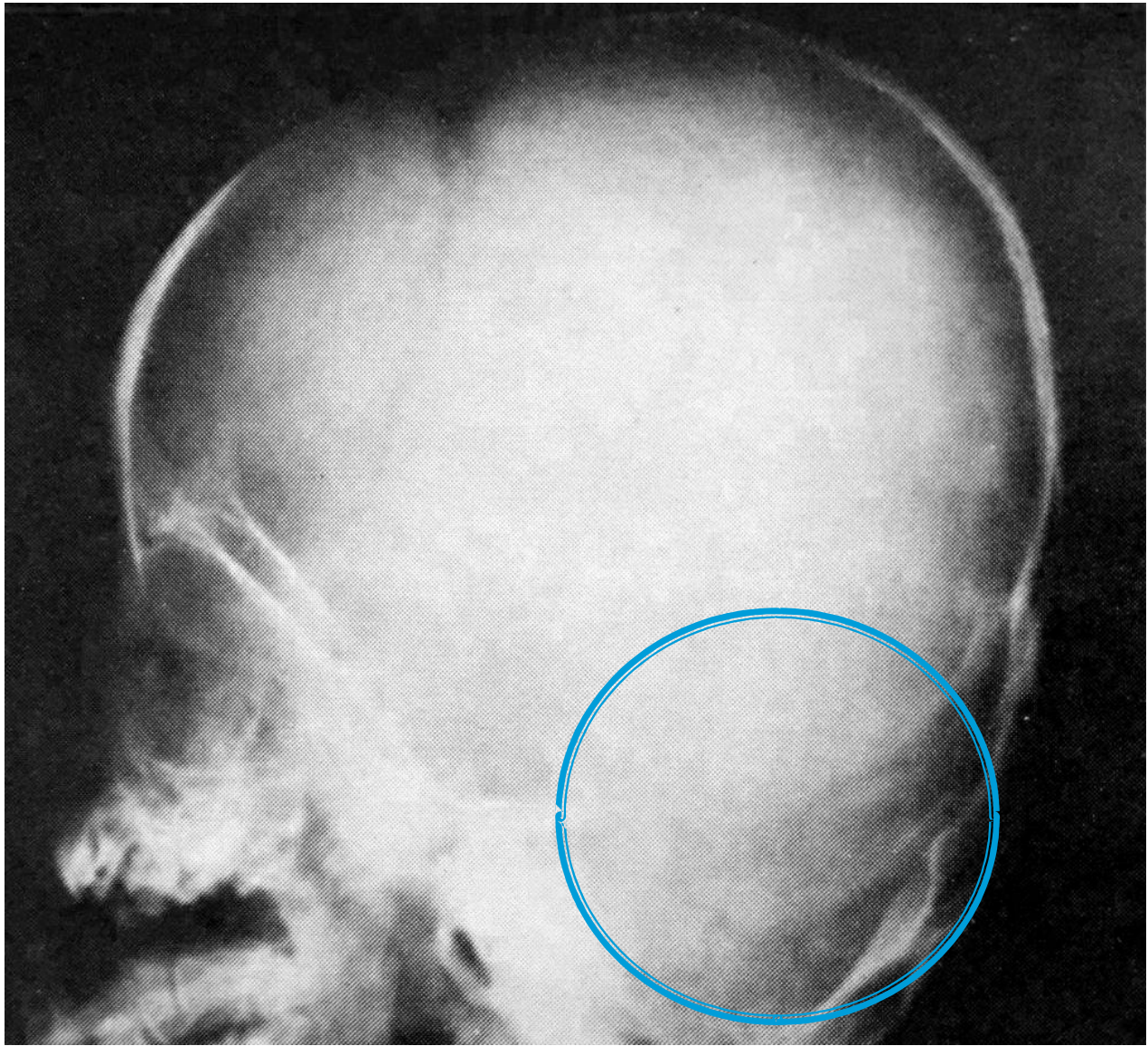

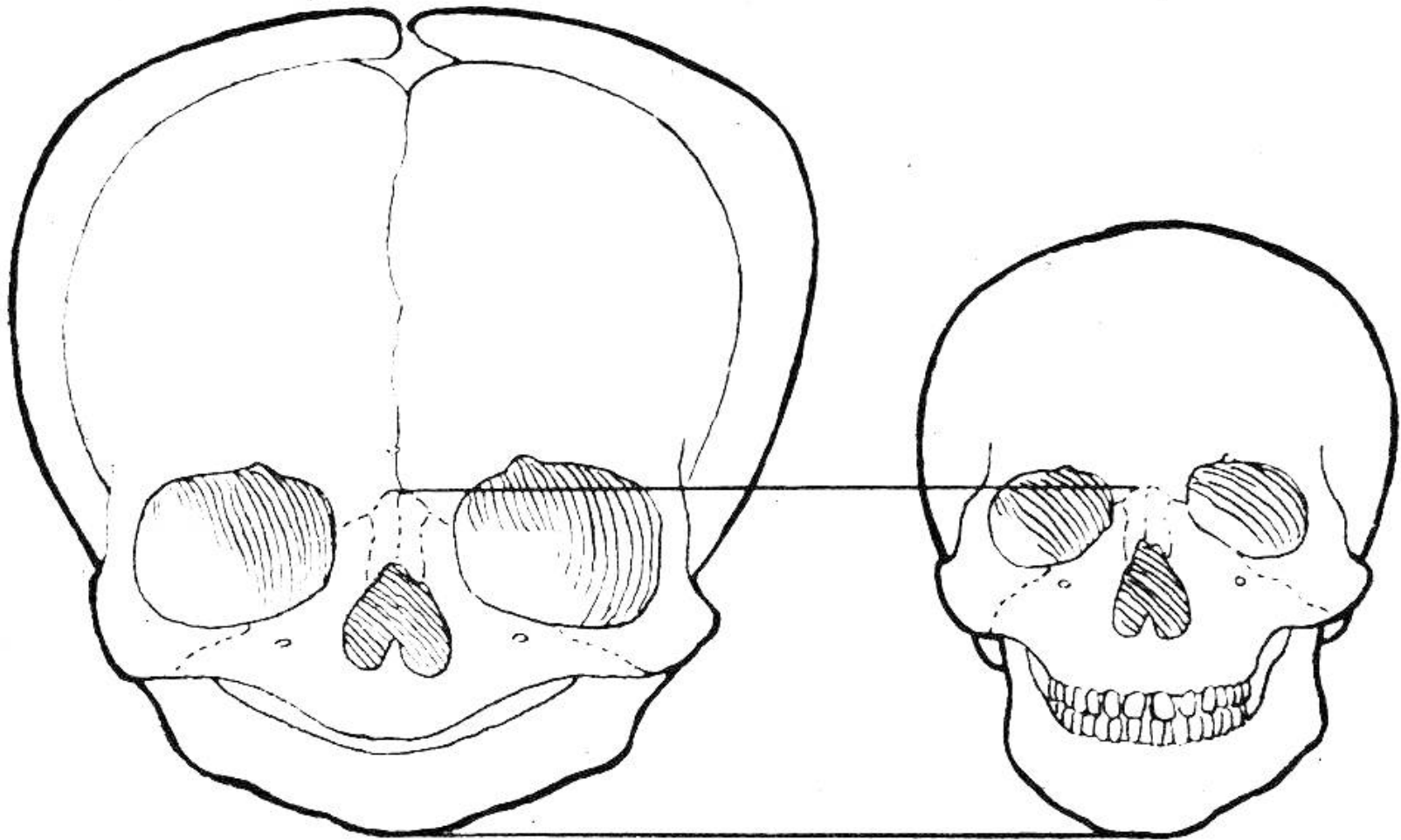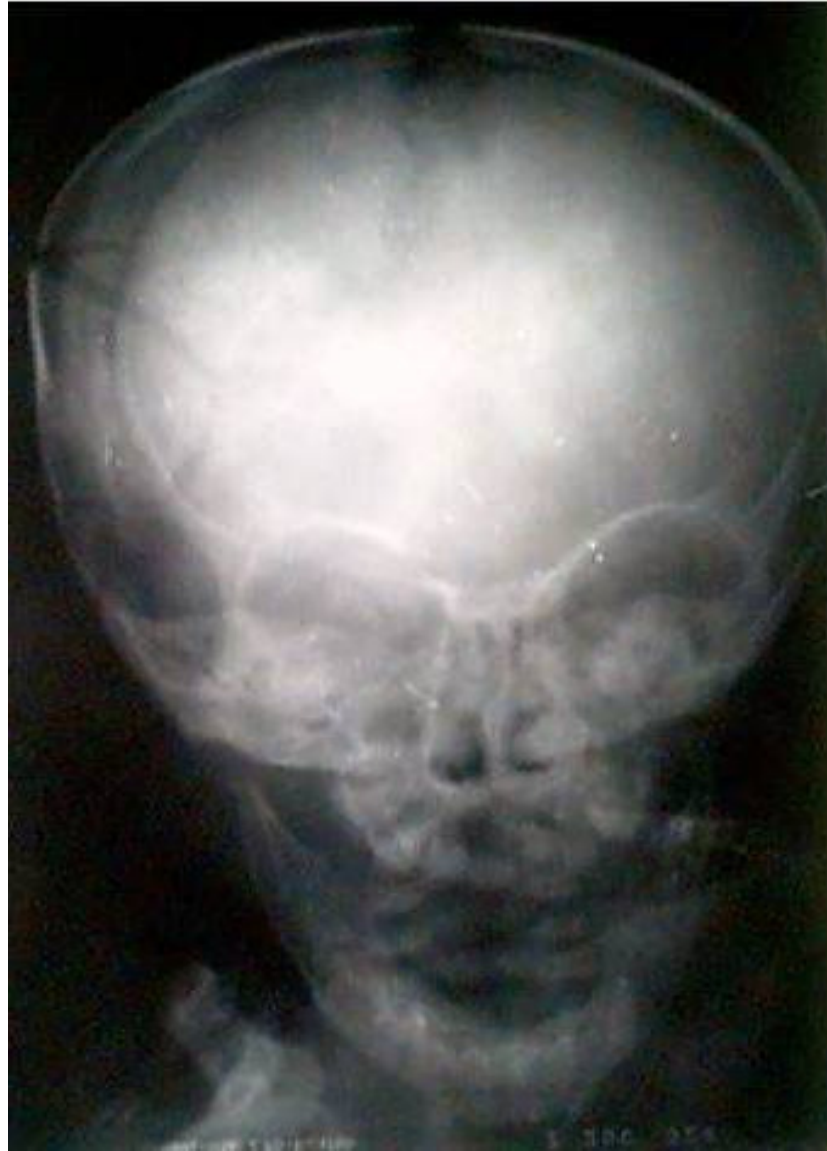


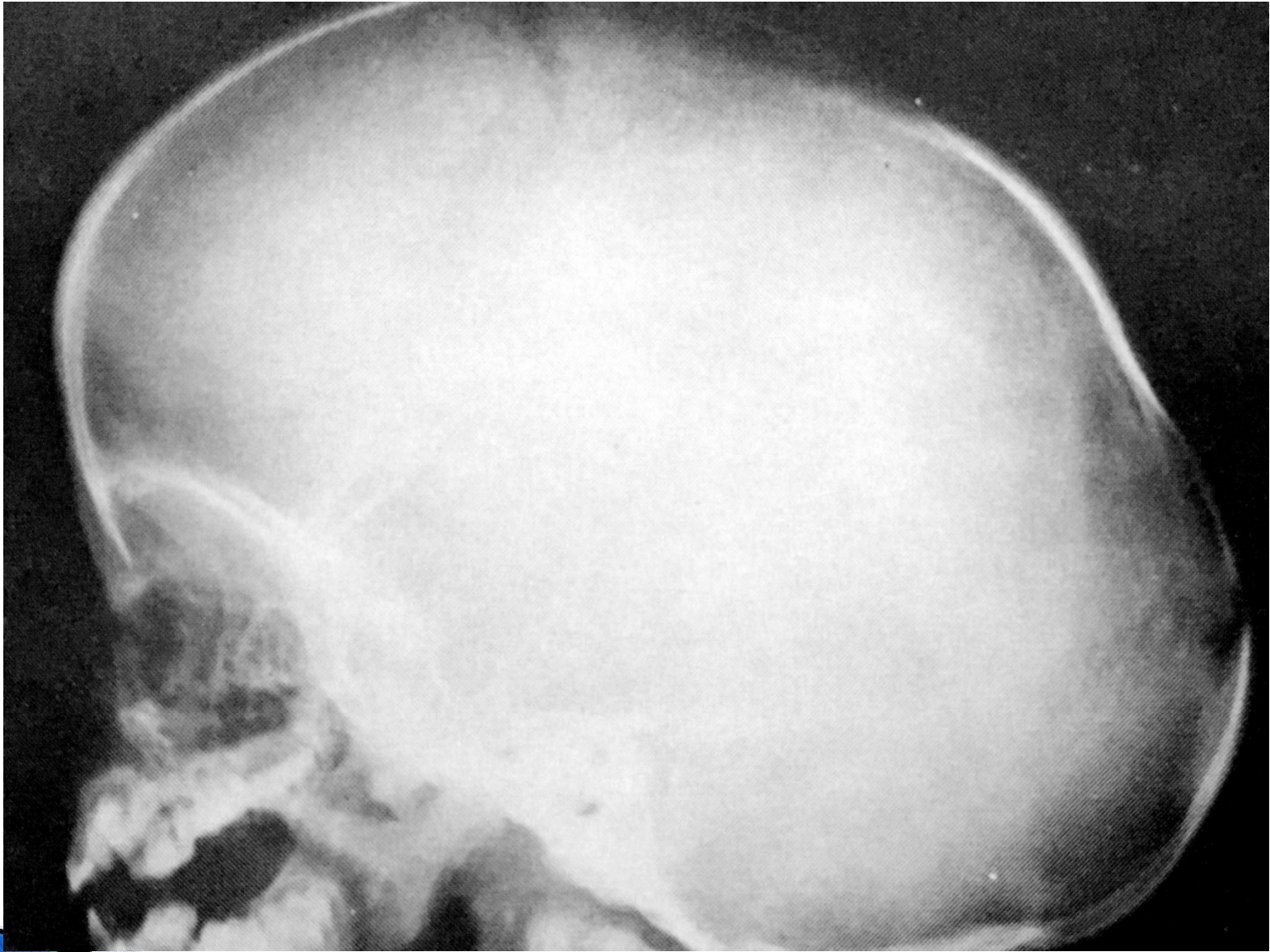


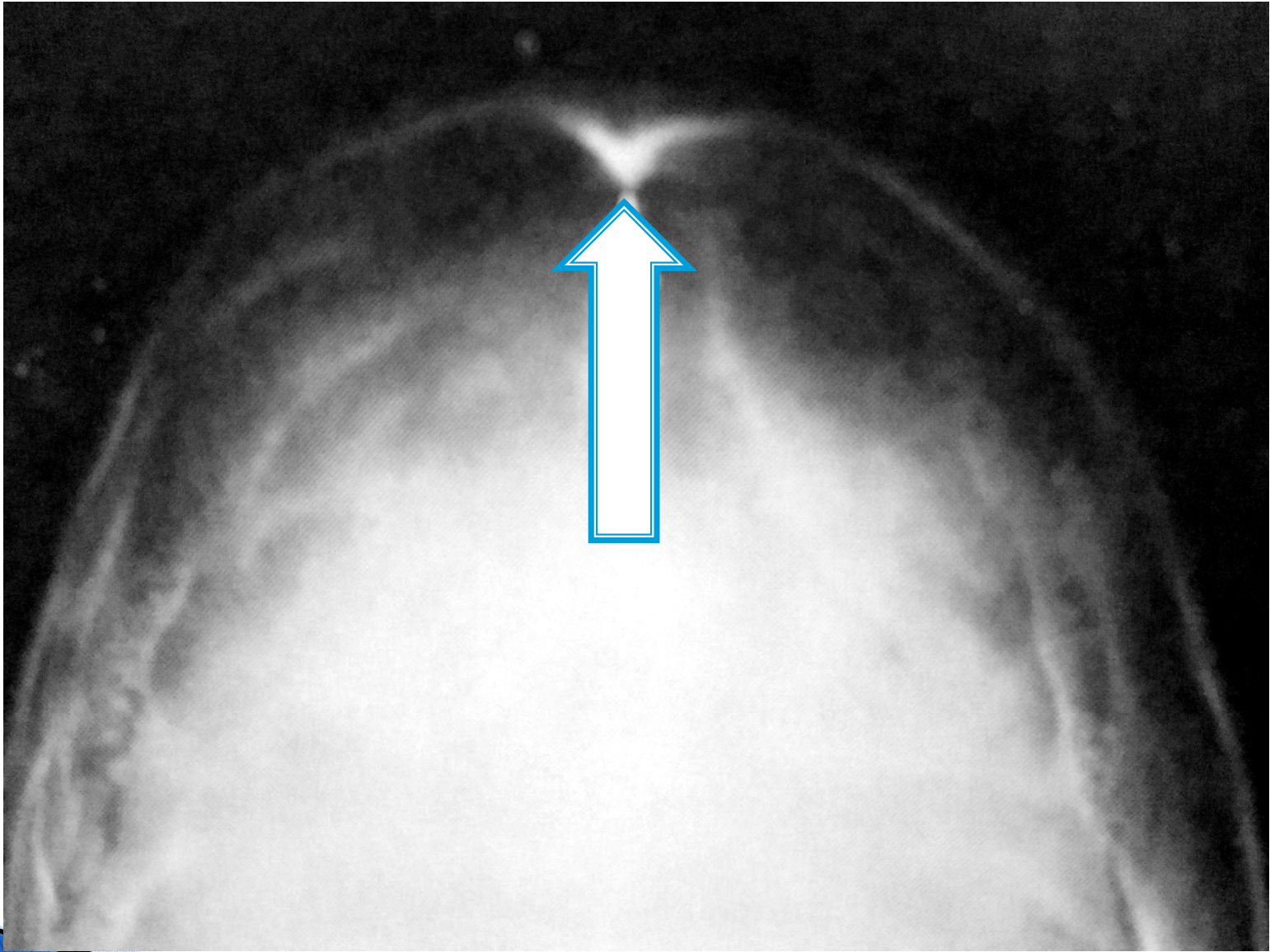
Imagen 1


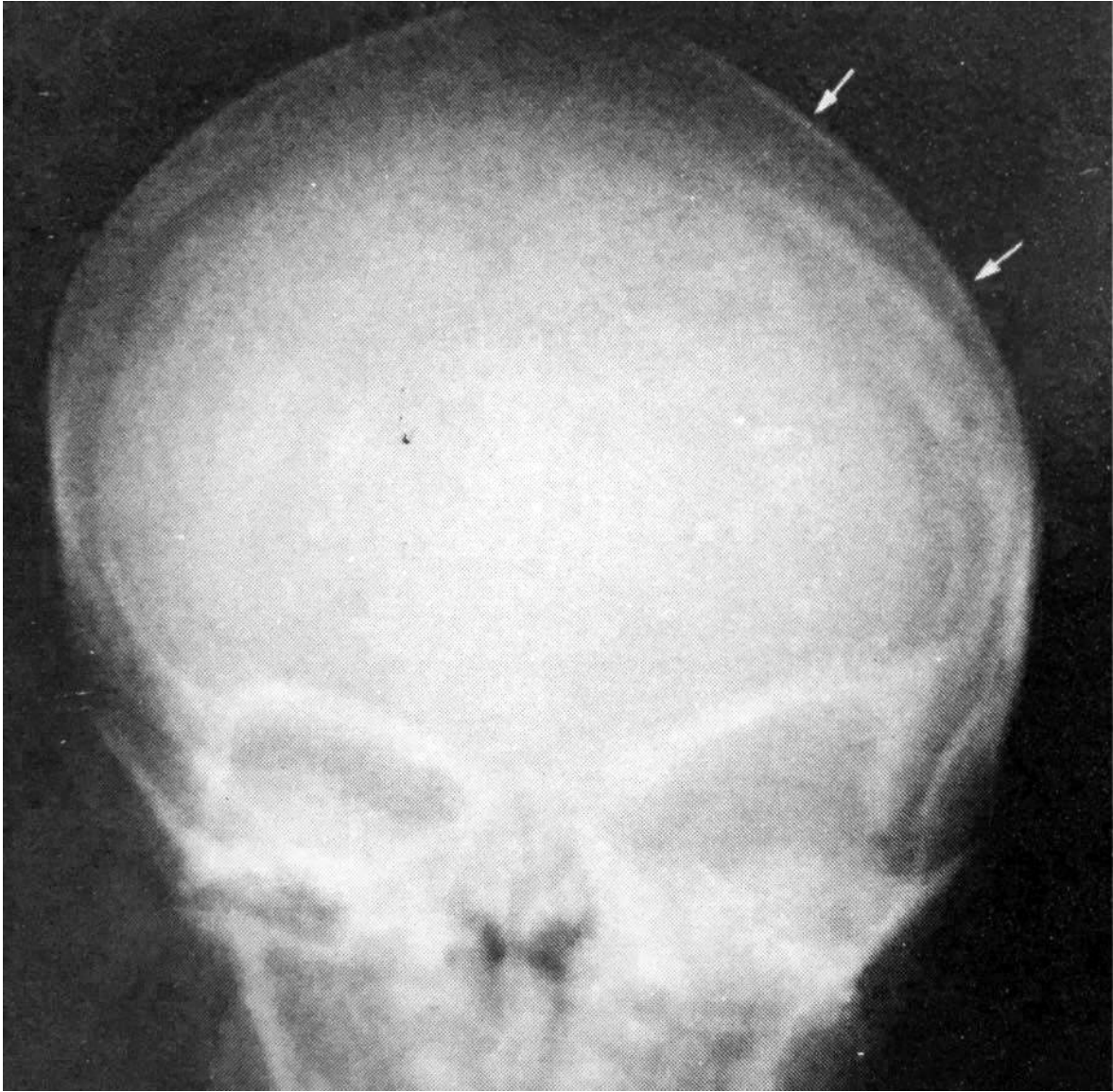

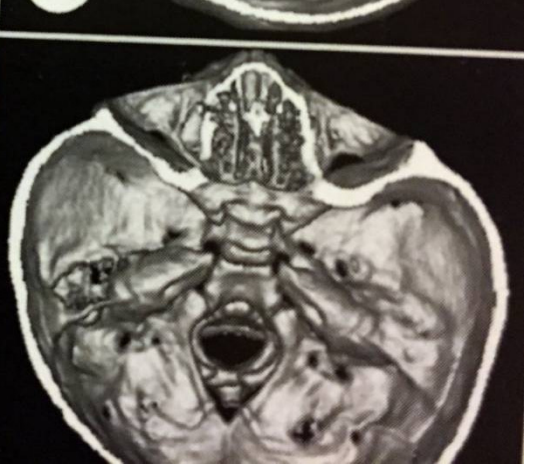

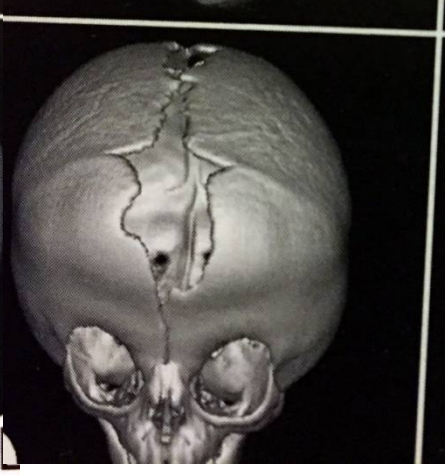
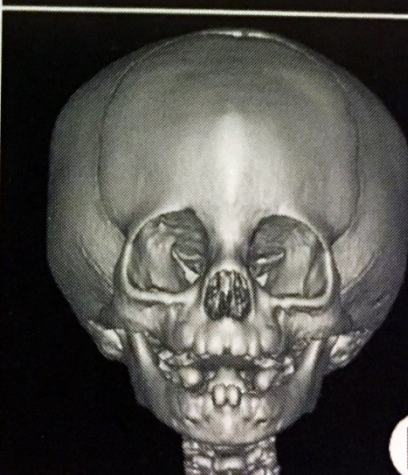
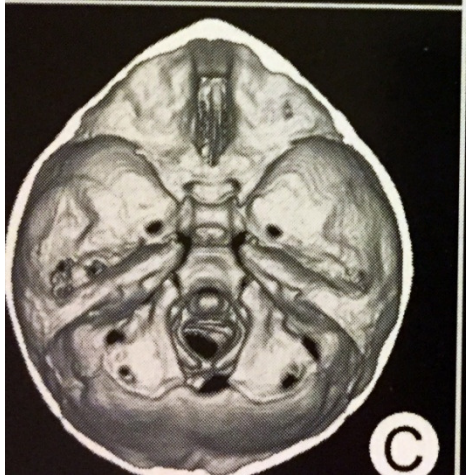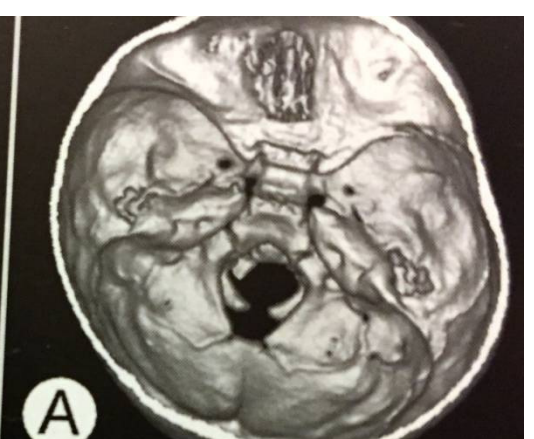
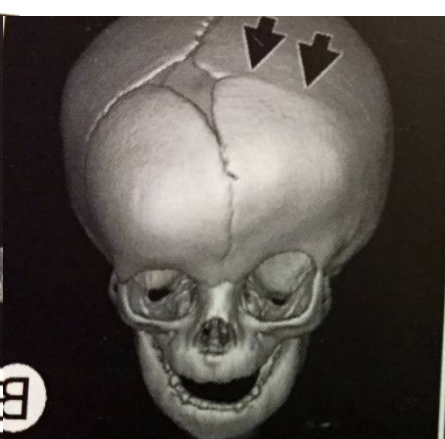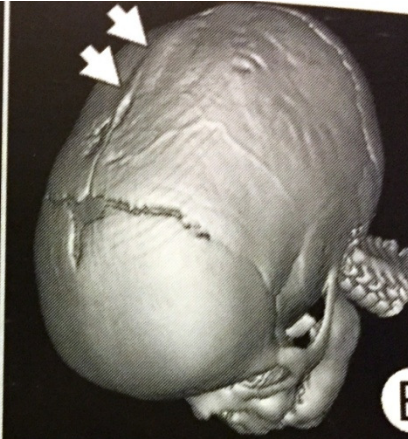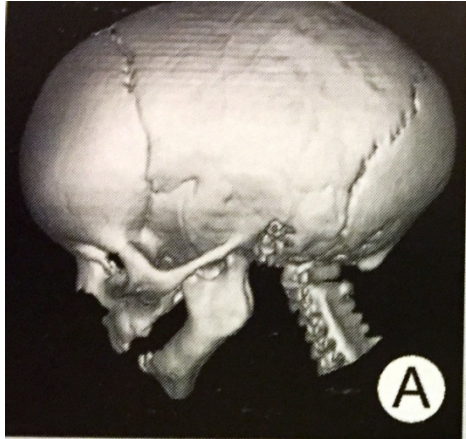




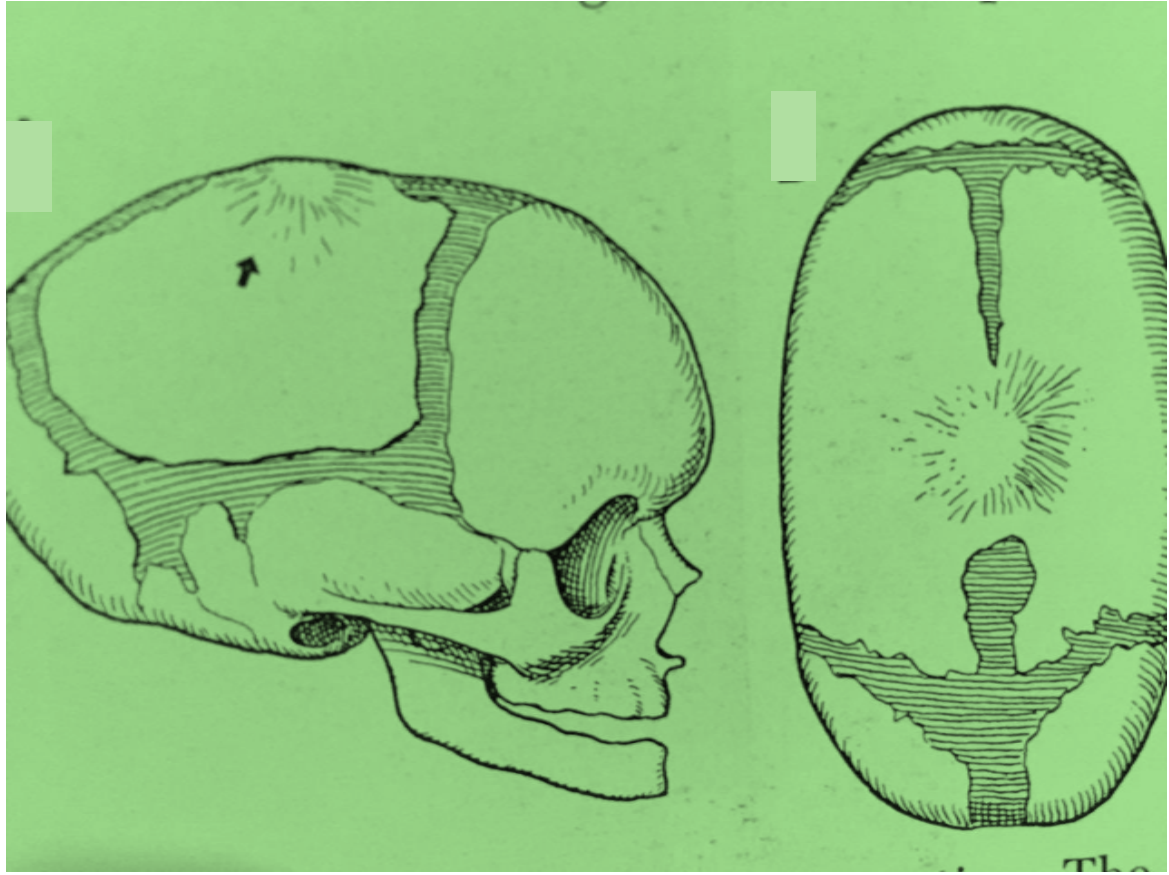
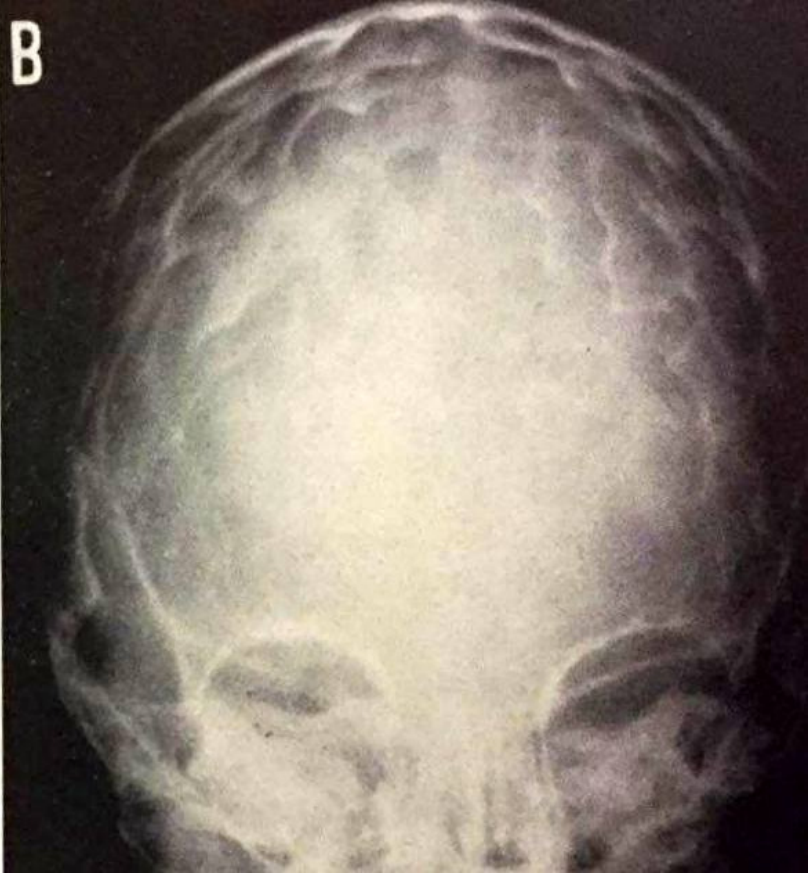
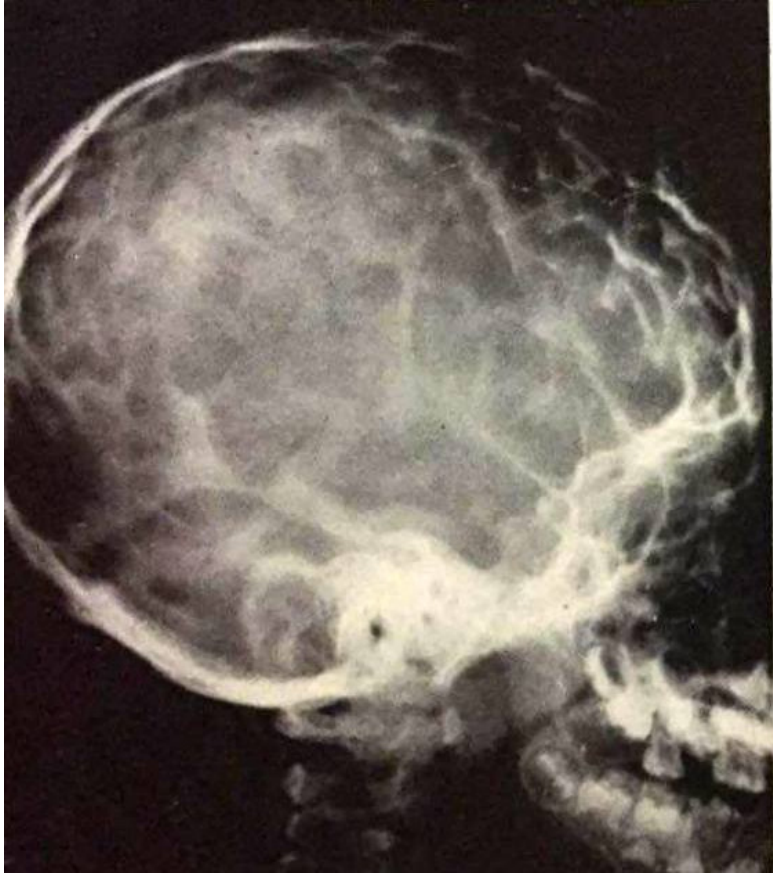




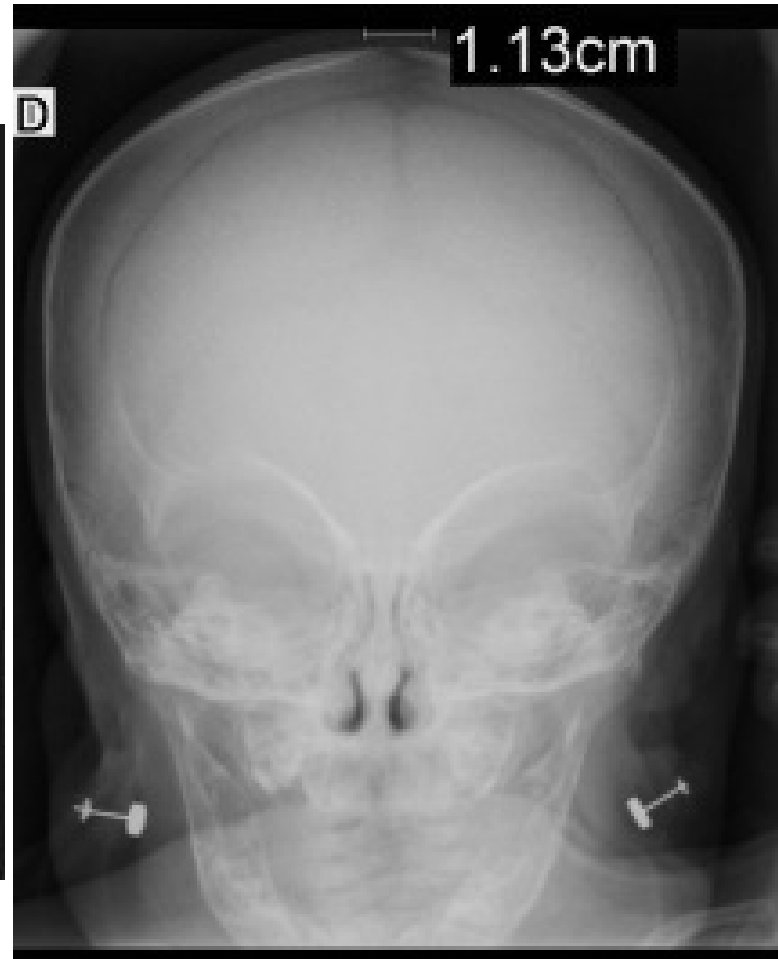
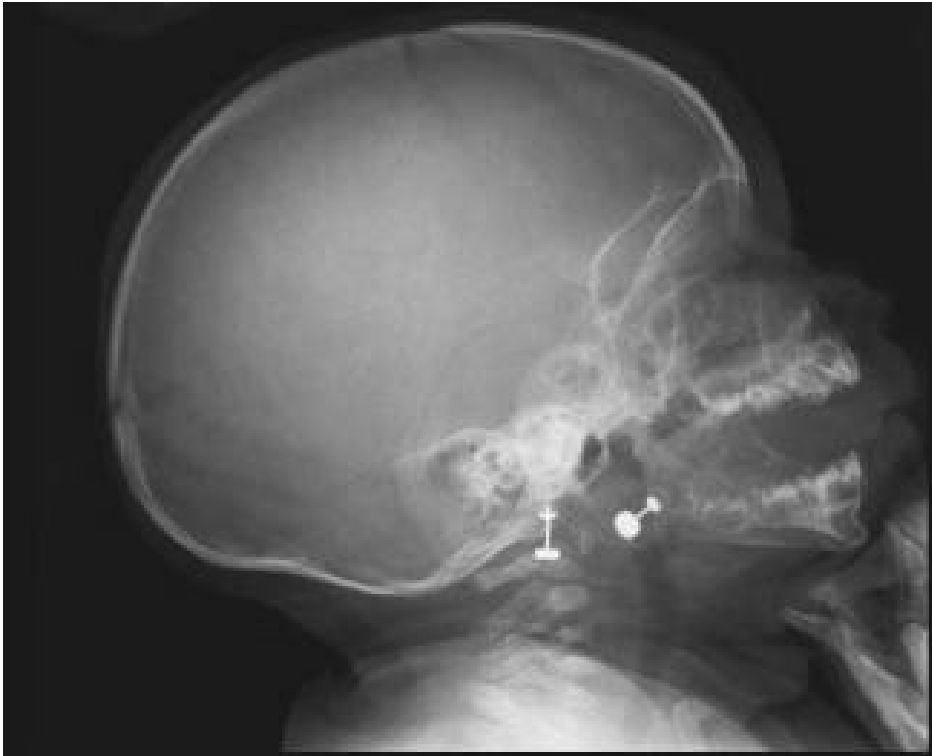
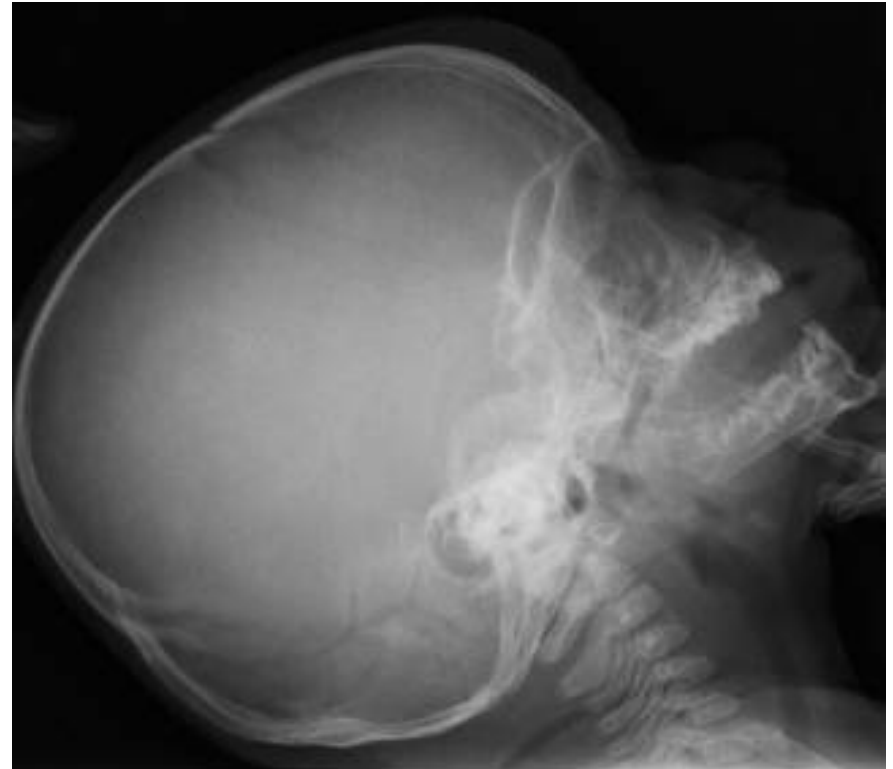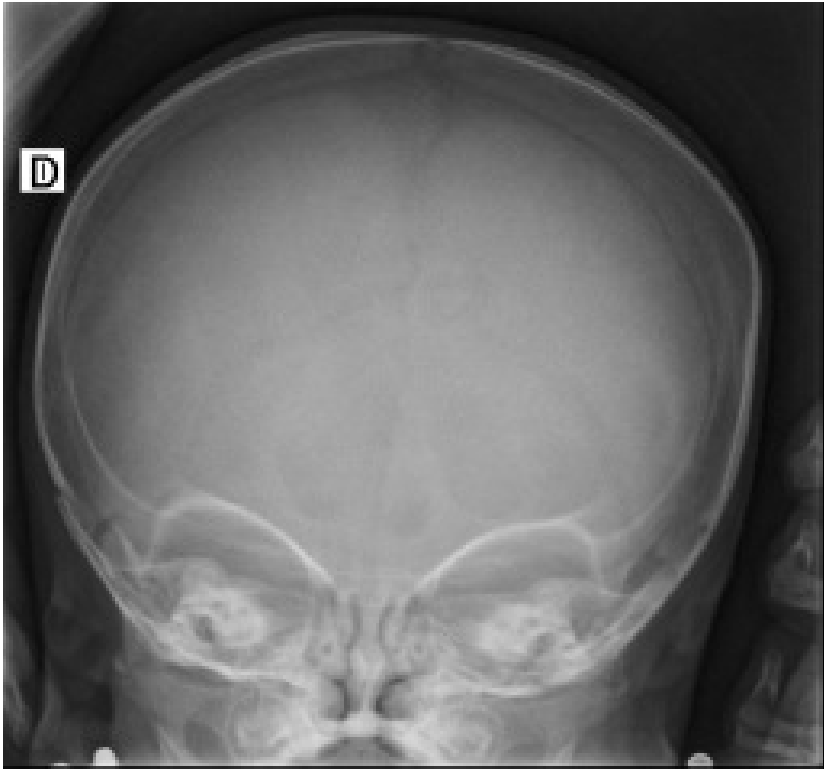





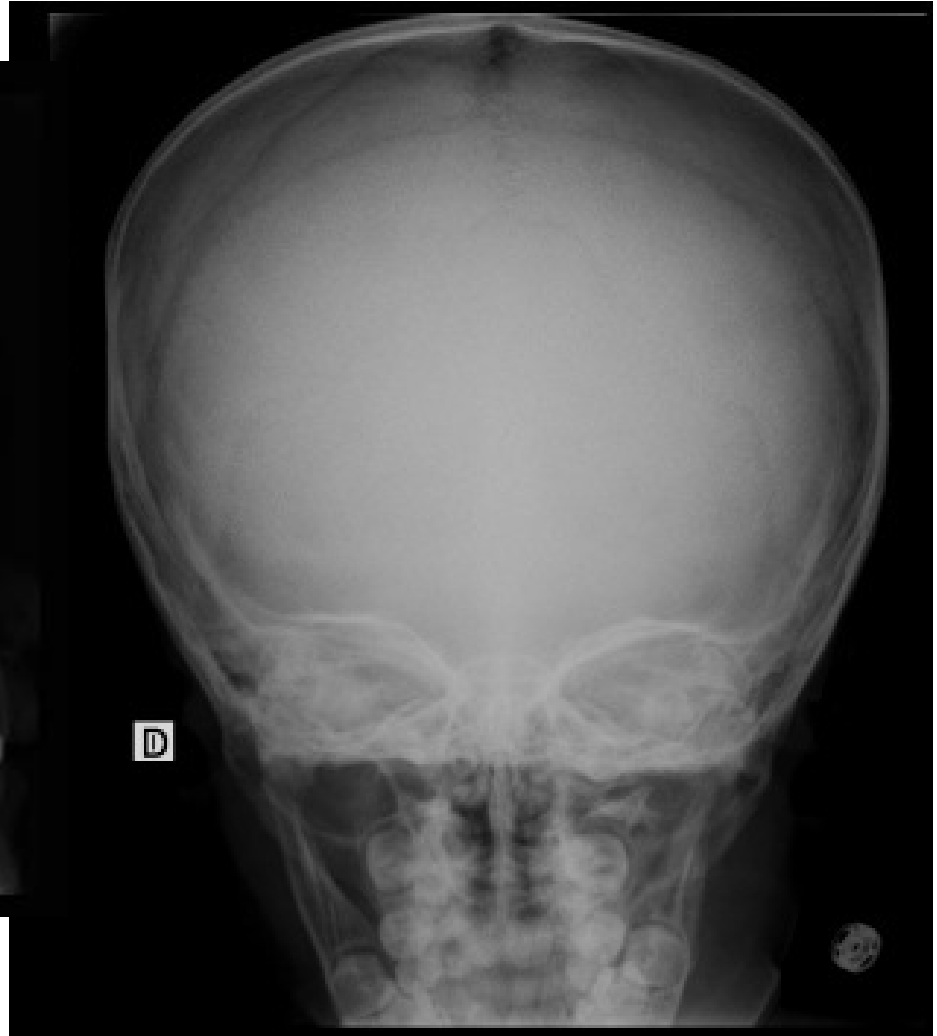
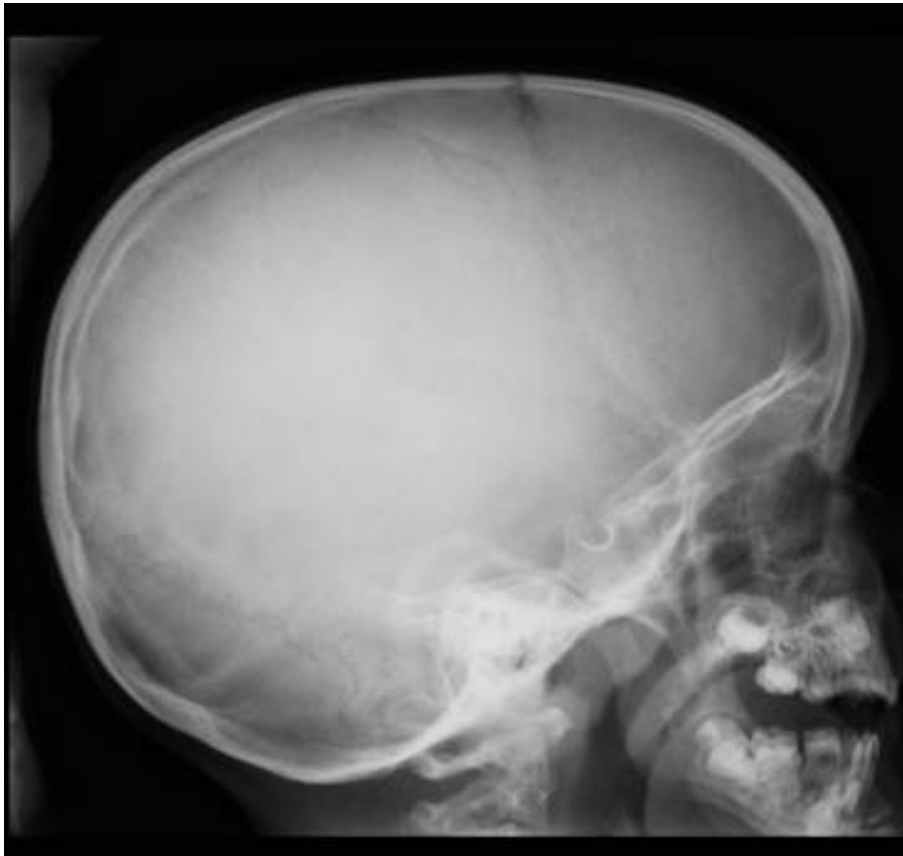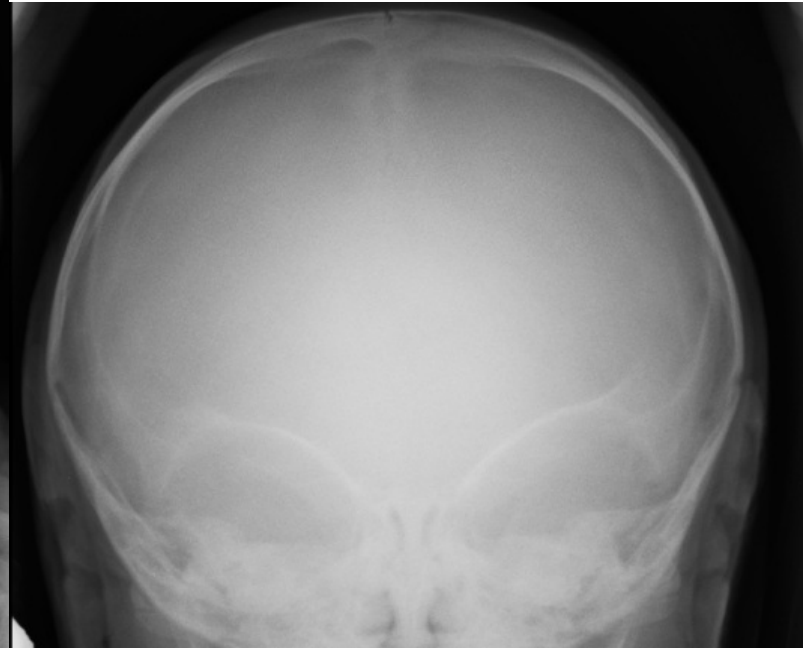



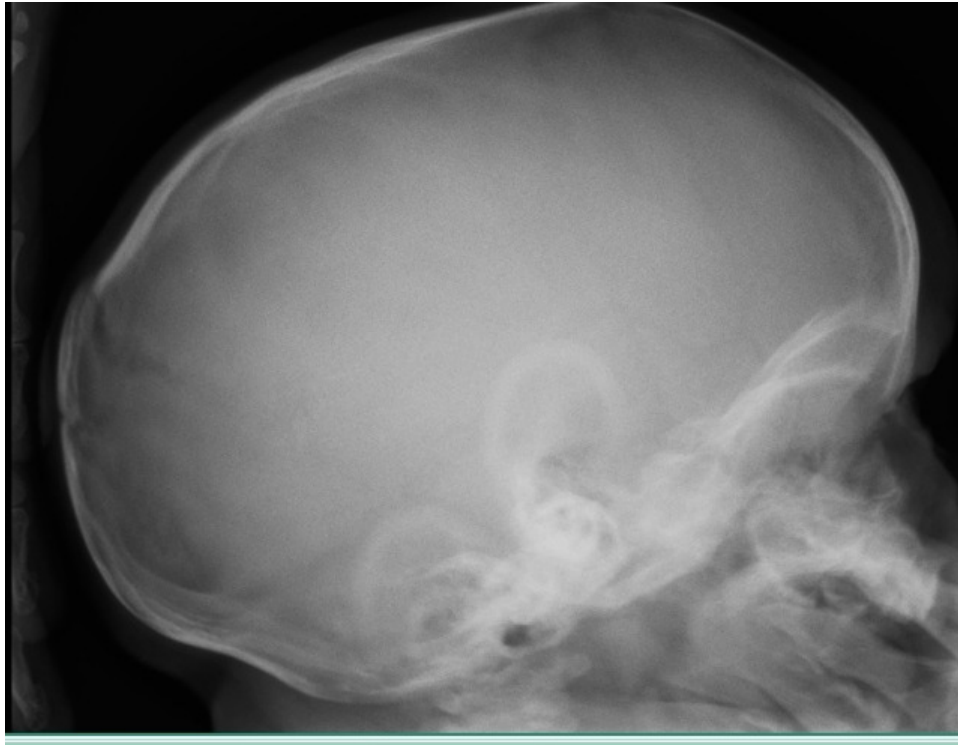








Muchas gracias

luisfernandogentile1@gmail.com

