

Total Intravenous Anesthesia in Neurosurgery

Narmadhalakshmi Kannabiran¹ Prasanna Udupi Bidkar²

¹Department of Neuroanaesthesiology, Jawaharlal Institute of Postgraduate Medical Education and Research (JIPMER), Pondicherry, India

²Division of Neuroanaesthesia, Department of Anaesthesiology and Critical Care, Jawaharlal Institute of Postgraduate Medical Education and Research (JIPMER), Pondicherry, India

Address for correspondence Prasanna Udupi Bidkar, MBBS, MD (Anesthesiology), DNB (Anesthesiology), DM (Neuroanesthesiology) MNAMS, MBA, Division of Neuroanaesthesia, Department of Anaesthesiology and Critical Care, Jawaharlal Institute of Postgraduate Medical Education and Research (JIPMER), Pondicherry 605006, Tamil Nadu, India (e-mail: drprasannabidkar@gmail.com).

J Neuroanaesthesiol Crit Care 2018;5:141–149

Abstract

In recent years, neurosurgical anesthesia has been rapidly evolving in the fields of pharmacotherapy and techniques to administer safe anesthesia. Intravenous (IV) anesthetic agents reduce both cerebral blood flow and intracranial pressure besides maintaining flow–metabolism coupling in contrast to inhalational agents. In neuroanesthesia, the technique and choice of drugs directly influence the outcome of the patients. The purpose of this review is to provide the updated information of total intravenous anesthesia (TIVA) in neuroanesthesia. Administration of TIVA using target-controlled infusion technique is emerging as a standard method to administer safe anesthesia in neurosurgical patients. The propofol–remifentanyl combination has become very popular due to their favorable pharmacokinetic and pharmacodynamic properties for neurosurgery cases. Plasma-effect site concentration monitoring from target TCI devices together with electroencephalogram or bispectral index monitors allows easy titration of anesthetic agents to ensure adequate depth of anesthesia depending upon the nociceptive stimulus. TIVA is associated with smooth induction and rapid emergence with less postoperative nausea and vomiting.

Keywords

- ▶ neurosurgery
- ▶ TIVA
- ▶ propofol
- ▶ remifentanyl
- ▶ dexmedetomidine

Introduction

Neuroanesthesia has been rapidly evolving over the decades. Anesthesia for neurosurgical procedures requires an understanding of cerebral anatomy, physiological cerebral flow dynamics, and the likely changes that occur in response to the pathological rise in intracranial pressure (ICP). With the development of safer and faster acting inhalational and intravenous (IV) anesthetic agents, a balanced anesthesia is widely provided in a variety of neurosurgical cases. But, it is always challenging to provide optimal anesthesia during perioperative period.

We cannot deny the fact that IV anesthesia is widely used in neurosurgical anesthesia. The drugs and techniques of neuroanesthesia will directly influence the perioperative surgical outcome of patients. In addition to balanced anesthesia with smooth induction and emergence, the fundamental necessities in neuroanesthesia include maintenance

of adequate cerebral perfusion pressure (CPP), avoidance of intracranial hypertension, and the provision of optimal surgical conditions to avoid further progression of the pre-existing neurological insult.¹ The aforementioned conditions can be achieved by both inhalational and total intravenous anesthesia (TIVA).² However, in certain circumstances, TIVA has the edge over the other technique, as the evidence is weak for inhalational agents, and affirmation on TIVA also needs to be established.

The IV thiopental was introduced into clinical practice in 1934 and was widely used during world war II,³ but its popularity fell soon after the attack on Pearl Harbor when soldiers died after the administration of thiopental in patients with hypovolemic shock. Since the introduction of propofol in 1986, it has largely replaced thiopental and has become an induction agent of choice.⁴ It has become a key component of TIVA nowadays.

received

July 1, 2018

accepted after revision

August 21, 2018

published online

October 24, 2018

DOI <https://doi.org/>

10.1055/s-0038-1673544

ISSN 2348-0548.

Copyright ©2018 Indian Society of Neuroanaesthesiology and Critical Care

License terms



Ideal Anesthetic Agent for Neuroanesthesia

The choice of the anesthetic agent can have a significant impact on neurological outcome in neurosurgical operations. The ideal anesthetic agent in neurosurgery should have the following properties: rapid onset and rapid emergence for neurological assessment, hemodynamic stability, and ICP reduction.⁵

Cerebral blood flow (CBF) and cerebral metabolic rate of oxygen (CMRO₂) are interdependent. Any increase or decrease in cerebral metabolic oxygen demand will increase or decrease the CBF, respectively, and this phenomenon is known as flow–metabolism coupling. As the skull is a closed space, any increase in CBF will increase ICP, which may affect CPP.

Inhalational anesthetic agents tend to affect this flow–metabolism coupling in a dose-dependent manner.⁶ At concentrations of ≤1 minimum alveolar concentrations (MAC), there will be a minimum increase in CBF and reduction in the CMRO₂. However, at >1 MAC inhaled concentrations, there will be an increase in CBF, which, in turn, increases ICP and causes flow–metabolism uncoupling (–Table 1). The vasodilation caused by inhalational agents is managed by hyperventilating the patient to vent off the carbon dioxide (CO₂), but moderate-to-severe hyperventilation can induce cerebral ischemia due to vasoconstriction of cerebral vessels in a patient whose CPP is low due to raised ICP.

In contrast to inhalational agents, IV agents, such as propofol, reduce both CBF and CMRO₂, lower ICP, improve CPP, and provide adequate neuroprotective effect during cerebral ischemia (–Table 2).^{7–9} Besides, propofol has rapid onset as well

as is a shorter acting drug, a property which facilitates rapid tracheal intubation and smooth emergence during recovery, which is crucial for monitoring neurosurgical patients.

Which is Better?

Is Anesthesia for Elective and Emergency Neurosurgery Cases Different?

Though inhalational anesthetic agents and TIVA have been used successfully, there is no sufficient evidence to prove the superiority of one over the other. Todd et al compared propofol–fentanyl-, isoflurane–nitrous oxide-, and fentanyl–nitrous oxide-based anesthesia techniques in 121 patients undergoing supratentorial tumor surgeries.¹⁰ ICP was comparable in all the three groups. Fentanyl–nitrous oxide group had slightly faster recovery (5 minutes vs. 10 minutes in other group). But early postoperative nausea and vomiting (PONV) were significantly higher in fentanyl–nitrous oxide patients (17%) compared with only 2.5% and 5% in patients in propofol–fentanyl and isoflurane–nitrous oxide group ($p = 0.03$). The study concluded that the short-term outcomes such as new postoperative deficits, total hospital stay, or cost were similar, and all the three techniques were acceptable for supratentorial tumor surgeries.

Petersen et al studied three groups: propofol–fentanyl (TIVA), isoflurane–fentanyl, and sevoflurane–fentanyl anesthesia techniques to assess its effects on ICP and cerebral hemodynamics before and during hyperventilation in 117 patients undergoing elective craniotomy surgeries.⁷ Subdural ICP and jugular venous oxygen saturation (SJVO₂) were significantly lower in the TIVA group compared

Table 1 Effect of inhaled agents on cerebral dynamics

Inhaled agents	MAP	CBF	CPP	ICP	CMRO ₂
Halothane	↓ ↓	↑ ↑ ↑	↓ ↓	↑ ↑	↓ ↓
Isoflurane	↓ ↓	↑	↓ ↓	↑	↓ ↓ ↓
Sevoflurane	↓ ↓	↑	↑	0– ↑	↓ ↓ ↓
Desflurane	↓ ↓	↑	↑	↑	↓
Nitrous oxide	0– ↓	↑ – ↑ ↑	↓	↑ – ↑ ↑	↓ ↑

Abbreviations: CBF, cerebral blood flow; CMRO₂, cerebral metabolic rate of oxygen; CPP, cerebral perfusion pressure; ICP, intracranial pressure; MAP, mean arterial pressure.

(↓) Decrease and (↑) increase.

Table 2 Effects of intravenous agents on cerebral dynamics

Intravenous agents	MAP	CBF	CPP	ICP	CMRO ₂
Thiopentone	↓ ↓	↓ ↓ ↓	↑ ↑ ↑	↓ ↓ ↓	↓ ↓ ↓
Propofol	↓ ↓ ↓	↓ ↓ ↓	↑ ↑	↓ ↓	↓ ↓ ↓
Etomidate	0– ↓	↓ ↓ ↓	↑ ↑	↓ ↓ ↓	↓ ↓ ↓
Ketamine	↑ ↑	↑ ↑ ↑	↓	↑ ↑ ↑	↑
Benzodiazepines	0– ↓	↓ ↓	↑	0	↓ ↓
Opioids	0– ↓	↓	0– ↓	0– ↓	↓

Abbreviations: CBF, cerebral blood flow; CMRO₂, cerebral metabolic rate of oxygen; CPP, cerebral perfusion pressure; ICP, intracranial pressure; MAP, mean arterial pressure.

(↓) Decrease and (↑) increase.

with patients in the inhalational agents' group ($p < 0.05$), whereas mean arterial pressure and CPP were found higher in patients receiving propofol–fentanyl (TIVA) compared with patients receiving isoflurane and sevoflurane ($p < 0.05$). They concluded that favorable cerebral hemodynamics from propofol group resulted in decreased cerebral swelling after dural opening.

In the meta-analysis by Prabhakar et al, TIVA and the inhalational-based anesthesia techniques were compared to assess the rapid emergence from anesthesia.¹¹ They included 15 randomized controlled trials (RCT) with 1,833 patients who underwent craniotomy for supratentorial tumor surgeries. The emergence was faster in patients who received propofol compared with isoflurane (mean difference [MD]: 3.29 minutes, 95% confidence interval [CI]: -5.41 to -1.18, low-quality evidence), whereas the emergence from anesthesia was similar in both propofol and sevoflurane groups (MD: 0.28 minutes slower with sevoflurane, 95% CI: -0.56 to 1.12, four studies, low-quality evidence). The overall risk of PONV was less in the propofol group. They also found that the brain relaxation scores were better with propofol group compared with isoflurane (reference range [RR]: 0.88, 95% CI: 0.67 to 1.17, low-quality evidence). But, no difference in the brain relaxation scores was noticed when the propofol group was compared with sevoflurane. The authors mentioned that the evidence was of low quality and commented that the IV technique and the sevoflurane inhalational technique are comparable in terms of early emergence and adverse events from anesthesia. Whereas, the use of isoflurane significantly delays the emergence.

Though both the techniques are comparable in elective brain tumor surgeries, things can be more complicated in emergency surgeries. The risk of brain bulge increases with gross peritumoral edema, midline shift of more than 5 mm, raised ICP features, and impending herniation (→ Fig. 1). It is crucial to prevent secondary brain injuries and to give adequate neuroprotection to prevent irreversible neurological sequelae. The target-controlled infusion (TCI) techniques with pharmacokinetic models for IV administration

of drugs facilitate smoother induction, with smaller doses, and slower infusion rates thereby prevent fall in mean arterial pressure, which is often associated with the manual administration of IV drugs during induction.¹² Thiopentone, propofol, ketamine, and etomidate all have been used for the induction in patients with raised ICP.^{13,14} The property of ketamine to raise ICP has been challenged and has been found to have beneficial effects on ICP.¹³ Propofol, when given in bolus doses, will cause fall in mean arterial pressure, which will be catastrophic in raised ICP cases. However, if this fall in mean arterial pressure is mitigated with adequate fluid resuscitation and vasopressors, propofol has been associated with improved neuroprotection. If inhalational agents are used, the condition of the dura (tense or soft) should be assessed after the first burr hole and, if needed, can be switched over to TIVA. The researches and studies had mentioned the use of inhalational anesthetic agents in the maintenance of neuroanesthesia in emergency-raised ICP cases.^{15,16}

A study, by Wan Mohd et al, comparing the outcomes of TCI of propofol versus sevoflurane anesthesia in 110 patients undergoing emergency traumatic brain surgery,¹⁵ found no difference in the outcomes—Glasgow Outcome Scale (GOS) score at discharge ($p = 0.25$); the percentages of mortality (GOS 1) (27.3% vs. 16.4%, respectively); vegetative and severe disability (GOS 2–3) (29.1% vs. 41.8%, respectively), and good outcome (GOS 4–5) (43.6% vs. 41.8%, respectively). Most postoperative parameters and ICU complications were not significantly different between the groups, except for the requirement of inotropic support, which was higher in the sevoflurane group (40.0% vs. 60.0%; $p = 0.04$).

Based on the limited available literature and non-availability of the superior quality of RCTs, it can be inferred that both the techniques can be effectively used in elective neurosurgeries. Though the TCI technique provides rapid onset and offset of anesthesia and propofol being proven to be neuroprotective, providing brain relaxation, favorable cerebral hemodynamics, and reduced incidence of PONV, strong evidence to suggest the use of TIVA in emergency neurosurgery is also lacking.

Total Intravenous Anesthesia in Neuroanesthesia

Total Intravenous Anesthesia uses a combination of agents given exclusively by the IV route.¹⁷ The increasing popularity of TIVA in neuroanesthesia is mainly due to three reasons—first, the faster and shorter acting drugs such as propofol and opioids (remifentanyl) provide optimal conditions for maintaining the adequate plane of anesthesia in neurosurgery. Second, the availability of computer-based models of TCI, which couples the pharmacokinetics of the drug with infusion pump technology, helps achieve the desired plasma concentration of the drug easily.¹⁸ Third, propofol in TIVA offers several advantages over inhalational techniques that include a reduction in ICP, hemodynamic stability, and reduced incidence of PONV.^{19,20}

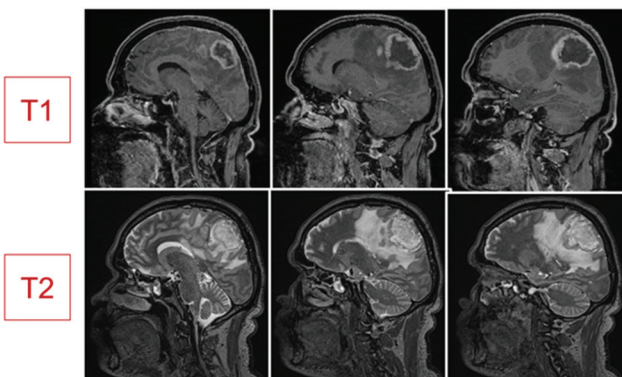


Fig. 1 Sagittal section brain magnetic resonance imaging (MRI) shows gross peritumoral edema in T1- and T2-weighted images. Arrow marks: cerebral edema, T1-weighted: hypointensity, and T2-weighted: hyperintensity.

Target-Controlled Infusion and Neuroanesthesia

Target-controlled infusion (TCI) aims to achieve a predetermined drug concentration targeted by the user. This technique has been developed to meet the anesthetic goals such as smooth induction, reliable and titratable maintenance, and rapid emergence. It is identified as a standard technique to administer IV anesthetic drugs. The first TCI system “Diprifusor” was made commercially available in 1998 for use with propofol.²¹ TCI pump incorporates a computer-based technology where the patient information such as height, weight, age, and gender is entered, and the anesthetist sets the desired plasma concentration of drug that needs to be attained in a particular tissue or compartment. The computer uses the pharmacokinetic and pharmacodynamic properties of the drug, then it calculates the infusion rate to attain user-defined plasma concentration in the specific tissue. TCI pumps display the plasma–effect site concentration of the drug, thereby allowing the anesthetist to alter the desired drug concentration, if required, depending upon the stages of surgery.

Infusion of propofol and remifentanyl drug combination was found to obtund the responses to noxious stimuli satisfactorily in TCI-based TIVA technique.²² The rapid recovery profile with TIVA facilitates intraoperative wake-up while retaining amnesia, this property is essential in minimally invasive cortical surgeries to prevent injury to eloquent areas. The availability of TCI to administer TIVA helps adjust the drug concentration in a desirable user-friendly way that favors rapid patient recovery.²³ These devices do mathematical calculations to include the volume of distribution of drugs in various tissues to rapidly adjust the drug concentration and achieve the desired clinical effect. The fifth National Audit Project reported awareness during anesthesia when manual infusion of the drugs was used to administer TIVA.²⁴

Complexities in Neuroanesthesia and Total Intravenous Anesthesia

Neurosurgical operations are complex with variable levels of stimulation ranging from mild to severe throughout the procedure. It is essential to monitor and adjust the depth of anesthesia to prevent a rise in ICP. ► **Fig. 2** depicts varying periods of noxious stimuli during surgery.

During induction, the depth of anesthesia required is more to prevent an increase in ICP during laryngoscopy and intubation. This is followed by a period of the minimal stimulus of 30 minutes when arterial and central venous pressure lines are inserted. After securing IV lines, the patient is handed over for positioning and skull pin fixation where the depth of anesthesia needs to be increased. Along with anesthetic depth alteration, adequate analgesia should be provided to prevent the sympathetic response from noxious stimuli. Once the dura is opened, the noxious stimulus becomes minimal again as the brain tissue is pain insensitive. However, the lighter plane of anesthesia during brain dissection can produce brain bulge and cause intraoperative tight

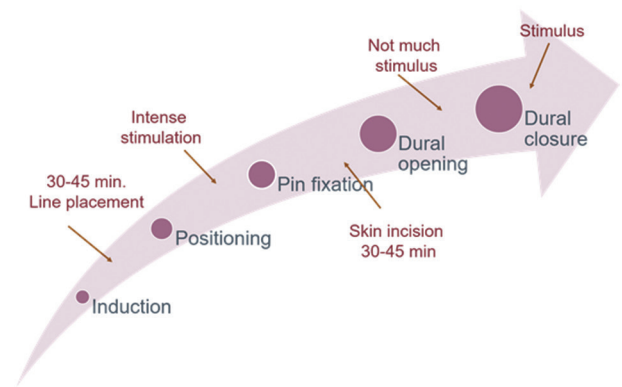


Fig. 2 Time course of a neurosurgical operation.

brain situation. During brain retraction and dissection, there needs to be a good anesthetic depth to achieve metabolic suppression as well as neuroprotection when the maximum brain injury occurs. Hence, the anesthetic depth is increased, and analgesics are minimized. For these reasons, a depth of anesthesia monitor and effect site drug concentration monitors are essential in neuroanesthesia especially when TIVA technique is used. Monitoring the depth of anesthesia can be achieved with the use of a bispectral index (BIS) or spectral entropy.^{25,26} Titrating and maintaining BIS index between 45 and 60 will prevent deep hypnosis or a light anesthetic plane.^{27,28} If TCI is used, effect site drug concentration can be predicted in real time using Tivatrainer pharmacokinetic software (www.eurosiva.eu) and the drug levels can be rapidly adjusted according to the need. Suggested effect site concentration of propofol and remifentanyl for patients under intrinsic positive pressure ventilation are 3 to 4 $\mu\text{g}/\text{mL}$ and 5 to 8 ng/mL , respectively, for patients <50 years and 2 to 3 $\mu\text{g}/\text{mL}$ and 3 to 6 ng/mL , respectively, for patients > 50 years.²⁹ A study by, Ferreira et al predicted the cerebral concentration of propofol (PropCe) and remifentanyl (RemiCe) requirement at various stages of neurosurgical anesthesia. They observed that PropCe at intubation, incision, and extubation were 5 ± 1 , 2.6 ± 0.9 , and 1 ± 0.3 $\mu\text{g}/\text{mL}$, respectively. RemiCe in the same periods were 2.2 ± 0.3 , 6 ± 2.6 , and 2.2 ± 0.9 ng/mL , respectively.³⁰ Above all, TIVA is environmentally friendly when compared with inhalational anesthetic agents, which are implicated in global warming.

Special Situations

Total Intravenous Anesthesia in Traumatic Brain Injury
Traumatic brain injury (TBI) is one of the most common conditions very often seen in the emergency department. It is a leading cause of neurologic disability and mortality. Till now, there are no standard guidelines or recommendations available outweighing the proposed benefits of TIVA against inhalational agents in TBI cases. Brain Trauma Foundation guidelines recommended no specific anesthetic agent.³¹ However, due to neuroprotection and maintenance of flow–metabolism coupling, it is preferable to use TIVA to reduce ICP than inhalational agents in patients with

poor Glasgow Coma scale, brain edema, and midline shift of more than 5 mm posted for an emergency craniotomy.³²

During Intraoperative Neurophysiological Monitoring

Intraoperative neurophysiological monitoring (IONM) is one of the greatest advancements in neuroanesthesia, which has become an integral part of care. IONM has been utilized to identify and prevent insult to crucial neural structures in the surgical field. Its use has been reported in almost all neurosurgical procedures that include spinal surgeries, aneurysm surgery, cerebellopontine angle surgery, and endovascular procedures.^{33–35} The commonly employed monitoring techniques include somatosensory-evoked potentials (SSEP), motor-evoked potentials (MEP), and electromyography (EMG).³⁶ Anesthetic agents affect the latency and the amplitude of SSEP and MEP, which is very prominent with inhalational anesthetics compared with IV agents.^{37–39}

The inhalational agents increase the latency and reduce the amplitude of evoked potentials, hence interfering with evoked potential monitoring (► **Table 3**). The MEP recording precludes the use of neuromuscular blocking agents. These evoked potentials are minimally affected by IV agents and opioids, used in regular anesthetic doses.⁴⁰ Hence, TIVA becomes the preferred technique for IONM monitoring. Another advantage of TIVA over inhalational agents in cervical spine surgeries is that it suppresses coughing effectively at the end of surgery that prevents potential complications.^{41,42} If the depth of anesthesia is not monitored, the risk of awareness is higher with TIVA. This risk can be decreased with the use of the TCI technique and with the use of anesthetic depth monitors. This will also prevent any unexpected movement due to reduced anesthetic depth.

Monitored Anesthesia Care in Neuro Patients

Monitored anesthesia care (MAC) is a technique to provide local anesthesia along with sedation and analgesia to

► **Table 3** Effects of anesthetic agents on evoked potential monitoring

Agent	Amplitude	Latency
Nitrous oxide	↓	–
Inhalational agents Iso/Sevo/Des	↓↓	++
Propofol	–	+
Barbiturates–thiopentone, methohexital	↓	++
Etomidate	↓↓	+
Ketamine	↑↑	–
Opiates–fentanyl, remifentanyl	–	+
Benzodiazepines–diazepam, midazolam, and alprazolam	↓↓	++
Muscle relaxants	–	–

(↓↓) Significant decrease in amplitude, (↓) modest decrease in amplitude, (++) Significant increase in latency, (+) modest increases in latency, and (–) not affected.

undergo a planned therapeutic or diagnostic procedure. MAC is increasingly being used in neurosurgery in awake craniotomies for deep brain stimulation or to remove the lesion that is close to vital structures. It facilitates intraoperative neurophysiologic and neurocognitive monitoring and rapid postoperative recovery. Propofol remains the mainstay of the drug for sedation.⁴³ As it lacks the analgesic property, opioids are often combined.⁴³ Midazolam is coadministered to allay the anxiousness.⁴⁴ Even $\alpha 2$ agonists especially dexmedetomidine is gaining popularity recently due to its highly selective $\alpha 2$ agonist action that produces sedation without respiratory depression.⁴⁵ Besides, dexmedetomidine has the analgesic property that spares the use of opioids.⁴⁵

Awake Craniotomy

Awake craniotomy is performed to check regions of the brain before they are incised and to test patient's functioning continuously throughout the surgery. This is employed when surgeries in the brain involve the resection of lesion close to vital structures (motor and speech area), which needs to be preserved.^{46,47} There are two techniques, which are commonly used for awake craniotomy— (1) asleep–awake–asleep techniques and (2) awake–awake–awake technique. The aim of anesthesia in awake craniotomy is to provide changing states of sedation and analgesia, to ensure optimal patient comfort without interrupting neurophysiologic monitoring, and to ensure adequate ventilation and patency of airways. Propofol and remifentanyl TCI or propofol/fentanyl infusions are commonly used to titrate the levels of sedation with the aid of anesthetic depth monitors.^{48,49}

In the recent years, dexmedetomidine has gained popularity as a sole anesthetic agent to provide sedation without depressing respiration.^{50–52} The other drugs commonly used are a propofol–remifentanyl infusion, clonidine, benzodiazepines, and fentanyl.⁵³ There are studies that recommend TCI to administer TIVA for safety in awake craniotomies.⁵⁴ Scalp block is usually given either as a sole anesthetic technique or along with TIVA in awake craniotomies to avoid noxious stimulus responses.

Awake Intubation

Awake intubation has been practiced in unstable cervical spine cases to prevent any hazardous injury to it. The main advantage of awake intubation is that the patient is spontaneously breathing, and we can assess the neurologic examination after intubation before providing general anesthesia. Topical anesthesia and nerve blocks are often used to anaesthetize the airway, however, there is always a fear of local anesthetic toxicity. Patients are often very anxious and feel uncomfortable during the procedure. They require conscious sedation, where the patient can maintain airway, spontaneous respiration, and respond to commands. Dexmedetomidine has been widely utilized for sedation for awake intubation.^{55,56} Other drugs such as propofol, midazolam, and remifentanyl have also been studied and widely accepted for this purpose.^{57–59} The advantages of using IV anesthetic drugs in awake intubation is that it minimizes the local anesthetic requirement, suppresses cough reflex, allays anxiety, and provides sedation.

Intensive Care Unit Sedation

The sedation of neurosurgical patients in ICU is a controversial topic. Recent randomized trials emphasize that minimal or no sedation in ICU produces improved patient outcomes.^{60,61} However, sedation is vital in the acute phase of insult after either post-surgery or TBI especially when the patient is under mechanical ventilation. The risks and benefits of sedation are weighed against each other in relation to neuro-specific indications. The indications include sedation, analgesia, anxiety, delirium, ventilator-patient asynchrony, seizure suppression, and avoidance of raise in ICP to maintain CPP and flow-metabolism coupling. Various drugs have a varying effect on the above-mentioned indications. The drugs are chosen depending on the requirement, and sometimes drugs are combined to balance the advantages and disadvantages.⁶² Commonly preferred medications for ICU sedation include propofol, ketamine, remifentanyl, fentanyl, midazolam, and dexmedetomidine.^{63,64} Hemodynamic monitoring is essential in patients on sedation as the excess sedation is often dangerous. Purrucker et al studied the sedative effect of sevoflurane in ICU patients with acute stroke or subarachnoid hemorrhage (SAH) and found that though sevoflurane provides effective sedation, it causes a significant increase in ICP.⁶⁵ Other disadvantages of inhalational agents are that it needs complex equipment and expertise to deliver and monitor the effects.

Neuroanesthesia Outside the Operating Room

Increasingly, neuroanesthetists are faced with challenges to provide safe anesthesia outside the operating room due to increase in diagnostic and interventional radiological procedures. The plane of anesthesia required will vary for each procedure. For any neurological or neurosurgical case, the goals of anesthesia outside the operating room are the same as for anesthesia inside the operating room. Standard monitors, IV access and temperature control, and fluid balance should be taken care of in all the cases. The key areas of focus are plane of anesthesia/sedation required, airway protection and control of CO₂, hemodynamic stability, cervical spine immobility for suspected spine injuries, and ICP management.

For diagnostic procedures, conscious or deep sedation is often required. For shorter duration procedures, such as computed tomography (CT), shorter and faster acting drugs such as IV midazolam are used.

For MRI procedures, MRI compatible anesthesia machines with vaporizers and MRI safe infusion pumps are required inside the MRI suite to deliver inhalational-based anesthesia and TIVA, respectively. Dexmedetomidine is increasing in popularity for imaging studies as it can provide conscious sedation without respiratory depression and adverse events.⁶⁶⁻⁶⁸

Interventional neuroradiological procedures may be elective (e.g., aneurysm and arteriovenous malformations) or emergency (SAH and stroke) depending upon the diagnosis. The procedures may be long and difficult; the patients will often feel uncomfortable to lie still. Some procedures may demand episodes of apnea to prevent iatrogenic injury and to obtain high-quality imaging during the procedure. Necessary

precautions are needed to be undertaken while providing anesthesia to prevent secondary brain injury due to hypoxia, hypercapnia, hypertension, and hypotension. Sedation is required rather than the surgical plane of anesthesia. A combination of propofol or midazolam and remifentanyl or alfentanil can obtund noxious stimulus and offer completely still patient.⁶⁹ Dexmedetomidine has been found to provide sedation comparable with propofol and remifentanyl in a variety of surgical and interventional settings, but with lower incidences of respiratory adverse events.⁷⁰ Volatile anesthesia is complex and impractical outside the operating room. Lack of scavenging systems for vapor poses hazards to the environment.

Status Epilepticus

Status epilepticus is referred to as a condition when seizures occur for a prolonged duration of time or when multiple episodes of seizures recur without patient's recovery in between the seizures. When the patient does not respond to first- or second-line epileptic drugs, it is referred to as refractory status epilepticus. It is a neurological emergency that needs immediate administration of antiepileptic drugs. Midazolam has been widely used to prevent and treat status epilepticus in children as well as adults.⁷¹ IV anesthetic agents such as barbiturates and propofol are implicated to have anticonvulsant properties and are used in the management of refractory status epilepticus.⁷²

Drugs Used in Total Intravenous Anesthesia

Propofol

Propofol is an IV anesthetic agent that has the properties such as the reduction in CMRO₂, CBF reduction, maintenance of flow-metabolism coupling, reduction in ICP, inhibition of glutamate release, GABA-A receptor activation, cerebral autoregulation, CO₂ responsiveness, and neuroprotection.^{73,74} Other properties specific to neurosurgery include shorter and faster acting to facilitate rapid recovery, reduced incidence of PONV, and anticonvulsant action.⁷⁵ Propofol remains the mainstay of the drug for sedation in MAC procedures. The commonly used effect site concentration of propofol for sedation is 1 to 2 µg/mL. As it lacks the analgesic property, opioids are often combined. It causes the least interference with neurophysiologic monitoring and better recovery profile compared with volatile anaesthetics.⁷⁶ However, propofol lacks analgesic property, so it is frequently administered with other short-acting opioids such as remifentanyl or fentanyl. When propofol is administered at a high dose for a prolonged duration (> 5 mg/kg/h for more than 48 hours), it may cause metabolic acidosis, rhabdomyolysis, liver failure, and myocardial failure which is referred as propofol infusion syndrome.⁷⁷ So, prolonged administration of high dose of propofol should be avoided to prevent this dreaded complication.

Alpha-2 Agonists

Dexmedetomidine, a selective α-2 agonist has been used as an adjuvant to IV anesthetic agents.⁷⁸ It has gained its popularity recently due to its highly selective α₂ agonist action

that produces sympatholysis, sedation without respiratory depression.⁴⁵ Studies have mentioned that dexmedetomidine reduces CBF in a dose-dependent manner.⁷⁹⁻⁸¹ Farag et al compared the effects of propofol and dexmedetomidine for sedation during deep brain stimulation surgery, and they found that both the drugs comparably preserve CBF velocity and cerebral oxygen consumption in patients with movement disorders.⁸² The other advantages are that it provides conscious sedation and has got opioid and anesthetic agent sparing properties with improved hemodynamic stability. It has also been used as a sole agent in awake craniotomies and in ICU sedation.⁸³

Opioids

Opioids are administered along with induction agents to blunt the sympathetic response to intubation and surgical stimulation. In a study of opioids bolus administration in brain-injured patients by Schregel et al, they found no rise in ICP despite a transient fall in mean arterial pressure.⁸⁴ Remifentanyl is successfully used along with propofol in TCI-based TIVA technique in neurosurgery cases. Few studies have found that remifentanyl is equally effective as is fentanyl in neurosurgeries, and the recovery profile is better with remifentanyl compared with fentanyl.⁸⁵ Leone et al found that the cough suppression during recovery is better when higher plasma concentration of remifentanyl was used with propofol.⁸⁶ The property of cough suppression during emergence will prevent any rise in ICP in neurosurgical cases.

Benzodiazepines

Benzodiazepines reduce CBF, CMRO₂, and ICP and increase the seizure threshold. The bolus doses were found to reduce MAP thereby CPP in severe TBI patients. Midazolam has been a preferred sedative agent in TBI due to its faster onset and rapid offset of action.⁸⁷ Midazolam is often coadministered with propofol and opioids to allay the anxiousness during sedation.⁴⁴

Muscle Relaxants

The use of muscle relaxants in neurosurgery is widely questioned as the evolving neurosurgery techniques are of short duration and minimally invasive procedures. Muscle relaxants are used along with the induction agent to favor intubation. Muscle relaxants are associated with post-operative residual paralysis. Mivacurium overcomes this disadvantage as it is a short-acting muscle relaxant. Nowadays, with the use of propofol and remifentanyl infusion, muscle relaxants can be avoided for intubation.⁸⁸

Conclusion

The benefits of TIVA for neurosurgical patients seems abundant. With the advent of innovative technologies, such as target controlled infusion, safe anesthesia can be provided to the patients. The technique is simple, and TIVA is well tolerated by the patients. The intraoperative comfort for the patient and the relaxed brain for surgeon along with early postoperative recovery makes the TIVA preferred by most

neuroanesthetists. TCI use to monitor and administer IV drugs will prevent intraoperative awareness or deep hypnosis. The cost of TCI pumps needs to be balanced against perioperative management and hospital costs, which needs further research.

Conflict of Interest

None.

References

- Magni G, Baisi F, La Rosa I, et al. No difference in emergence time and early cognitive function between sevoflurane-fentanyl and propofol-remifentanyl in patients undergoing craniotomy for supratentorial intracranial surgery. *J Neurosurg Anesthesiol* 2005;17(3):134-138
- Bastola P, Bhagat H, Wig J. Comparative evaluation of propofol, sevoflurane and desflurane for neuroanaesthesia: a prospective randomised study in patients undergoing elective supratentorial craniotomy. *Indian J Anaesth* 2015;59(5):287-294
- Condon-Rall ME. *A Brief History of Military Anesthesia: Anesthesia and Perioperative Care of the Combat Casualty*. Washington, DC: The Borden Institute, Office of the Surgeon General, US Dept of the Army; 2000:855-896
- Struys MMRF, Absalom AR, Shafer S. Intravenous drug delivery systems. In: Miller RD, ed. 8th ed. *Miller's Anesthesia*. Philadelphia: Elsevier Inc.; 2015:920
- Schifilliti D, Grasso G, Conti A, Fodale V. Anaesthetic-related neuroprotection: intravenous or inhalational agents? *CNS Drugs* 2010;24(11):893-907
- Sakabe T, Matsumoto M. Effects of anaesthetic agents and other drugs on cerebral blood flow, metabolism and intracranial pressure. In: Cottrell JE, Young WL, eds. 5th ed. *Cottrell and Young's Neuroanaesthesia*. Philadelphia: Elsevier; 2010:78-94
- Petersen KD, Landsfeldt U, Cold GE, et al. Intracranial pressure and cerebral hemodynamic in patients with cerebral tumors: a randomized prospective study of patients subjected to craniotomy in propofol-fentanyl, isoflurane-fentanyl, or sevoflurane-fentanyl anesthesia. *Anesthesiology* 2003;98(2):329-336
- Hans P, Bonhomme V. Why we still use intravenous drugs as the basic regimen for neurosurgical anaesthesia. *Curr Opin Anaesthesiol* 2006;19(5):498-503
- Deiner S. Highlights of anesthetic considerations for intraoperative neuromonitoring. *Semin Cardiothorac Vasc Anesth* 2010;14(1):51-53
- Todd MM, Warner DS, Sokoll MD, et al. A prospective, comparative trial of three anesthetics for elective supratentorial craniotomy. Propofol/fentanyl, isoflurane/nitrous oxide, and fentanyl/nitrous oxide. *Anesthesiology* 1993;78(6):1005-1020
- Prabhakar H, Singh GP, Mahajan C, Kapoor I, Kalaivani M, Anand V. Intravenous versus inhalational techniques for rapid emergence from anaesthesia in patients undergoing brain tumour surgery: a Cochrane systematic review. *J Neuroanaesth Crit Care* 2017;4:23-35
- Debailleul AM, Fichten A, Krivosic-Horber R. Target-controlled infusion with propofol for neuro-anesthesia [Article in French] *Ann Fr Anesth Reanim* 2004;23(4):375-382
- Zeiler FA, Teitelbaum J, West M, Gillman LM. The ketamine effect on ICP in traumatic brain injury. *Neurocrit Care* 2014;21(1):163-173
- Wang X, Ding X, Tong Y, et al. Ketamine does not increase intracranial pressure compared with opioids: meta-analysis of randomized controlled trials. *J Anesth* 2014;28(6):821-827
- Hassan WMNW, Nasir YM, Zaini RHM, Shukeri WFWM. Target-controlled infusion propofol versus sevoflurane anaesthesia for emergency traumatic brain surgery: comparison of the outcomes. *Malays J Med Sci* 2017;24(5):73-82

- 16 Qureshi H, Mithaiwala H, Ezell J, Maurtua M. Anesthetic management of traumatic brain injury. *Clin Med Rev Case Rep* 2017;4:159
- 17 Total Intravenous Anesthesia Using a Target-Controlled Infusion—A Pocket Reference. 2nd ed. College of Anesthesiologists, Academy of Medicine Malaysia; 2013
- 18 Campbell L, Engbers FH, Kenny GN. Total intravenous anaesthesia. *CPD Anaesthesia* 2001;3:109–119
- 19 Lamperi M, Ashiq F. TCI and TIVA in neurosurgery: considerations and techniques. In: Absalom AR, Maison KP, eds. *Total Intravenous Anesthesia and Target Controlled Infusions*. Gewerbestrasse: Springer International Publishing AG; 2017: 561–570
- 20 Yuill G, Simpson M. An introduction to Intravenous anaesthesia. *Br J Anaesth* 2002;2:24–26
- 21 Glen JB. The development of 'Diprifusor': a TCI system for propofol. *Anaesthesia* 1998;53(Suppl 1) :13–21
- 22 Yeganeh N, Roshani B, Yari M, Almasi A. Target-controlled infusion anesthesia with propofol and remifentanyl compared with manually controlled infusion anesthesia in mastoidectomy surgeries. *Middle East J Anaesthesiol* 2010;20(6):785–793
- 23 Ozkose Z, Ercan B, Unal Y, et al. Inhalation versus total intravenous anesthesia for lumbar disc herniation: comparison of hemodynamic effects, recovery characteristics, and cost. *J Neurosurg Anesthesiol* 2001;13(4):296–302
- 24 Nimmo AF, Cook TM. Total intravenous anaesthesia. In: Pandit JJ, Cook TM, eds. *5th National Audit Project (NAP5). Accidental Awareness during General Anaesthesia in the United Kingdom and Ireland Report and Findings—Chapter 18. The Royal College of Anaesthetists and the Association of Anaesthetists of Great Britain and Ireland*; 2014:151–158
- 25 Hans P, Bonhomme V, Born JD, Maertens de Noordhout A, Brichant JF, Dewandre PY. Target-controlled infusion of propofol and remifentanyl combined with bispectral index monitoring for awake craniotomy. *Anaesthesia* 2000;55(3):255–259
- 26 Dahaba AA. Different conditions that could result in the bispectral index indicating an incorrect hypnotic state. *Anesth Analg* 2005;101(3):765–773
- 27 Ekman A, Lindholm ML, Lennmarken C, Sandin R. Reduction in the incidence of awareness using BIS monitoring. *Acta Anaesthesiol Scand* 2004;48(1):20–26
- 28 Myles PS, Leslie K, McNeil J, Forbes A, Chan MT. Bispectral index monitoring to prevent awareness during anaesthesia: the B-Aware randomised controlled trial. *Lancet* 2004;363(9423) :1757–1763
- 29 Al-Rifai Z, Mulvey D. Principles of total intravenous anaesthesia: practical aspects of using total intravenous anaesthesia. *BJA Educ* 2016;16:276–280
- 30 Ferreira DA, Nunes CS, Antunes L, Lobo F, Amorim P. Practical aspects of the use of target controlled infusion with remifentanyl in neurosurgical patients: predicted cerebral concentrations at intubation, incision and extubation. *Acta Anaesthesiol Belg* 2006;57(3):265–270
- 31 Carney N, Totten AM, O'Reilly C, et al. Guidelines for the management of severe traumatic brain injury. 4th ed. *Neurosurgery* 2017; 80:6–15
- 32 Murthy TVSP. Propofol in neurotrauma. *Indian Journal of Neurotrauma*. 2008;5:41–44
- 33 Hemmer LB, Zeeni C, Bendok BR, Koht A. Intraoperative neurophysiological monitoring for intracranial aneurysm surgery. In: Koht A, Sloan TB, Toleiki S JR, eds. *Monitoring the Nervous System for Anesthesiologists and Other Health Care Professionals*. 2nd ed. Gewerbestrasse, Cham, Switzerland: Springer International Publishing AG; 2017: 353–366
- 34 Lopez JR. Intraoperative neurophysiologic monitoring of cerebral aneurysm surgery and endovascular procedures. *Clin Neurophysiol* 2016;127:e307
- 35 Park JH, Hyun SJ. Intraoperative neurophysiological monitoring in spinal surgery. *World J Clin Cases* 2015;3(9):765–773
- 36 Kim SM, Kim SH, Seo DW, Lee KW. Intraoperative neurophysiologic monitoring: basic principles and recent update. *J Korean Med Sci* 2013;28(9):1261–1269
- 37 Wang AC, Than KD, Etame AB, La Marca F, Park P. Impact of anesthesia on transcranial electric motor evoked potential monitoring during spine surgery: a review of the literature. *Neurosurg Focus* 2009;27(4):E7
- 38 Lo YL, Dan YF, Tan YE, et al. Intraoperative motor-evoked potential monitoring in scoliosis surgery: comparison of desflurane/nitrous oxide with propofol total intravenous anesthetic regimens. *J Neurosurg Anesthesiol* 2006;18(3):211–214
- 39 Clapcich AJ, Emerson RG, Roye DP Jr, et al. The effects of propofol, small-dose isoflurane, and nitrous oxide on cortical somatosensory evoked potential and bispectral index monitoring in adolescents undergoing spinal fusion. *Anesth Analg* 2004;99(5):1334–1340
- 40 Sloan TB, Toleikis JR, Toleikis SC, Koht A. Intraoperative neurophysiological monitoring during spine surgery with total intravenous anesthesia or balanced anesthesia with 3% desflurane. *J Clin Monit Comput* 2015;29(1):77–85
- 41 Konstantopoulos K, Makris A, Moustaka A, Karmanioliou I, Konstantopoulos G, Mela A. Sevoflurane versus propofol anesthesia in patients undergoing lumbar spondylodesis: a randomized trial. *J Surg Res* 2013;179(1):72–77
- 42 Hans P, Marechal H, Bonhomme V. Effect of propofol and sevoflurane on coughing in smokers and non-smokers awakening from general anaesthesia at the end of a cervical spine surgery. *Br J Anaesth* 2008;101(5):731–737
- 43 Casati A, Fanelli G, Casaletti E, Colnaghi E, Cedrati V, Torri G. Clinical assessment of target-controlled infusion of propofol during monitored anesthesia care. *Can J Anaesth* 1999;46(3):235–239
- 44 Ghisi D, Fanelli A, Tosi M, Nuzzi M, Fanelli G. Monitored anesthesia care. *Minerva Anesthesiol* 2005;71(9):533–538
- 45 Candiotti KA, Bergese SD, Bokesch PM, Feldman MA, Wisemandle W, Bekker AY; MAC Study Group. Monitored anesthesia care with dexmedetomidine: a prospective, randomized, double-blind, multicenter trial. *Anesth Analg* 2010;110(1):47–56
- 46 Meyer FB, Bates LM, Goerss SJ, et al. Awake craniotomy for aggressive resection of primary gliomas located in eloquent brain. *Mayo Clin Proc* 2001;76(7):677–687
- 47 Blanshard HJ, Chung F, Manninen PH, Taylor MD, Bernstein M. Awake craniotomy for removal of intracranial tumor: considerations for early discharge. *Anesth Analg* 2001;92(1):89–94
- 48 Sinha PK, Koshy T, Gayatri P, Smitha V, Abraham M, Rathod RC. Anesthesia for awake craniotomy: a retrospective study. *Neurol India* 2007;55(4):376–381
- 49 Lobo F, Beiras A. Propofol and remifentanyl effect-site concentrations estimated by pharmacokinetic simulation and bispectral index monitoring during craniotomy with intraoperative awakening for brain tumor resection. *J Neurosurg Anesthesiol* 2007;19(3):183–189
- 50 Ard JL Jr, Bekker AY, Doyle WK. Dexmedetomidine in awake craniotomy: a technical note. *Surg Neurol* 2005;63(2):114–116, discussion 116–117
- 51 Rozet I. Anesthesia for functional neurosurgery: the role of dexmedetomidine. *Curr Opin Anaesthesiol* 2008;21(5):537–543
- 52 Garavaglia MM, Das S, Cusimano MD, et al. Anesthetic approach to high-risk patients and prolonged awake craniotomy using dexmedetomidine and scalp block. *J Neurosurg Anesthesiol* 2014;26(3):226–233
- 53 Pereira LCM, Oliveira KM, L'Abbate GL, Sugai R, Ferreira JA, da Motta LA. Outcome of fully awake craniotomy for lesions near the eloquent cortex: analysis of a prospective surgical series of 79 supratentorial primary brain tumors with long follow-up. *Acta Neurochir (Wien)* 2009;151(10):1215–1230

- 54 Deras P, Moulinié G, Maldonado IL, Moritz-Gasser S, Duffau H, Bertram L. Intermittent general anesthesia with controlled ventilation for asleep-awake-asleep brain surgery: a prospective series of 140 gliomas in eloquent areas. *Neurosurgery* 2012;71(4):764–771
- 55 Nagashima M, Kunisawa T, Takahata O, Iwasaki H. [Dexmedetomidine infusion for sedation during awake intubation [Article in Japanese]. *Masui* 2008;57(6):731–734
- 56 Bergese SD, Khabiri B, Roberts WD, Howie MB, McSweeney TD, Gerhardt MA. Dexmedetomidine for conscious sedation in difficult awake fiberoptic intubation cases. *J Clin Anesth* 2007;19(2):141–144
- 57 Mingo OH, Ashpole KJ, Irving CJ, Rucklidge MW. Remifentanyl sedation for awake fiberoptic intubation with limited application of local anaesthetic in patients for elective head and neck surgery. *Anaesthesia* 2008;63(10):1065–1069
- 58 Sharan R, Mohan B, Kaur H, Bala A. Efficacy and safety of propofol versus midazolam in fiberoptic endotracheal intubation. *Anesth Essays Res* 2016;10(3):437–445
- 59 Zhang X, He W, Wu X, Zhou X, Huang W, Feng X. TCI remifentanyl vs. TCI propofol for awake fiber-optic intubation with limited topical anesthesia. *Int J Clin Pharmacol Ther* 2012;50(1):10–16
- 60 Jackson DL, Proudfoot CW, Cann KF, Walsh T. A systematic review of the impact of sedation practice in the ICU on resource use, costs and patient safety. *Crit Care* 2010;14(2):R59
- 61 Barr J, Fraser GL, Puntillo K, et al; American College of Critical Care Medicine. Clinical practice guidelines for the management of pain, agitation, and delirium in adult patients in the intensive care unit. *Crit Care Med* 2013;41(1):263–306
- 62 Skoglund K, Enblad P, Marklund N. Monitoring and sedation differences in the management of severe head injury and subarachnoid hemorrhage among neurocritical care centers. *J Neurosci Nurs* 2013;45(6):360–368
- 63 Oddo M, Crippa IA, Mehta S, et al. Optimizing sedation in patients with acute brain injury. *Crit Care* 2016;20(1):128
- 64 Bratton SL, Chestnut RM, Ghajar J, et al; Brain Trauma Foundation; American Association of Neurological Surgeons; Congress of Neurological Surgeons; Joint Section on Neurotrauma and Critical Care, AANS/CNS. Guidelines for the management of severe traumatic brain injury. XI. Anesthetics, analgesics, and sedatives. *J Neurotrauma* 2007;24(Suppl 1):S71–S76
- 65 Purrucker JC, Renzland J, Uhlmann L, et al. Volatile sedation with sevoflurane in intensive care patients with acute stroke or subarachnoid haemorrhage using AnaConDa®: an observational study. *Br J Anaesth* 2015;114(6):934–943
- 66 Lubisch N, Roskos R, Berkenbosch JW. Dexmedetomidine for procedural sedation in children with autism and other behavior disorders. *Pediatr Neurol* 2009;41(2):88–94
- 67 Hsu YW, Cortinez LI, Robertson KM, et al. Dexmedetomidine pharmacodynamics: part I: crossover comparison of the respiratory effects of dexmedetomidine and remifentanyl in healthy volunteers. *Anesthesiology* 2004;101(5):1066–1076
- 68 Kamibayashi T, Maze M. Clinical uses of alpha2-adrenergic agonists. *Anesthesiology* 2000;93(5):1345–1349
- 69 Hajat Z. Neuroradiology in neurotrauma. In: Prabhakar H, Mahajan C, Kapoor I, eds. *Essentials of Anaesthesia for Neurotrauma*. Boca Raton, Florida, United States: CRC Press, Taylor and Francis Group; 2018: 215–222
- 70 Goettel N, Bharadwaj S, Venkatraghavan L, Mehta J, Bernstein M, Manninen PH. Dexmedetomidine vs propofol-remifentanyl conscious sedation for awake craniotomy: a prospective randomized controlled trial. *Br J Anaesth* 2016;116(6):811–821
- 71 Smith R, Brown J. Midazolam for status epilepticus. *Aust Prescr* 2017;40(1):23–25
- 72 Power KN, Flaatten H, Gilhus NE, Engelsen BA. Propofol treatment in adult refractory status epilepticus. Mortality risk and outcome. *Epilepsy Res* 2011;94(1-2):53–60
- 73 Koerner IP, Brambrink AM. Brain protection by anesthetic agents. *Curr Opin Anaesthesiol* 2006;19(5):481–486
- 74 Kawaguchi M, Furuya H, Patel PM. Neuroprotective effects of anesthetic agents. *J Anesth* 2005;19(2):150–156
- 75 Walder B, Tramèr MR, Seck M. Seizure-like phenomena and propofol: a systematic review. *Neurology* 2002;58(9):1327–1332
- 76 Gupta A, Stierer T, Zuckerman R, Sakima N, Parker SD, Fleisher LA. Comparison of recovery profile after ambulatory anesthesia with propofol, isoflurane, sevoflurane and desflurane: a systematic review. *Anesth Analg* 2004;98(3):632–641
- 77 Wysowski DK, Pollock ML. Reports of death with use of propofol (Diprivan) for nonprocedural (long-term) sedation and literature review. *Anesthesiology* 2006;105(5):1047–1051
- 78 Flower O, Hellings S. Sedation in traumatic brain injury. *Emerg Med Int* 2012;2012:637171
- 79 Grewal A. Dexmedetomidine: New avenues. *J Anaesthesiol Clin Pharmacol* 2011;27(3):297–302
- 80 Peng K, Wu S, Liu H, Ji F. Dexmedetomidine as an anesthetic adjuvant for intracranial procedures: meta-analysis of randomized controlled trials. *J Clin Neurosci* 2014;21(11):1951–1958
- 81 Wang X, Ji J, Fen L, Wang A. Effects of dexmedetomidine on cerebral blood flow in critically ill patients with or without traumatic brain injury: a prospective controlled trial. *Brain Inj* 2013;27(13-14):1617–1622
- 82 Farag E, Kot M, Podolyak A, et al. The relative effects of dexmedetomidine and propofol on cerebral blood flow velocity and regional brain oxygenation: A randomised noninferiority trial. *Eur J Anaesthesiol* 2017;34(11):732–739
- 83 Carollo DS, Nossaman BD, Ramadhyani U. Dexmedetomidine: a review of clinical applications. *Curr Opin Anaesthesiol* 2008;21(4):457–461
- 84 Schregel W, Weyerer W, Cunitz G. Opioids, cerebral circulation and intracranial pressure [article in German]. *Anaesthesist* 1994;43(7):421–430
- 85 Balakrishnan G, Raudzens P, Samra SK, et al. A comparison of remifentanyl and fentanyl in patients undergoing surgery for intracranial mass lesions. *Anesth Analg* 2000;91(1):163–169
- 86 Leone M, Rousseau S, Avidan M, et al. Target concentrations of remifentanyl with propofol to blunt coughing during intubation, cuff inflation, and tracheal suctioning. *Br J Anaesth* 2004;93(5):660–663
- 87 Urwin SC, Menon DK. Comparative tolerability of sedative agents in head-injured adults. *Drug Saf* 2004;27(2):107–133
- 88 McNeil IA, Culbert B, Russell I. Comparison of intubating conditions following propofol and succinylcholine with propofol and remifentanyl 2 micrograms kg-1 or 4 micrograms kg-1. *Br J Anaesth* 2000;85(4):623–625