

STUDY ON THE USE OF IMMOBILIZATION DEVICES IN PERIODONTAL DISEASE AND THEIR IMPACT ON PERIODONTAL CONDITION

Mădălina Nicoleta Matei¹, Dorina Cerasella Șincar²,
Sergiu Focșăneanu³, Kamel Earar^{2*}

1 "Dunărea de Jos" University – Galați, Romania, Faculty of Dentistry

2 "Apollonia" University - Iași, Romania, Faculty of Dentistry

3 Dental Practitioner - Iași

*Corresponding author: Kamel Earar, Assoc. Professor, PhD, DMD
"Apollonia" University
- Iași, Romania

ABSTRACT

Aim of the study is to assess the change of periodontal parameters in a lot of patients with periodontal disease, in which the management of mobile teeth had as an aim the recovery of the periodontal function by means of immobilization of mobile teeth. **Material and methods** The study lot included 35 patients, aged between 42-65, with chronic periodontitis, divided into two lots: control lot of 17 patients – with periodontal disease and conservatory periodontal treatment, a study lot of 18 patients – with periodontal disease and that have been applied different types of immobilization devices. Clinical and assessment parameters have been developed after the etiological therapy and the application of immobilization devices had been finished. **Results** There is a significant difference between the two lots, which is independent of the initial depth of the bag. Clinical attachment gain is significant in both the control and the study group. Plaque index was significantly reduced in both groups relative to the initial values and between the 2 groups. **Conclusions** By comparing periodontal condition after the application of immobilization devices, there can be observed a significant difference between the 2 groups, the final significant difference being independent of the initial depth of the bag. Clinical attachment gain is significant in both the control and in the study group, 1,15mm in the study group compared to 1,92mm in the control group. Plaque index was significantly reduced in both groups compared to initial values and between the 2 groups. The immobilization of periodontal teeth produced immediate effects, both functional and aesthetic and psychological ones; the decreased mobility allowing the reestablishment of periodontal balance, the decrease of inflammation and a better tissue healing and attachment gain.

Keywords: periodontal disease, immobilization devices

INTRODUCTION

Clinical management of mobile teeth is a difficult issue. Tooth mobility resulting from the progression of periodontal disease currently benefits from numerous therapeutic options; temporary immobilization, semi-permanent and permanent teeth being able to

improve the prognosis of teeth and to provide stability in periodontal treatment.

AIM OF THE STUDY

The study aims to assess the change of periodontal parameters in a lot of patients with periodontal disease, in which the

management of mobile teeth had as an aim the recovery of the periodontal function by means of immobilization of mobile teeth, especially in the frontal area as to achieve occlusal stability that allowed to maintain mobile teeth on the arch and the periodontal health.

MATERIAL AND METHODS

The study lot included 35 patients, aged between 42-65, with chronic periodontitis, divided into two lots: control lot of 17 patients – with periodontal disease and conservatory periodontal treatment, a study lot of 18 patients – with periodontal disease and that have been applied different types of immobilization devices.

All patients received the etiologic treatment, and, depending on the clinical condition, temporary, these were applied temporary, semi-permanent or final immobilization devices. The assessment of clinical parameters has been made both at the beginning of treatment and in 6 months after the etiologic treatment and the application of immobilization devices.

Clinical and assessment parameters that have been used:

- depth of exploring
- loss of attachment
- bleeding index
- plaque index

Recording has been made before the treatment and after the completion of

etiologic therapy and the application immobilization devices.

RESULTS

Clinical cases:

Clinical case: Patient D.C., aged 42, chronic marginal periodontitis, severe form.

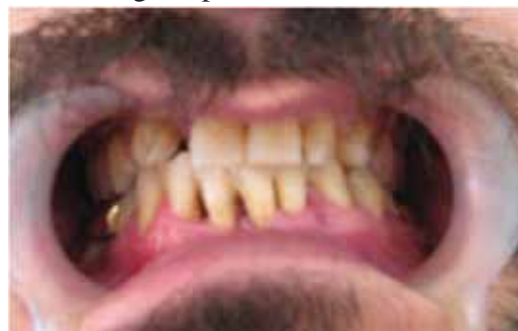

Figure 1. Patient D.C., aged 42, Chronic periodontitis severe stage

When examined, the patient had tooth mobility especially in mandibular incisors, poor hygiene, with plaque and tartar deposits (fig.1). A semi permanent periodontal immobilization with Fiber Splint Multi-Layer and composite fig. 2, 3 has been fixed after the etiologic treatment.



Figure 2. Patient D. The choice of immobilization splint

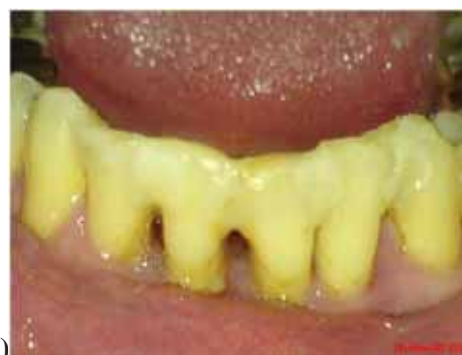
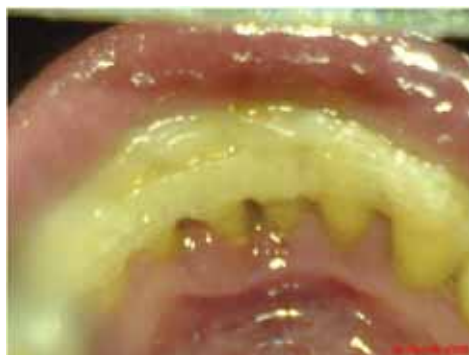
Figure 3. Patient D.C., aged 42 and Periodontal immobilization with Fiber Splint Multi-Layer

and composite splint - lingual (a) and vestibular (b) view

Clinical case: Patient M.V., deep chronic marginal periodontitis.

The patient complained about dental mobility, especially in the front group mandibular, aesthetic disorders linked to lack of 41 tooth on the arch, lost due to tooth mobility, gingival bleeding and the existence of tartar deposits (fig. 4). The upper and subgingival scaling, surfacing and

professional brushing have been done after a clinical examination and Rx. Before completing other treatments (endodontic, surgical, prosthetic), a non-invasive method was chosen for stabilizing mobile teeth – the application of an immobilizing rail, a lingual plate with the extracoronal aggregation and the application of an artificial substitute for the replacement of a missing tooth (fig.5,6).

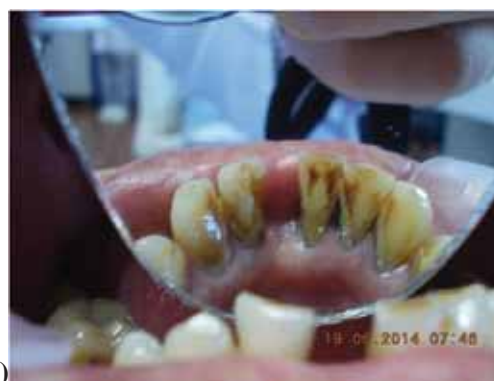
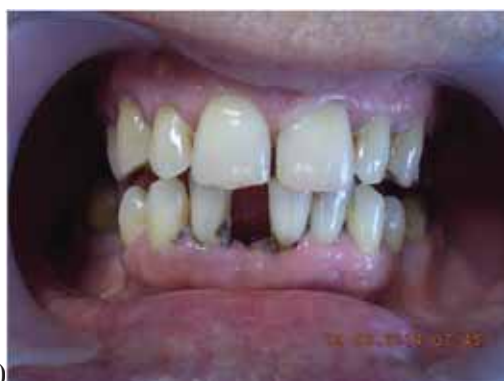
Figure 4. Patient M.V. Initial clinical view–vestibular side (a) lingual side (b) frontal mandibular group

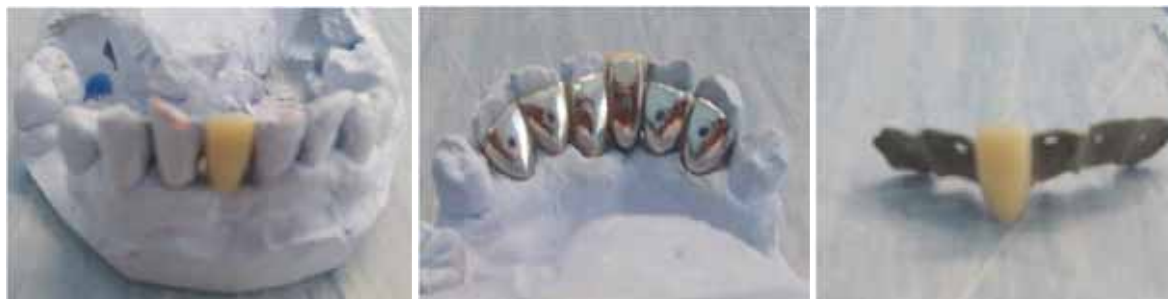

Figure 5. Patient M.V. Immobilization rail

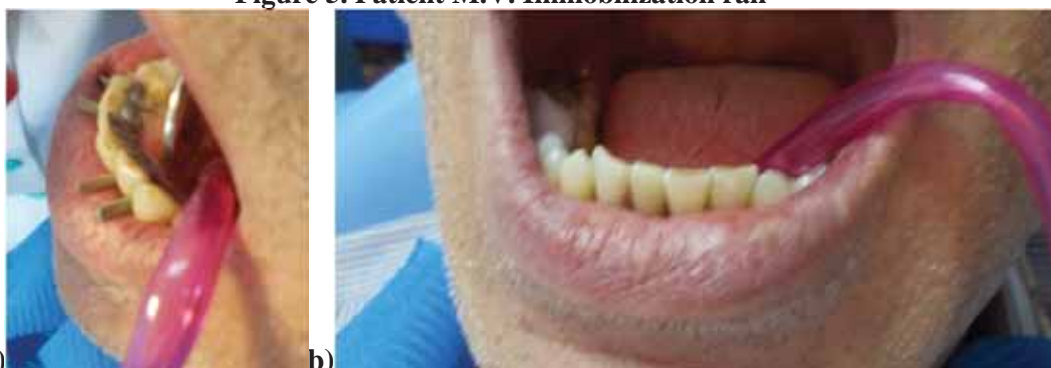

Figure 6. Pat M. Cimentation of immobilization rail (a) and the final view of immobilization (b)

Clinical manifestations of the marginal periodontium in patients investigated (Table 2) consisted of gingival inflammation,

gingival recession of varying degrees, periodontal bags and in more than half of the patients were diagnosed with migration of

teeth of different degrees, both in the sagittal as well as in the vertical planes (fig.9).

There is a significant difference between the two lots, which is independent of the initial bag depth (Table 4, fig.11).

Clinical attachment gain is significant in

both the control and in the study lots (Table 5). It was of 1,15 mm in the study lot versus 1.92 mm in the control lot (fig. 12).

Plaque index (Table 6) has been reduced significantly in both lots compared to initial values and between the two lots (fig. 13).

Table 1. Features of the lot of patients

Features	Control (N=17)	Study(N=18)
Average age	51	53
Men	9	11
Women	8	7
Examined teeth per patient (average)	27	28

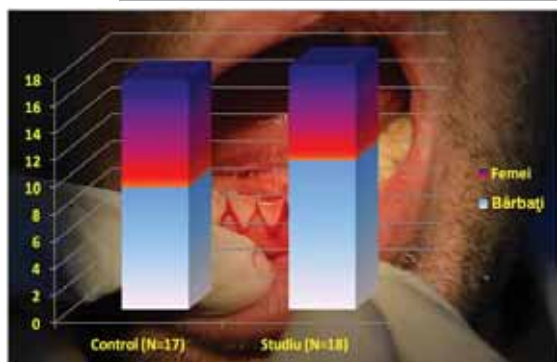


Figure 7. Patients distribution by gender

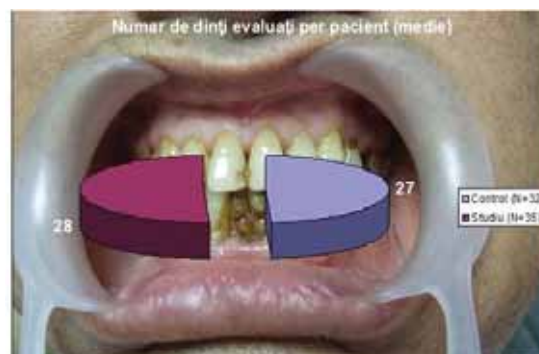


Figure 8. Average number of examined teeth

Table 2. Clinical assessment of periodontal symptoms upon presentation

Periodontal disease symptoms	% out of the number of patients
Gingival overgrowth	2%
Inflammation	90 %
Tooth mobility	59%
False/true bags	42%
Gingival recession	48%
Gingival bleeding	10%

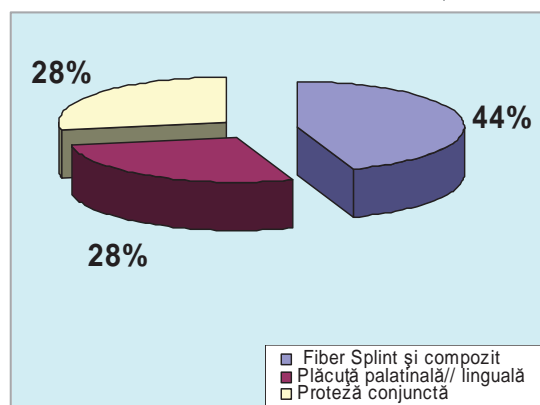



Figure 9. Clinical assessment of periodontal symptoms

Figure 10. Types of immobilization devices applied

Table 3. Types of immobilization devices applied

Type of device	Number of patients
Extemporaneous immobilization with Fiber and Composite Splint	8
Immobilization splint– palatal/lingual plate cemented with glass-ionomer	5
Conjunct prosthesis	5

Table 4. Reducing the depth of periodontal bags after the etiologic therapy and the application of immobilization devices

Lot	Average bag depth (mm)	
	Study	Control
Pre-treatment	5,79	5,62
Post-treatment	3,59	4,11
Difference	2,19	1,51

Table 5. Difference in clinical attachment between the two lots

Lot	Average clinical attachments (mm)	
	Study	Control
Pre-treatment	5,8	5,34
Post-treatment	3,87	4,17
Difference	1,92	1,15

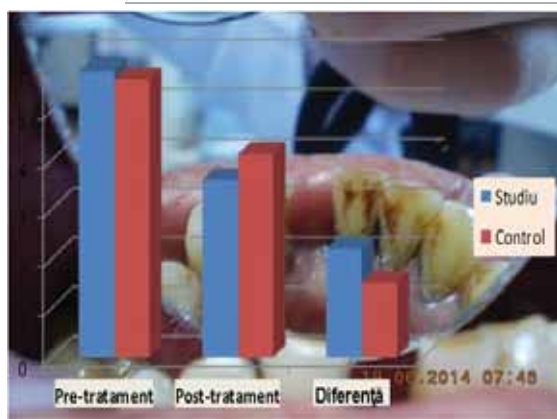


Figure 11. Reduction of periodontal bags depth

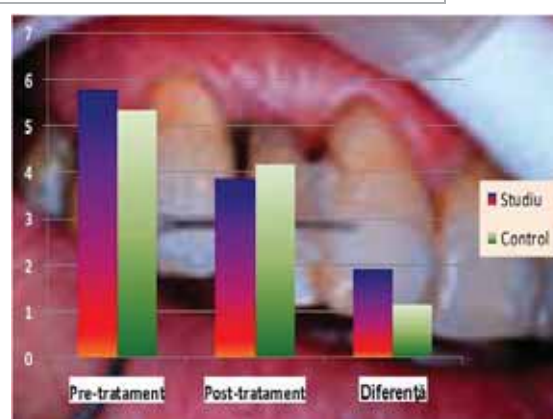


Figure 12. The degree of clinical attachment – comparison between the two lots

Table 6. Difference in average plaque index between the two lots

Lot	Average plaque index (mm)	
	Study	Control
Pre-treatment	1,87	1,7
Post-treatment	0,85	1,5
Difference	1,17	0,65

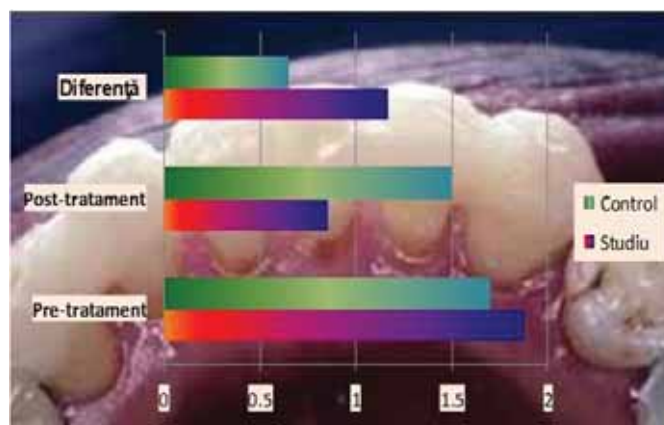


Figure 13. Average plaque index

DISCUSSIONS

Methods of contention in periodontal disease often depends more on periodontal disease prognosis, efficiency of complex treatment, stability in time of the results and less on the technical solution applied [1].

In most cases, the contention must be temporary and provisional, immobilizations (splints) should be used only when they are required to obtain occlusal stability, or to replace missing teeth [2, 3].

Applying a permanent splint does not necessarily reduce the effect of harmful forces or the mobility in a predictable way [4].

When an immobilization device is applied in the periodontal disease, a set of principles should be followed [5]:

- Multidirectional teeth engagement (at least on two planes) when contention is made of a front group addresses. In the posterior teeth due to their morphological features (pluriradicular teeth), immobilization in a single plane could be made.
- Protection of periodontal support – by immobilization, a teeth contention is achieved that prevents the tooth mobility into all directions and that allows to desmodontium at a low amplitude of movements.
- The inclusion of the largest possible number of teeth. Expanding contention can be made

on an arcade/semiarcade with the protection of the marginal periodontium in the joint between the tooth and the device.

- Applying immobilization system away from the axis of rotation of teeth. Vertical forces on the occlusal surface are sent on a vertical axis to hipomoclion. Any deviation from the longitudinal axis passing through this point is an eccentric occlusal force.

- Maximum saving of tooth substance. Contention systems involve many elements of the dental arch. In relation to mobility of teeth and coronary volume, the types of aggregation elements can be chosen.

- Pulp organ protection. It is recommended wherever possible to respect the pulp vitality. The depulcation of vital teeth is sometimes required in (endo-periodontal syndrome) or in case of immobilization rails with intraradicular pivot.

- Best occlusal relations - no harmful forces on teeth should be allowed. Interdental contacts must be evenly distributed and take place in the center of the occlusal surface of teeth, and the transverse decomposition of forces de performed correctly.

- Suppression of the point of contact pathology related to the abnormal transmission of forces, migration, tilting, compaction of food.

- Respecting the height of the lower level,

- Restoring optimal parameters of the stomatognathic system functions. The immobilization device should allow a good artificial and self-cleaning

- Production using simple and effective means with current materials at an affordable cost price.

In the studied lot, we found that, the longer was the time from the onset of tooth mobility or dental arch gap, the higher were the changes in the dental arches, and therefore, the occlusal disorders.

He conducted study showed that the application of immobilization devices in patients included in the study influenced individually the status of paradontium.

The immobilization has been indicated when the functional balancing has not been sufficient to stabilize lesions. The assessment of the clinical form of the disease – the degree of evolution of the affected teeth should be made by means of a deep clinical investigations, completed by paraclinical ones (6). The assessment of the moment of application and type of immobilization device is up to the practitioner, who, based on his experience and the interpretation of the clinical and laboratory results, can in time ensure success and effectiveness.

The immobilization of periodontal teeth has been made as a transition or temporary measure during the early stages of periodontal therapy, whether before the periodontal surgery, or during the restorative therapy stage when immobilization devices had been permanent. The immobilization of periodontal teeth, however, has not been used as the only method for obtaining tooth stability. The cause of increased tooth mobility and of pathological teeth migration should always be determined. Permanent immobilization was considered only after periodontal inflammation has been treated. In some cases, due to the control and treatment of inflammation that was treated correctly,

the mobility decreased and, therefore, the immobilization was not necessary. The occlusal stability and the control of excessive occlusal forces have been obtained before immobilization. Frequently, the occlusal forces change eliminates the need for immobilization because the tooth reduces its mobility and has a much more stable position.

CONCLUSIONS

1. The immobilization systems prevent random movements of teeth with pathological mobility, driving the masticatory forces in the longitudinal axis of the tooth and distributing them equally to all teeth of the system.
2. In the absence of tooth immobilization, a part of teeth on the arcade are overworked by occlusal trauma, and others become dysfunctional.
3. Designing treatment using immobilization devices in patients with periodontal disease is based on the particularities of the clinical picture, the degree of damage to deep parodontium, presence or absence of occlusal plane deleveling, interocclusal relations and possibilities of creating an optimal occlusal balance.
4. Radiological examination results confirmed the presence of functional overload of the teeth by widening the periodontal space and the existence of resorption signs of periodontal bone tissue and a varying degree of inclination towards the mesial teeth neighboring with breaches in the mandible.
5. Comparing the periodontal status after the application of the immobilization devices, there is a significant difference between the 2 lots, the final significant difference being independent of the initial depth of the bag.
6. The clinical attachment gain is significant in both the control and in the study lots, it was of 1,15mm in the study lot compared

- to the control lot of 1,92mm.
7. Plaque index was significantly reduced in both lots compared to initial values and between the 2 lots.
 8. The immobilization of periodontal teeth produced immediate effects, both functional, aesthetic and psychological; a decreased mobility allowing to restore a periodontal balance, decrease inflammation, improve tissue healing and attachment gain.

REFERENCES

- 1 Dumitriu H.T Parodontologie, București, ed. a 9-a, 2009
- 2 Bernal G, Carvajal JC, Muñoz-Viveros CA. Clinical management of mobile teeth. J Contemp Dent Pract 2002 November;(3)4:010-022.
- 3 Forabosco A, Grandi T, Cotti B. The importance of splinting of teeth in the therapy of periodontitis. Minerva Stomatol. 2006 Mar; 55(3):87-97.
- 4 Byrne PJ, Irwin C, Mullally B, Allen E, Ziada H. Periodontal problems associated with compromised anterior teeth. Dent Update. 2008 Jan-Feb;35(1):21-2, 24-6, 28.
- 5 Mosedale RF. Current indications and methods of periodontal splinting. Dent Update. 2007 Apr;34(3):168-70, 173-4, 176-8.
- 6 Ritter AV. Periodontal splinting. J Esthet Restor Dent. 2004;16(5):329-30.