

Proceed with Caution: Low Vision and Driving, **PAGE 74**

REVIEW[®] OF OPTOMETRY

April 15, 2018

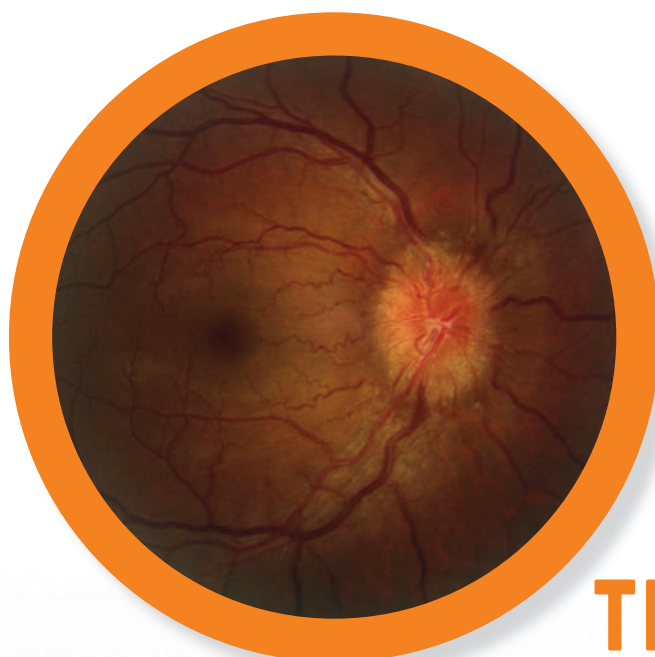
www.reviewofoptometry.com

11th Annual Pharmaceuticals Report

KNOW YOUR SYSTEMIC MEDS:

THE TOP

1



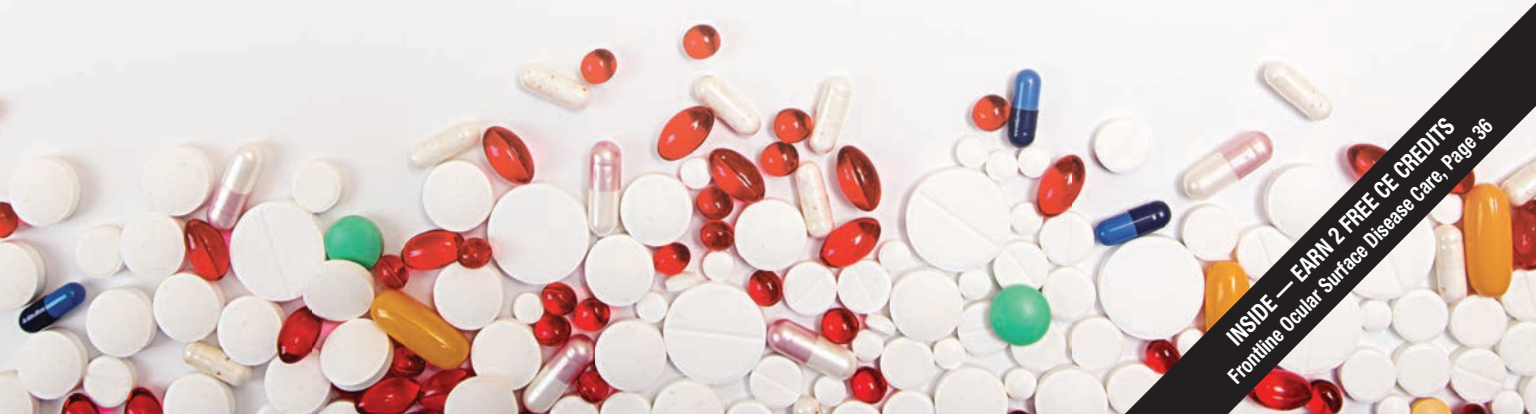TO TRACK

Here's what you need to know about the ocular effects of the heavy-hitters. **PAGE 44**

One Size *Won't* Fit All:
Treating Ocular Infection
PAGE 52

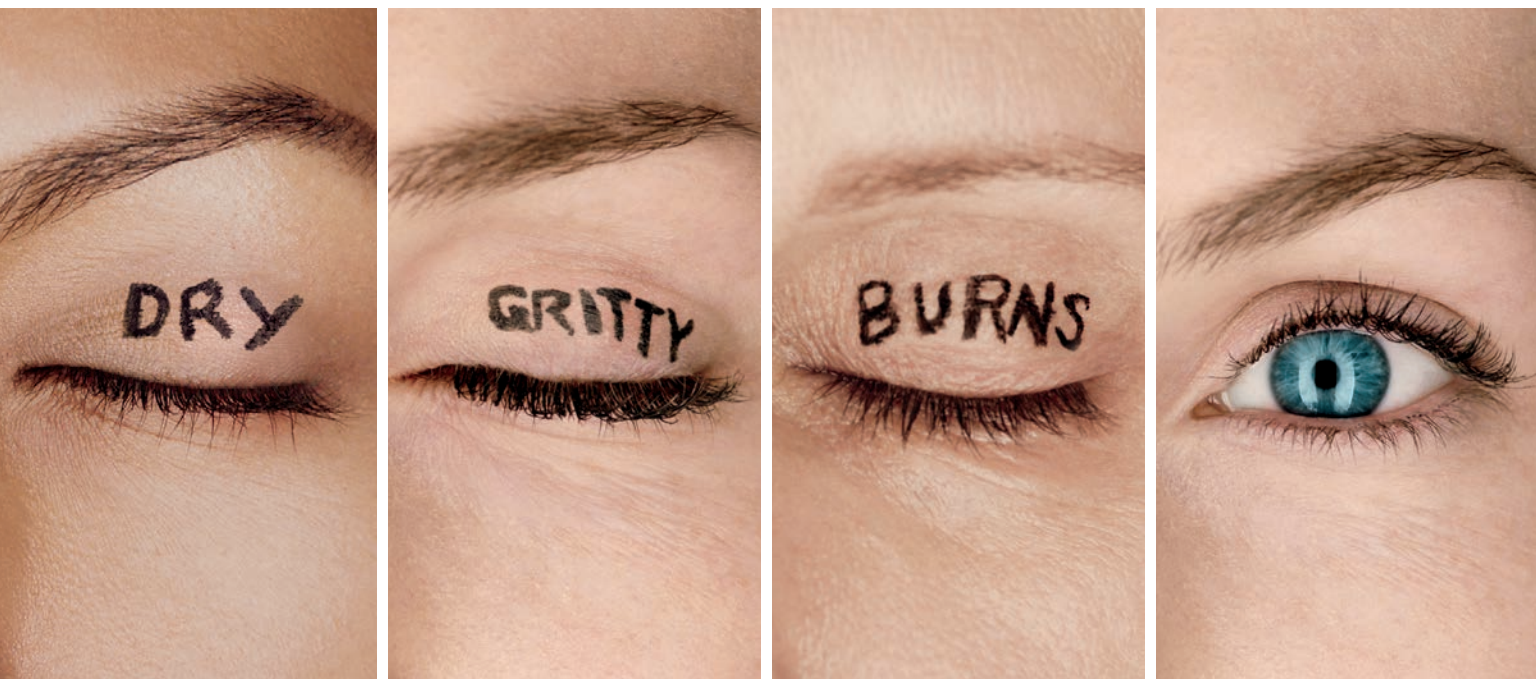Sizing Up Anti-inflammatories
in Dry Eye Disease
PAGE 62

Protocols and Pitfalls in
Topical Steroid Use
PAGE 66



INSIDE — EARN 2 FREE CE CREDITS
Frontline Ocular Surface Disease Care, Page 36

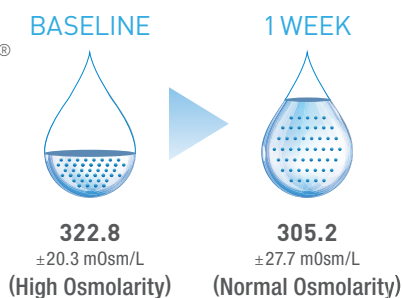
TheraTears® is clinically proven to reduce the signs and symptoms of dry eyes¹



TheraTears® Dry Eye Therapy Lubricant Eye Drops with Osmo-Correction®

- Reduced patient symptoms (OSDI) up to 33%
- Restored tears to normal osmolarity levels within one week

Average Tear Osmolarity Level



More than eye drops,
dry eye therapy™

theratears.com

Study sponsored by Akorn

Reference: 1. Ng L, Nguyen A, Karpecki P, Houtman D. Evaluation of Tear Osmolarity Over Time with Sustained Use of TheraTears® Lubricant Eye Drops. Poster presented at: The American Academy of Optometry Annual Meeting; November 9-12, 2016; Anaheim, CA.

© 2017 Akorn Consumer Health | A Division of Akorn, Inc. | M16-039

IN THE NEWS

Hydrogel and overnight orthokeratology (OK) contact lens (CL) wear can increase tear film osmolarity, a new study finds. Researchers observed osmolarity values in non-CL wearers and those who have worn hydrogel and overnight OK lenses for at least three years, and found osmolarity was within normal limits in all groups, although it was significantly lower in non-CL wearers compared with hydrogel and OK lens wearers. Osmolarity returns to baseline one month after discontinuation of CL wear.

Nieto-Bona A, Nombela-Palomo M, Felipe-Márquez G, Teus MA. Tear film osmolarity in response to long-term orthokeratology treatment. *Eye Contact Lens*. 2018;44(2):85-90.

Researchers found day one post-op assessment with swept-source OCT provided better visualization of the macula than spectral-domain (SD) OCT in patients treated with pars plana vitrectomy and gas tamponade. For patients with rhegmatogenous retinal detachment, SD-OCT provided good visualization on day one in 35.3% of eyes compared with 73.5% of eyes using SS-OCT's line scan protocol. In eyes with macular holes, the rates were 59.3% with SD-OCT and 88.9% with SS-OCT's line scan protocol.

Ahn SJ, Park SH, Lee BR. Visualization of the macula in gas-filled eyes: Spectral domain optical coherence tomography versus swept-source optical coherence tomography. *Retina*. 2018;38(3):480-9.

Clinicians should endeavor to refer patients with orbital-floor trap-door blowout fractures with incarcerated tissue for surgery within eight days, according to new research. The study found ocular motility outcomes were significantly better for patients who underwent repair surgery within eight days of injury than those after eight days.

Yamanaka Y, Watanabe A, Sotozono C, Kinoshita S. Impact of surgical timing of postoperative ocular motility in orbital blowout fractures. *Br J Ophthalmol*. 2018;102(3):398-403.

Hope For Noninvasive ICP Monitoring

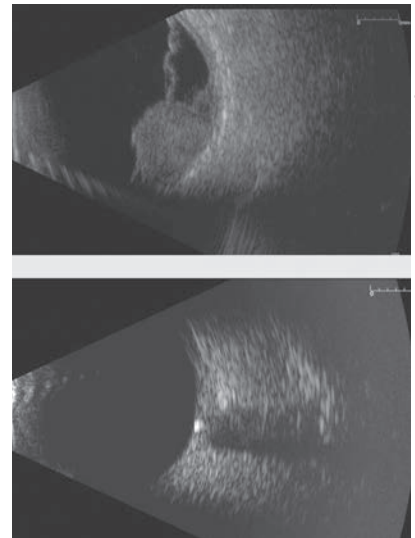
Ultrasonography may one day help patients avoid a painful lumbar puncture.

By Rebecca Hepp, Managing Editor

Clinicians have long known intracranial pressure (ICP) plays a critical role in idiopathic intracranial hypertension, and “there has also been debate about its potential role in other disease states such as glaucoma,” says Nate Lighthizer, OD, an associate professor and assistant dean of Clinical Care Services at Oklahoma College of Optometry. “There is current thinking now that perhaps glaucoma is a two-pressure disease: the balance between intraocular pressure and intracranial pressure. So better understanding the role ICP plays in many disease states may be a critical element in the future.”

Unfortunately, the standard test for diagnosing elevated ICP, lumbar puncture (LP), is invasive and painful.¹ Recently, researchers have sought noninvasive methods for dynamically monitoring ICP, and think ultrasonography may be the key.¹

Researchers in China used ultrasonography to measure the optic nerve sheath diameter (ONSD) in 60 patients admitted for lumbar puncture. After LP, the patients were split into two groups, those with elevated ICP between 200mm H₂O and 300mm H₂O and those above 300mm H₂O. The investigators noted a strong



Photos: Nate Lighthizer, OD

Ultrasonography can reveal any number of issues, such as choroidal melanoma with overlying retinal detachment, top, and optic nerve drusen, bottom. Recently, researchers found measuring optic nerve sheath diameter with ultrasonography may be a noninvasive method of monitoring ICP.

correlation between the ONSD and ICP values on admission, and a strong correlation between the change in ONSD and ICP values one month later. Post-treatment, the elevated ICP and dilated ONSD had returned to normal, the researchers found.¹

Other studies have highlighted ultrasonography's utility in

(continued on page 5)

FDA Hits Opternative with Notice

The Food and Drug Administration (FDA) has advised online refraction company Opternative that its services constitute a medical device and, as such, require “marketing clearance,” according to a letter the agency issued in October, but didn’t publicize until March. The letter indicates that the company, which was sending marketing e-mails as of March 22, has been operating in violation of the Federal Food, Drug, and Cosmetic Act. In the letter, the FDA “requests that Opternative, Inc. immediately cease activities that result in the misbranding or adulteration of the

On-Line Opternative Eye Examination Mobile Medical App device, such as the commercial distribution of the device through your online website.”


“We responded promptly to FDA’s warning letter from October 2017, and we are working diligently to voluntarily comply with all regulatory requirements,” says a representative from Opternative. “We continue to communicate with the FDA on a regular basis to work through the regulatory medical device clearance process with our outside experts.”

The FDA’s letter also says that the agency determined that the app “is a device because it is intended for use in the diagnosis of disease or other conditions or in the cure, mitigation, treatment, or prevention of disease, or to affect the structure or any function of the body.” It also outlines how Opternative can submit for premarket approval and “whether the product may be legally marketed.”

The American Optometric Association (AOA) is counting the FDA’s action as “validation” of its 2016 complaint. “Despite the October 2017 FDA warning letter, Opternative has continued to market their device through 1-800 Contacts, etc. until the filing was made public,” says Clarke Newman, OD, AOA Federal Relations Committee chair.

“We recognize our technology and our new way of helping patients get their prescriptions renewed are viewed as disruptive to those who wish to prohibit emerging technologies from entering the vision prescription renewal space,” said an Opternative representative.

Although the AOA has historically opposed online refraction, a spokesperson underscores that the association supports technologies, so long as they don’t interrupt the patient-doctor relationship.



Opternative just hit a roadblock with an FDA warning letter.

Food and Drug Administration. Inspections, Compliance, Enforcement, and Criminal Investigations. Opternative Inc 10/30/17 Warning Letter. www.fda.gov/iceci/enforcementactions/warningletters/2017/ucm600029.htm.

Clinical Acumen Boosts AI Accuracy

Although artificial intelligence (AI), and the machine learning algorithm that drives it, shows promise as a screening tool for ocular pathology such as diabetic retinopathy (DR), it’s not perfect. But researchers at Google found using a small set of DR cases judged by ophthalmologists and retina specialists can improve the algorithm’s accuracy.¹

The researchers had the clinicians and the algorithm grade retinal fundus images from DR screening programs and then chose the con-

sensus of the retina specialists as the reference standard.

After adding the reference cases “as a tuning dataset,” the investigators looked at the area under the curve (AUC), sensitivity and specificity data between the manual grading and the algorithm. With the new data, the algorithm improved its AUC from 0.934 to 0.986 when screening moderate or worse DR, a boost that enabled the AI system to perform similarly to or even exceed US board-certified ophthalmologists and retina specialists, according to

study author Lily Peng, MD, PhD.^{1,2}

Although reference cases are key to “teach” any deep learning machine to properly screen for DR, creating those standards is time-consuming. The researchers were happy to find using just a small subset of carefully adjudicated cases could make a huge difference in the algorithm’s performance.

1. Krause J, Gulshan V, Rahimy E, et al. Grader variability and the importance of reference standards for evaluating machine learning models for diabetic retinopathy. *Ophthalmology*. March 12, 2018. [Epub ahead of print].

2. Human adjudication of DR grading enhances machine learning algorithm. *Healio*. March 14, 2018.

Monitoring ICP Sans LP

(continued from page 3)

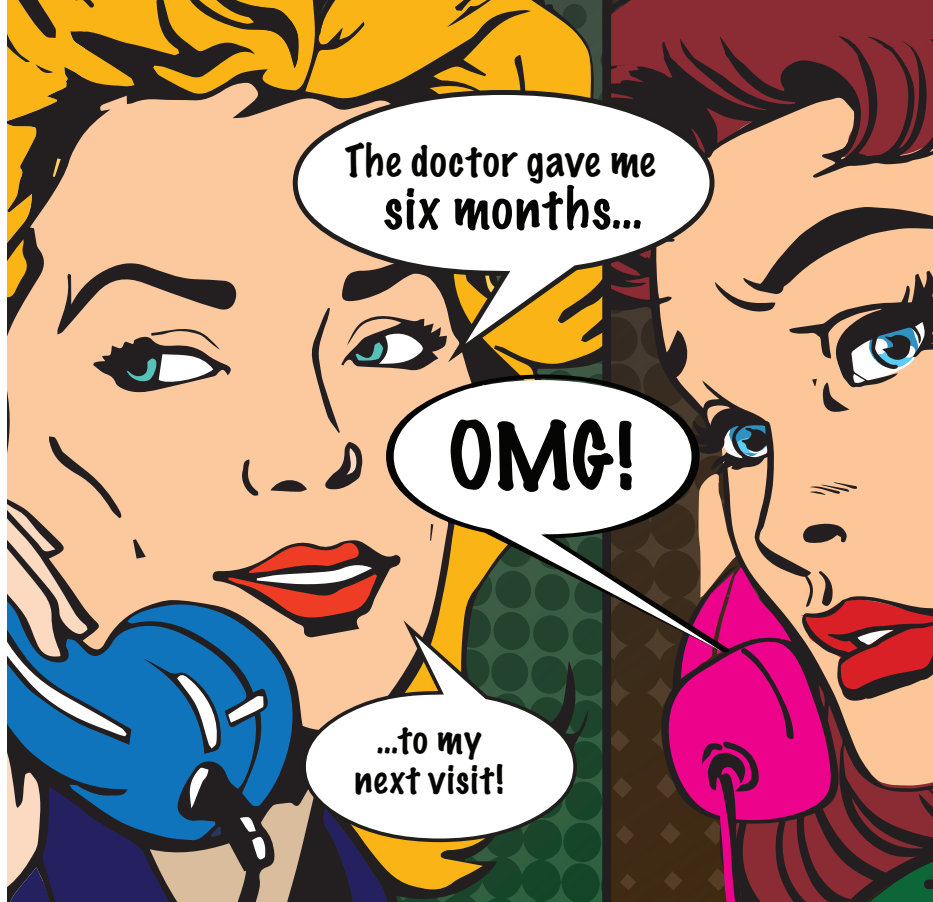measuring elevated ICP, and this study “adds further evidence for the sensitivity and specificity of ultrasonography for this purpose,” according to an editor’s note from Andrew G. Lee, MD, of Houston Methodist Eye Associates in Houston, Texas.

Dr. Lee already uses the diagnostic tool in his practice to: differentiate difficult cases of pseudopapilledema vs. papilledema, follow patients with papilledema with residual post-treatment disc changes, evaluate those whose papilledema may no longer manifest ophthalmoscopically and patients with cerebrospinal fluid shunts and follow patients who refuse or cannot undergo a standard LP for measuring ICP.²

Because of the strong correlation between ONSD and ICP values, and because the ICP decreased as the dilated ONSDs decreased, the researchers believe “ultrasonographic ONSD measurements may be a useful, noninvasive tool for dynamically evaluating ICP.”²

“It is exciting to see that other measurements, such as ultrasound assessments of optic nerve sheath diameter, potentially offer easier, less invasive ways to gain an understanding of a patient’s ICP,” says Dr. Lighthizer. “Certainly, future research will only help to clarify this even more.”

1. Wang L, Chen L, Chen Y, et al. Ultrasonography assessments of optic nerve sheath diameter as a noninvasive and dynamic method of detecting changes in intracranial pressure. *JAMA Ophthalmol.* 2018;136(3):250-256.
2. Lee AG. Correlation between noninvasive ultrasonography and dynamically monitored intracranial pressure. *JAMA Ophthalmol.* 2018;136(3):256.

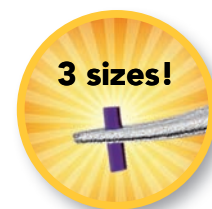

Six Full Months* of Effective Dry Eye Relief

The Extend 180™ Long-Term Dissolvable Implant

Featuring

- Simple insertion technique
- No foreign body sensation
- Exceptionally reliable retention



Indications

- Post-ocular surgery or seasonal dry eye
- Contact lens intolerance
- Dry eye associated with digital eye strain

1-866-906-8080
bvimedical.com



* 510(k) Summary K162361

BVI, BVI Logo and all other trademarks (unless noted otherwise) are property of Beaver-Visitec International (“BVI”) © 2018 BVI

Stem Cells Reverse AMD Effects

Clinicians in the United Kingdom recently reported positive outcomes after treating two patients with severe age-related macular degeneration (AMD) by implanting an engineered retinal pigment epithelium (RPE) patch made of a fully differentiated, human embryonic stem cell (hESC)-derived RPE monolayer on a coated, synthetic basement membrane.¹

“Until now, stem cell research for retinal disorders has primarily involved the implantation of a suspension of retinal pigment epithelium cells,” says Richard Trevino, OD, director of Residency Programs at the Rosenberg School of Optometry, University of the Incarnate Word. “The use of a patch is believed to improve the viability of the implanted cells, and the results of this study

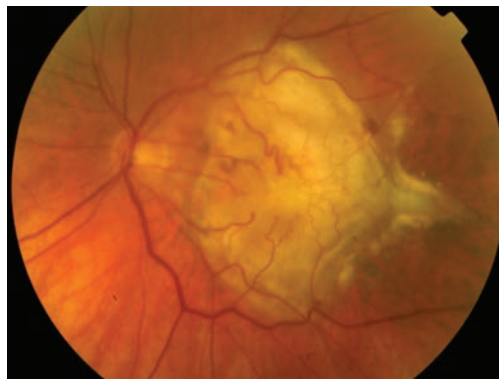

Photo: Richard Trevino, OD

Research shows an implanted stem cell patch may provide visual improvement for patients with severe AMD.

seems to support that notion.”

The researchers documented the survival of the implant with biomicroscopy and optical coherence tomography, and noted the patients gained significant visual acuity over 12 months of follow up.¹

“The researchers have regulatory approval to perform this

surgery on 10 patients, but they have chosen to report on the 12-month follow-up of their first two cases because the results have been so favorable,” says Dr. Trevino. “Both subjects experienced a dramatic improvement in vision (five to six lines on the ETDRS chart) following the procedure despite neither patient receiving anti-VEGF treatment.”

The Phase 1 trial was designed to first investigate the safety of the treatment, and results showed no tumors

caused by residual undifferentiated embryonic stem cells spreading from the patch. Serious complications following the procedure were rare, the most serious being a retinal detachment associated with proliferative vitreoretinopathy (PVR), according to Dr. Trevino. “The researchers admit that the implanted RPE cells may have contributed to the development of PVR. Only by performing the procedure on more patients will the true risk be assessed.”

The researchers have a long way to go before proving the patch’s full safety and efficacy, however. For one, “there is no control group, so it is unclear how the vision recovery experienced following this intervention compares to the vision recovery that would occur following standard therapy for this disorder (anti-VEGF therapy),” Dr. Trevino adds. “But the prospect of having another treatment for this disorder that has the potential to improve vision is very exciting.”

OCT Reveals Ocular Changes in Astronauts

Researchers recently found that astronauts have disc edema-like changes in eye structure after returning to Earth from the International Space Station (ISS).

The study looked at morphological changes in the optic nerve head and surrounding tissues in 15 astronauts after they completed a roughly six-month mission aboard the ISS. The results were compared with 43 healthy control patients with no history of exposure to microgravity in space. After analyzing optical coherence tomography (OCT) data for the astronauts collected before and after the mission, the researchers found three major changes in eye structure.

Before the flight, the astronauts presented with recessed Bruch’s membrane openings compared with the healthy controls. After the mission, their membrane openings were deepened. Additionally, the astronauts showed a noteworthy increase of total retinal thickness near the optic nerve head rim margin, and the total number of eyes with choroidal folds increased.

While determining an exact cause of these changes was not within the study’s scope, the results do point to long-term exposure to microgravity and space travel as a possibility. Beyond that, the researchers believe the algorithms and methods used to determine structural changes could be helpful in both future space travel studies and those here on Earth.

Patel N, Pass A, Mason S, et al. Optical coherence tomography analysis of the optic nerve head and surrounding structures in long-duration international space station astronauts. *JAMA Ophthalmol*. 2018;136(2):193-200.

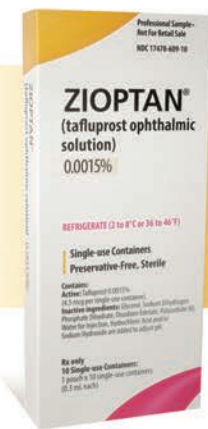1. da Cruz L, Fynes K, Georgiadis O, et al. Phase 1 clinical study of an embryonic stem cell-derived retinal pigment epithelium patch in age-related macular degeneration. *Nature Biotechnology*. March 19, 2018. [Epub ahead of print].



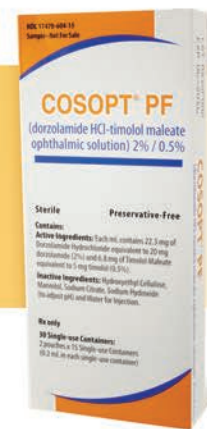100% PRESERVATIVE-FREE

ZIOPTAN[®]
(tafluprost ophthalmic solution) 0.0015%

Cosopt[®] PF
(dorzolamide HCl - timolol maleate ophthalmic solution) 2% / 0.5%



ORDER FREE SAMPLES



Go to either website
and select "Request Sample"

www.Zioptan.com

www.CosoptPF.com

Cosopt is a registered trademark of Merck Sharp & Dohme Corp and is used under license. ZIOPTAN is a registered trademark of Merck Sharp & Dohme Corp and is used under license.

Santen ZIOPTAN is licensed by Santen Pharmaceutical Co., Ltd.



Scientists Discover a New ‘Organ,’ Label it “the Interstitium”

Using probe-based confocal laser endomicroscopy (pCLE), researchers can now view living tissue at the microscopic level—leading to the recent discovery of fluid-filled spaces in the body’s connective tissue. In a recently published report, investigators are calling the interconnected, fluid-filled spaces supported by a lattice of thick collagen “bundles” a new ‘organ,’ although further research and a consensus is necessary before the label can become official.¹

Previous research used standard microscopic slides to explore this tissue layer, which, when viewed on the slides, appeared to be “densely-packed barrier-like walls of collagen.”² pCLE reveals a failing of this traditional scientific method, as the preparation process collapsed the fluid-filled

spaces and hid them from examination for decades, the researchers said in the report. By viewing the live tissue, Neil Theise, MD, a professor of pathology at New York University Langone School of Medicine, and colleagues found not a dense structure, but an “open, fluid-filled highway,” that transports “interstitial” fluid, including lymph and drains into the lymphatic system.¹

Because the purported new ‘organ’ is in connective tissues all over the body, the researchers hypothesize several functions—and possible dysfunctions. For one, they note the interstitium may act as a “shock absorber” for other organs subject to “cycles of compression and distension.”² And because it seems integral to lymph movement throughout the body, it may also be “a potential conduit

for movement of injurious agents, pro-fibrogenic signaling molecules, and tumor cells,” according to the study. “This raises the possibility that direct sampling of the interstitial fluid could be a diagnostic tool.”

This finding, while potentially ground-breaking, raises more questions than it answers. However, it “allows us ask all kinds of questions we didn’t even know to ask beforehand,” said Michael Nathanson, MD, chief of the digestive diseases section at Yale University School of Medicine, who was not involved in the work but observed the network of dark fibers in a 2011 study of his own.¹

1. Rettner R. Meet your interstitium, a newfound ‘organ.’ Live Science. www.livescience.com/62128-interstitium-organ.html?utm_source=notification. March 27, 2018. Accessed March 29, 2018.

2. Benias PC, Wells RG, Sackey-Aboagye B, et al. Structure and distribution of an unrecognized interstitium in human tissues. *Scientific Reports* 2018;8:4947.

Rare Corneal Dystrophy Gene ID’ed

Genome sequencing has lead researchers to identify the root cause of posterior polymorphous corneal dystrophy (PPCD), a rare autosomal-dominant form of corneal dystrophy that affects the corneal endothelium, according to a new study published in the March edition of the *American Journal of Human Genetics*.¹ Investigators from University College London’s Institute of Ophthalmology and Moorfields Eye Hospital London have nailed down the precise variation to the DNA—located on a gene called

GRHL2—that leads to dysfunction in the endothelial barrier and, ultimately, PPCD.¹

Using data from a large family of Czech origin, the researchers mapped a locus for an autosomal-dominant corneal endothelial dystrophy. The whole-genome sequencing identified a unique variant that causes the gene to be expressed inappropriately in corneal endothelial cells.

“We are delighted that the results from this study led to the discovery of a new genetic cause of PPCD. This will be the founda-

tion for further studies to understand even more about the biological processes leading to corneal dystrophies and to developing new treatments,” Neil Meemaduma, a research manager with Fight for Sight—which assisted in funding the research—said in a statement on the organization’s website.² ■

1. Liskova P, Dudakova L, Evans C, et al. Ectopic GRHL2 Expression Due to Non-coding Mutations Promotes Cell State Transition and Causes Posterior Polymorphous Corneal Dystrophy 4. *AJHG*. 2018;102(3):447–59.

2. Ormoniyi Y. Researchers discover a new genetic cause of corneal dystrophy. Fight for Sight: The Eye Research Charity. www.fightforsight.org.uk/news-and-views/articles/news/researchers-discover-a-new-genetic-cause-of-corneal-dystrophy/. Accessed March 29, 2018.



BEAR IN MIND THE FORMULATION OF **LOTEMAX® GEL**

- **ENGINEERED TO ADHERE TO THE OCULAR SURFACE^{1,2}**
 - Adaptive viscosity: Gel at rest, viscous liquid on the eye
 - Drug-related blurred vision was rarely reported (0.25%, 2/813)
- **~70% LESS PRESERVATIVE than LOTEMAX® SUSPENSION (loteprednol etabonate ophthalmic suspension) 0.5%^{2,3,5}**
- **DOSE UNIFORMITY—EVERY DROP, EVERY TIME**
 - No shaking required to resuspend drug^{2,4}
- **pH OF 6.5 CLOSE TO THAT OF HUMAN TEARS²**
- **CONTAINS 2 KNOWN MOISTURIZERS³**
 - Glycerin and propylene glycol

~80% unrestricted managed care access on commercial plans*

Indication

LOTEMAX® GEL (loteprednol etabonate ophthalmic gel) 0.5% is indicated for the treatment of post-operative inflammation and pain following ocular surgery.

Important Safety Information about LOTEMAX® GEL

- LOTEMAX® GEL is contraindicated in most viral diseases of the cornea and conjunctiva including epithelial herpes simplex keratitis (dendritic keratitis), vaccinia, and varicella, and also in mycobacterial infection of the eye and fungal diseases of ocular structures.
- Prolonged use of corticosteroids may result in glaucoma with damage to the optic nerve, defects in visual acuity and fields of vision. If this product is used for 10 days or longer, IOP should be monitored.
- Use of corticosteroids may result in posterior subcapsular cataract formation.
- Use of steroids after cataract surgery may delay healing and increase the incidence of bleb formation and occurrence of perforations in those with diseases causing corneal and scleral thinning. The initial prescription and renewal of the medication order should be made by a physician only after examination of the patient with the aid of magnification, and where appropriate, fluorescein staining.
- Prolonged use of corticosteroids may suppress the host response and thus increase the hazard of secondary ocular infection. In acute purulent conditions, steroids may mask infection or enhance existing infection.
- Use of a corticosteroid medication in the treatment of patients with a history of herpes simplex requires great caution. Use of ocular steroids may prolong the course and exacerbate the severity of many viral infections of the eye (including herpes simplex).
- Fungal infections of the cornea are particularly prone to develop coincidentally with long-term local steroid application. Fungus invasion must be considered in any persistent corneal ulceration where a steroid has been used or is in use.
- Patients should not wear contact lenses when using LOTEMAX® GEL.
- The most common ocular adverse drug reactions reported were anterior chamber inflammation (5%), eye pain (2%) and foreign body sensation (2%).

Please see brief summary of Prescribing Information on adjacent page.

References: 1. Rajpal RK, Fong R, Comstock TL. Loteprednol etabonate ophthalmic gel 0.5% following cataract surgery: integrated analysis of two clinical studies. *Adv Ther*. 2013;30:907-923. 2. Coffey MJ, Decory HH, Lane SS. Development of non-settling gel formulation of 0.5% loteprednol etabonate for anti-inflammatory use as an ophthalmic drop. *Clin Ophthalmol*. 2013;7:299-312. 3. LOTEMAX GEL [package insert]. Tampa, FL: Bausch & Lomb Incorporated. 4. Apt L, Henrick A, Silverman LM. Patient compliance with use of topical ophthalmic corticosteroid suspensions. *Am J Ophthalmol*. 1979;87(2):210-214. 5. LOTEMAX SUSPENSION [package insert]. Tampa, FL: Bausch & Lomb Incorporated.

* Fingertip Formulary data 2017



LOTEMAX® GEL

loteprednol etabonate
ophthalmic gel 0.5%

BAUSCH + LOMB

LOTEMAX is a trademark of Bausch & Lomb Incorporated or its affiliates.
©Bausch & Lomb Incorporated. All rights reserved. Printed in USA. LGX.0101.USA.17

Visit www.LOTEMAXGEL.com

BRIEF SUMMARY OF PRESCRIBING INFORMATION

This Brief Summary does not include all the information needed to prescribe Lotemax Gel safely and effectively. See full prescribing information for Lotemax Gel.

Lotemax (loteprednol etabonate ophthalmic gel) 0.5%

Rx only

Initial Rx Approval: 1998

INDICATIONS AND USAGE

LOTEMAX is a corticosteroid indicated for the treatment of post-operative inflammation and pain following ocular surgery.

DOSAGE AND ADMINISTRATION

Invert closed bottle and shake once to fill tip before instilling drops.

Apply one to two drops of LOTEMAX into the conjunctival sac of the affected eye four times daily beginning the day after surgery and continuing throughout the first 2 weeks of the post-operative period.

CONTRAINDICATIONS

LOTEMAX, as with other ophthalmic corticosteroids, is contraindicated in most viral diseases of the cornea and conjunctiva including epithelial herpes simplex keratitis (dendritic keratitis), vaccinia, and varicella, and also in mycobacterial infection of the eye and fungal diseases of ocular structures.

WARNINGS AND PRECAUTIONS

Intraocular Pressure (IOP) Increase

Prolonged use of corticosteroids may result in glaucoma with damage to the optic nerve, defects in visual acuity and fields of vision. Steroids should be used with caution in the presence of glaucoma. If this product is used for 10 days or longer, intraocular pressure should be monitored.

Cataracts

Use of corticosteroids may result in posterior subcapsular cataract formation.

Delayed Healing

The use of steroids after cataract surgery may delay healing and increase the incidence of bleb formation. In those diseases causing thinning of the cornea or sclera, perforations have been known to occur with the use of topical steroids. The initial prescription and renewal of the medication order should be made by a physician only after examination of the patient with the aid of magnification such as slit lamp biomicroscopy and, where appropriate, fluorescein staining.

Bacterial Infections

Prolonged use of corticosteroids may suppress the host response and thus increase the hazard of secondary ocular infections. In acute purulent conditions of the eye, steroids may mask infection or enhance existing infection.

Viral Infections

Employment of a corticosteroid medication in the treatment of patients with a history of herpes simplex requires great caution. Use of ocular steroids may prolong the course and may exacerbate the severity of many viral infections of the eye (including herpes simplex).

Fungal Infections

Fungal infections of the cornea are particularly prone to develop coincidentally with long-term local steroid application. Fungus invasion must be considered in any persistent corneal ulceration where a steroid has been used or is in use. Fungal cultures should be taken when appropriate.

Contact Lens Wear

Patients should not wear contact lenses during their course of therapy with LOTEMAX.

ADVERSE REACTIONS

Adverse reactions associated with ophthalmic steroids include elevated intraocular pressure, which may be associated with infrequent optic nerve damage, visual acuity and field defects, posterior subcapsular cataract formation, delayed wound healing and secondary ocular infection from pathogens including herpes simplex, and perforation of the globe where there is thinning of the cornea or sclera.

The most common adverse drug reactions reported were anterior chamber inflammation (5%), eye pain (2%), and foreign body sensation (2%).

USE IN SPECIFIC POPULATIONS

Pregnancy

Teratogenic Effects

Loteprednol etabonate has been shown to be embryotoxic (delayed

ossification) and teratogenic (increased incidence of meningocele, abnormal left common carotid artery, and limb flexures) when administered orally to rabbits during organogenesis at a dose of 3 mg/kg/day (35 times the maximum daily clinical dose), a dose which caused no maternal toxicity. The no-observed-effect-level (NOEL) for these effects was 0.5 mg/kg/day (6 times the maximum daily clinical dose). Oral treatment of rats during organogenesis resulted in teratogenicity (absent innominate artery at ≥ 5 mg/kg/day doses, and cleft palate and umbilical hernia at ≥ 50 mg/kg/day) and embryotoxicity (increased post-implantation losses at 100 mg/kg/day and decreased fetal body weight and skeletal ossification with ≥ 50 mg/kg/day). Treatment of rats with 0.5 mg/kg/day (6 times the maximum clinical dose) during organogenesis did not result in any reproductive toxicity. Loteprednol etabonate was maternally toxic (significantly reduced body weight gain during treatment) when administered to pregnant rats during organogenesis at doses of ≥ 5 mg/kg/day.

Oral exposure of female rats to 50 mg/kg/day of loteprednol etabonate from the start of the fetal period through the end of lactation, a maternally toxic treatment regimen (significantly decreased body weight gain), gave rise to decreased growth and survival, and retarded development in the offspring during lactation; the NOEL for these effects was 5 mg/kg/day. Loteprednol etabonate had no effect on the duration of gestation or parturition when administered orally to pregnant rats at doses up to 50 mg/kg/day during the fetal period.

There are no adequate and well controlled studies in pregnant women. LOTEMAX should be used during pregnancy only if the potential benefit justifies the potential risk to the fetus.

Nursing Mothers

It is not known whether topical ophthalmic administration of corticosteroids could result in sufficient systemic absorption to produce detectable quantities in human milk. Systemic steroids appear in human milk and could suppress growth, interfere with endogenous corticosteroid production, or cause other untoward effects. Caution should be exercised when LOTEMAX is administered to a nursing woman.

Pediatric Use

Safety and effectiveness in pediatric patients have not been established.

Geriatric Use

No overall differences in safety and effectiveness have been observed between elderly and younger patients.

NONCLINICAL TOXICOLOGY

Carcinogenesis, Mutagenesis, Impairment Of Fertility

Long-term animal studies have not been conducted to evaluate the carcinogenic potential of loteprednol etabonate. Loteprednol etabonate was not genotoxic *in vitro* in the Ames test, the mouse lymphoma tk assay, or in a chromosome aberration test in human lymphocytes, or *in vivo* in the single dose mouse micronucleus assay. Treatment of male and female rats with up to 50 mg/kg/day and 25 mg/kg/day of loteprednol etabonate, respectively, (600 and 300 times the maximum clinical dose, respectively) prior to and during mating did not impair fertility in either gender.

PATIENT COUNSELING INFORMATION

Administration

Invert closed bottle and shake once to fill tip before instilling drops.

Risk of Contamination

Patients should be advised not to allow the dropper tip to touch any surface, as this may contaminate the gel.

Contact Lens Wear

Patients should be advised not to wear contact lenses when using LOTEMAX.

Risk of Secondary Infection

If pain develops, redness, itching or inflammation becomes aggravated, the patient should be advised to consult a physician.

Bausch + Lomb, a division of Valeant Pharmaceuticals North America LLC
Bridgewater, NJ 08807 USA

US Patent No. 5,800,807

©Bausch & Lomb Incorporated

Lotemax is a registered trademark of Bausch & Lomb Incorporated or its affiliates.

LGX.0114.USA.16

Based on 9269101/9269201

Revised: 08/2016

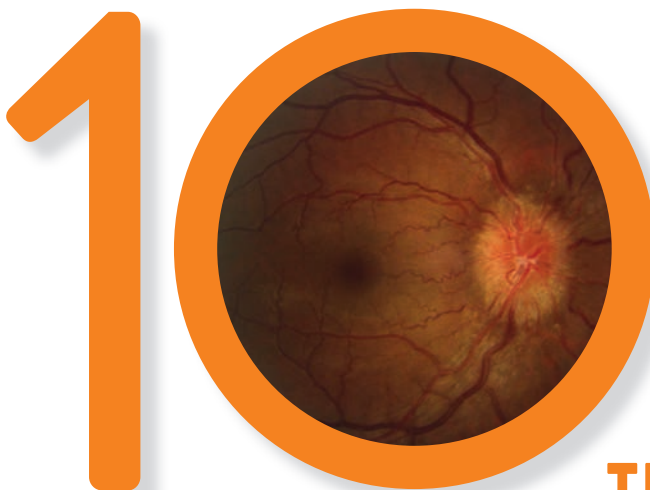
Contents

Review of Optometry April 15, 2018

11th Annual Pharmaceuticals Report

KNOW YOUR SYSTEMIC MEDS:

THE
TOP



TO
TRACK

Here's what you need to know about the ocular effects of the heavy-hitters.

BY MEGAN HUNTER, OD, AND MICHELLE MARCINIAK, OD

PAGE 44

One Size Won't Fit All: Treating Ocular Infection

Knowing which antibiotic to choose and how to use it are critical when treating and beating ocular infection.

BY TRACY OFFERDAHL-MCGOWAN, PharmD, AND GREG CALDWELL, OD

PAGE 52

Sizing Up Anti-inflammatories in Dry Eye Disease

A practical guide for optometrists applying these medications.

BY VIN DANG, OD

PAGE 62



Protocols and Pitfalls in Topical Steroid Use

It's always a balancing act between benefit and side effects. Here's how to keep patients safe while treating with steroids.

BY AARON BRONNER, OD, AND WALTER O. WHITLEY, OD, MBA

PAGE 66

74

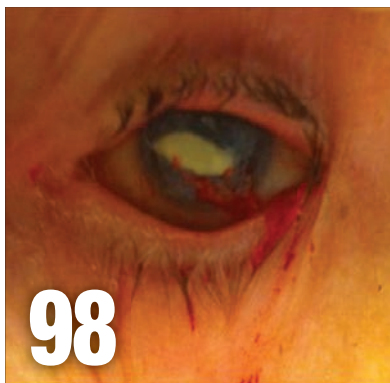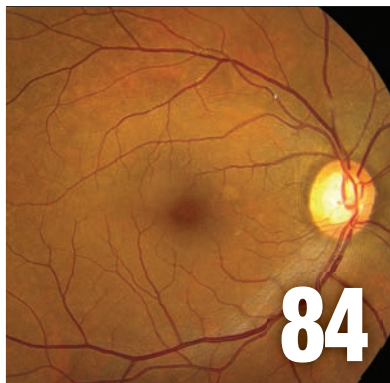
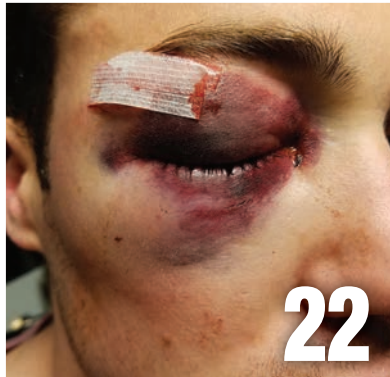Proceed With Caution: Low Vision and Driving

Here's how you can navigate the complex interplay between DMV standards and the needs of your patients who are visually impaired. **By Mark E. Wilkinson, OD, and Khadija S. Shahid, OD, MPH**

Departments

Review of Optometry April 15, 2018

- 3 News Review**
- 14 Letters to the Editor**
- 18 Through My Eyes**
Just Say Yes to (Some) Drugs
PAUL M. KARPECKI, OD
- 20 Chairside**
The Extinction of the Ink Pen
MONTGOMERY VICKERS, OD
- 22 Clinical Quandaries**
Taking the Floor on Fractures
PAUL C. AJAMIAN, OD
- 24 Outlook**
A Significant Proposal
JACK PERSICO
- 26 Coding Connection**
No Sneaking Around this Code
JOHN RUMPAKIS, OD, MBA
- 28 Focus on Refraction**
Fresnel Prism to the Rescue
MARC B. TAUB, OD, MS, AND PAUL HARRIS, OD
- 32 Retina Dilemmas**
Hold 'em or Fold 'em?
DIANA SHECHTMAN, OD, AND JAY M. HAYNIE, OD
- 83 Cornea + Contact Lens Q&A**
Trouble with Thygeson's
JOSEPH P. SHOVLIN, OD
- 84 Retina Quiz**
Something in the Way
MARK T. DUNBAR, OD
- 86 Therapeutic Review**
Take Your Lumps
JOSEPH W. SOWKA, OD, AND ALAN G. KABAT, OD
- 89 Glaucoma Grand Rounds**
The Devil is in the Details
JAMES L. FANELLI, OD
- 91 Advertisers Index**
- 93 Surgical Minute**
The MIGS Just Keep on Coming
CHRISTOPHER KRUTHOFF, OD, WALTER O. WHITLEY, OD, MBA, AND DEREK N. CUNNINGHAM, OD
- 94 Classifieds**
- 97 Meetings & Conferences**
- 98 Diagnostic Quiz**
There Will Be Blood
ANDREW S. GURWOOD, OD



REVIEW[®] OF OPTOMETRY

BUSINESS OFFICES

11 CAMPUS BLVD., SUITE 100
NEWTOWN SQUARE, PA 19073

CEO, INFORMATION SERVICES GROUP

MARC FERRARA
(212) 274-7062 • MFERRARA@JOBSON.COM

PUBLISHER

JAMES HENNE
(610) 492-1017 • JHENNE@JOBSON.COM

REGIONAL SALES MANAGER

MICHELE BARRETT
(610) 492-1014 • MBARRETT@JOBSON.COM

REGIONAL SALES MANAGER

MICHAEL HOSTER
(610) 492-1028 • MHOSTER@JOBSON.COM

VICE PRESIDENT, OPERATIONS

CASEY FOSTER
(610) 492-1007 • CFOSTER@JOBSON.COM

VICE PRESIDENT, CLINICAL CONTENT

PAUL M. KARPECKI, OD, FFAO
PKARPECKI@JOBSON.COM

PRODUCTION MANAGER

SCOTT TOBIN
(610) 492-1011 • STOBIN@JOBSON.COM

SENIOR CIRCULATION MANAGER

HAMILTON MAHER
(212) 219-7870 • HMAHER@JHIHEALTH.COM

CLASSIFIED ADVERTISING

(888) 498-1460

SUBSCRIPTIONS

\$56 A YEAR, \$88 (US) IN CANADA,
\$209 (US) IN ALL OTHER COUNTRIES.

SUBSCRIPTION INQUIRIES

(877) 529-1746 (US ONLY)
OUTSIDE US CALL: (845) 267-3065

CIRCULATION

PO Box 81
CONGERS, NY 10920
TEL: (TOLL FREE): (877) 529-1746
OUTSIDE US: (845) 267-3065



CEO, INFORMATION SERVICES GROUP
MARC FERRARA

SENIOR VICE PRESIDENT, OPERATIONS
JEFF LEVITZ

VICE PRESIDENT, HUMAN RESOURCES
TAMMY GARCIA

VICE PRESIDENT, CREATIVE SERVICES & PRODUCTION
MONICA TETTAMANZI

CORPORATE PRODUCTION DIRECTOR
JOHN ANTHONY CAGGIANO

VICE PRESIDENT, CIRCULATION
EMELDA BAREA

CONTRIBUTING EDITORS

PAUL C. AJAMIAN, OD, ATLANTA
AARON BRONNER, OD, KENNEWICK, WASH.
MILE BRUJIC, OD, BOWLING GREEN, OHIO
DEREK N. CUNNINGHAM, OD, AUSTIN, TEXAS
MARK T. DUNBAR, OD, MIAMI
ARTHUR B. EPSTEIN, OD, PHOENIX
JAMES L. FANELLI, OD, WILMINGTON, NC
FRANK FONTANA, OD, ST. LOUIS
GARY S. GERBER, OD, HAWTHORNE, NJ
ANDREW S. GURWOOD, OD, PHILADELPHIA
ALAN G. KABAT, OD, MEMPHIS, TENN.
DAVID KADING, OD, SEATTLE
PAUL M. KARPECKI, OD, LEXINGTON, KY.
JEROME A. LEGERTON, OD, MBA, SAN DIEGO
JASON R. MILLER, OD, MBA, POWELL, OHIO
CHERYL G. MURPHY, OD, BABYLON, NY
CARLO J. PELINO, OD, JENKINTOWN, PA.
JOSEPH PIZZIMENTI, OD, SAN ANTONIO, TEXAS
JOHN RUMPAKIS, OD, MBA, PORTLAND, ORE.
DIANA L. SHECHTMAN, OD, FORT LAUDERDALE, FLA.
JEROME SHERMAN, OD, NEW YORK
JOSEPH P. SHOVLIN, OD, SCRANTON, PA.
JOSEPH W. SOWKA, OD, FORT LAUDERDALE, FLA.
MONTGOMERY VICKERS, OD, LEWISVILLE, TEXAS
WALTER O. WHITLEY, OD, MBA, VIRGINIA BEACH, VA.

EDITORIAL REVIEW BOARD





JEFFREY R. ANSHEL, OD, ENCINITAS, CALIF.
JILL AUTRY, OD, RPH, HOUSTON
SHERRY J. BASS, OD, NEW YORK
EDWARD S. BENNETT, OD, ST. LOUIS
MARC R. BLOOMENSTEIN, OD, SCOTTSDALE, ARIZ.
CHRIS J. CAKANAC, OD, MURRYSVILLE, PA.
JERRY CAVALLERANO, OD, PHD, BOSTON
WALTER L. CHOATE, OD, MADISON, TENN.
BRIAN CHOU, OD, SAN DIEGO

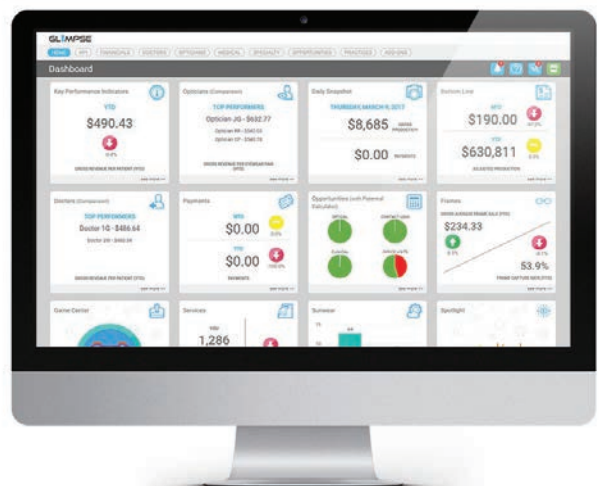A. PAUL CHOUS, MA, OD, TACOMA, WASH.
ROBERT M. COLE, III, OD, BRIDGETON, NJ
GLENN S. CORBIN, OD, WYOMISSING, PA.
ANTHONY S. DIECIDUE, OD, STROUDSBURG, PA.
S. BARRY EIDEN, OD, DEERFIELD, ILL.
STEVEN FERRUCCI, OD, SEPULVEDA, CALIF.
MURRAY FINGERET, OD, HEWLETT, NY
IAN BEN GADDIE, OD, LOUISVILLE, KY.
PAUL HARRIS, OD, MEMPHIS, TN
MILTON HOM, OD, AZUSA, CALIF.
BLAIR B. LONSBERRY, MS, OD, MED, PORTLAND, ORE.
THOMAS L. LEWIS, OD, PHD, PHILADELPHIA
DOMINICK MAINO, OD, MED, CHICAGO
KELLY A. MALLOY, OD, PHILADELPHIA
RICHARD B. MANGAN, OD, LEXINGTON, KY.
RON MELTON, OD, CHARLOTTE, NC
PAMELA J. MILLER, OD, JD, HIGHLAND, CALIF.
BRUCE MUCHNICK, OD, COATESVILLE, PA.
MARC MYERS, OD, COATESVILLE, PA.
WILLIAM B. POTTER, OD, FREEHOLD, NJ
CHRISTOPHER J. QUINN, OD, ISELIN, NJ
MICHAEL C. RADOIU, OD, STAUNTON, VA.
MOHAMMAD RAFIEETARY, OD, MEMPHIS, TN
JOHN L. SCHACHET, OD, ENGLEWOOD, COLO.
JACK SCHAEFFER, OD, BIRMINGHAM, ALA.
LEO P. SEMES, OD, BIRMINGHAM, ALA.
LEONID SKORIN, JR., OD, DO, ROCHESTER, MINN.
JOSEPH W. SOWKA, OD, FORT LAUDERDALE, FLA.
SRUTHI SRINIVASAN, PHD, BS OPTOM, WATERLOO, ONT.
BRAD M. SUTTON, OD, INDIANAPOLIS
LORETTA B. SZCZOTKA, OD, PHD, CLEVELAND
MARC TAUB, OD, MEMPHIS, TN
TAMMY P. THAN, MS, OD, BIRMINGHAM, ALA.
RANDALL THOMAS, OD, CONCORD, NC
SARA WEIDMAYER, OD, ANN ARBOR, MI
KATHY C. WILLIAMS, OD, SEATTLE
KAREN YEUNG, OD, LOS ANGELES



Unlocking the Future of Healthcare Analytics

ARE YOU KEEPING UP WITH THE COMPETITION?

-  Quickly identify missed revenue opportunities
-  Create your own metric dashboard
-  Complete accuracy customized to your billing habits
-  Have fun and engage your team with Gamification



The February 2018 cover story, “How the Diploma Deluge is Reshaping Optometry,” presented comments from educators and data from the Association of Schools and Colleges in Optometry (ASCO) to look at the impact of optometry’s expanded educational footprint. The feature generated criticism, praise and suggestions, some of which is addressed in the following letters and our reply.

Behind the Drive

Kudos for your well researched and appreciated article. I believe one cannot have a “deluge” of graduates without producing a surplus of optometrists, and that this surplus was self-induced and is counterproductive to patient care. This surplus was first predicted in a 1995 Rand study and again by an Abt. Associates study in 2000.^{1,2} But both underestimated future surpluses because graduates have since increased about 40%.

In 2011, the Lewin Group—with AOA-appointed advisors—was commissioned to survey how optometrists practiced and to estimate the future supply of, and demand for, eye care. Its 2012 survey found a 32% optometry surplus and its supply/demand model in 2014 predicted greater future optometry surpluses but increasing ophthalmology shortages.³ However, Lewin’s findings stated, “There would be an adequate supply of eye care providers in the future,” which was egregiously misleading. Lewin buried the optometry surplus within the surplus of “eye care providers” and characterized it as “an adequate supply of eye care providers.”

In 2014, Lewin next developed optometry and ophthalmology supply/demand projections and found

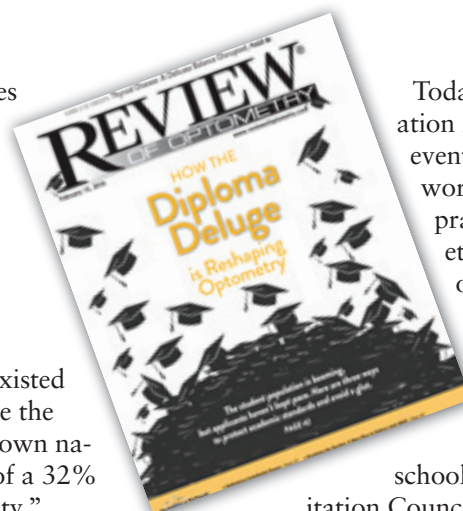
future surpluses of optometrists and shortages of ophthalmologists. These initial projections assumed no surplus of optometrists existed in 2012 despite the findings of its own national survey of a 32% “excess capacity.”

The group then constructed a complex model that did include the 2012 optometry “excess capacity,” but increased future eye care demands due to the Affordable Care Act, the growing diabetes rate and child health insurance plans. In this “unified eye care market,” optometrists and ophthalmologists were assumed interchangeable. The final model’s assumptions claimed:

1. No increase in future ophthalmologists or their productivity.
2. Optometry “excess capacities” will “fill” shortages of ophthalmologists.
3. Optometrists and ophthalmologists have identical scopes of care and considered interchangeable generic “eye care providers.”
4. A rate of 1.36 optometrists provide the care equivalent of one ophthalmologist.

These were, of course, implausible assumptions.

The chief impetus for the “diploma deluge” were Bureau of Labor Statistics reports claiming high demand for optometrists that led the media to report optometry was “hot.” But the primary source for those forecasts were rosy projections supplied by the AOA leadership and bitterly resisted, over the years, by some staff officers.



Today’s annual graduation rate of 1,900 will eventually produce a workforce of 76,000 practicing optometrists, a density of optometrists per 1,000 nearly twice today’s.

It has been too easy, for too long, for

schools to meet Accred-

itation Council on Optometric Education (ACOE) accreditation standards, which are far less robust than medical and dental schools due to a lack of quantitative standards for required student contacts by types/numbers during training.

—Kenneth J. Myers, PhD, OD
President, American Board of Certification in Medical Optometry

1. Lee P, Jackson C, Rolles D. RAND, Estimating eye care provider supply and workforce requirements. www.rand.org/pubs/monograph_reports/MR516.html. 1995.

2. White A, White C, Doksum T. Workforce study of optometrists. St. Louis, MO: Abt Associates Inc. American Optometric Association. 2000.

3. American Optometric Association/Lewin Group. Eye Care Workforce Study: Supply and Demand Projections. Executive Summary. April 25, 2014.

The Whole Truth

Your recent article identifies a subject worthy of discussion by the profession in looking to plan for the future. Unfortunately, the article appears to be something written more for a deadline than for a serious consideration of all the aspects. The effect of mandatory board passage for graduation and its effect on graduation rate was not even mentioned, nor was the recalibration of the Optometric Admission Test (OAT) during the years across which the author compares scores. While footnotes are used to imply some vigorous research, all the data is not given. For classes that matriculated in

2017, the University of the Incarnate Word Rosenberg School of Optometry had an entering class GPA that was higher than four of the six oldest institutions listed.

The entire article must be viewed with suspicion as it shows the Arizona College of Optometry to have been established in 2017 and yet provides its pass rates on licensing examinations. Once you realize the magnitude of that error you begin to question everything else the article asserts.

—Timothy A. Wingert, OD
Dean, University of the
Incarnate Word

Rosenberg School of Optometry

Keeping Us Honest

We thank the above readers and others who reached out to comment on the article. Several readers pointed out that Midwestern University's Arizona College of Optometry's first class was in 2009, not 2017. We regret the error. The online version has been corrected.

Second, Table 3 of our article compared the OAT scores of matriculating students from 2008 with those from 2017. Some readers pointed out, correctly, that the scoring was modified in 2009. The test is graded on a scale of 200 to 400. In 2009, adjustments were made to reduce the average score—which had crept up to 320—to 300. According to Association of Schools and Colleges of Optometry President David Damari, OD, the changes included “changing the way raw scores (number of items answered correctly) were converted to the standard scores reported.” He went on to explain that, “As the test ages—so to speak—the average score goes up a little bit at a time, for various reasons, especially in reading comprehension.”

Every year, administrators review the test to determine whether it's still a predictive indicator for schools. Before the 2009 test, they decided it was not. However, the adjustment was “not really a change in the test, it's a change in how many items the student needs to get correct in order to get to 300,” Dr. Damari explains. “It's an adjustment, not a major rescaling.” There's an ebb and flow to all testing, he suggests. Once a test starts to mature, average scores go up and that's how administrators know it's time to recalibrate the test. In fact, educators are looking again to adjust the scoring. Dr. Damari notes that “2008 was just before one calibration and 2017 is probably going to end up being right before another recalibration. If anything, that's an incredibly fair comparison.”

The article also makes use of recently released statistics from the National Board of Examiners in Optometry revealing the percentage of graduates who pass the boards. However, we did not discuss a caveat to those numbers; that some schools require students to pass part one or parts one and two of the boards (nobody requires passing part three) before it allows them to graduate. Although it does impact what that ultimate board pass rate is, this really raises a philosophical question. If optometry schools exist to educate future optometrists, should they do all they can to ensure their students success—and does “doing all they can” include guaranteeing they can pass the boards?

Look at Southern College of Optometry (SCO), which started requiring the national boards in 1990, according to Lisa Wade, OD, director at SCO's Hayes

Center for Practice Excellence. It suffered from low pass rates before that and its reputation was negatively impacted. When the school started requiring board passage, that changed drastically; in fact, it influenced other schools in the South to embrace requiring board passage. A rising tide lifts all boats.

Others wonder whether requiring students to pass a test that the institution itself does not compose itself amounts to a violation of the institution's autonomy. After all, the school issues a degree, not a license.

As our story noted, the numbers don't tell all. Optometry schools' standards clearly exist on a spectrum and, although they can be measured in a variety of ways, they can never really be ranked. There will always be some incongruity or unique circumstance. Although we can quantify performance and use data to predict success, we cannot quantify human beings and, ultimately, that's what optometric education must focus on: training actual human beings from a variety of backgrounds, to become skilled, dedicated, passionate doctors.

If it's to thrive, optometric education must serve two masters, one from the idealistic world of academia and one from the sober, hard-nosed world of capitalism. And while doing that may require schools to compromise from time to time, the educational system's influence over the future of optometry is not absolute. The real future is in the hands of the students themselves, who—we hope our article demonstrated—strive to grow the profession while preserving the legacy of their predecessors.

—Bill Kekevia
Senior Editor,
Review of Optometry

Don't Hold Back

There are many good reasons to switch patients to silicone hydrogel—whether they're wearing frequent replacement or 1-day lenses.

If you ask most optometrists which lens material is their go-to for monthly and two-week fits, the answer is overwhelmingly silicone hydrogel. Due to its increased oxygen transmissibility, silicone hydrogel offers patients a healthier* lens-wearing experience. Indeed, on average, ECPs fit 91% of their monthly and two-week contact lens wearers in silicone hydrogel lenses. This is in stark contrast to how many 1-day patients they fit in silicone hydrogel—they fit only 30% of 1-day patients in silicone hydrogel.

This begs the question: Why don't doctors routinely fit 1-day wearers in the same material they prefer for frequent replacement wear? Unfortunately, the answer to this question remains a mystery, particularly in light of startling new research, which demonstrates that doctors' lens prescribing patterns lag far behind their beliefs about what's best for patients.

We spoke with three optometrists for insight on this disconnect between beliefs and behavior. In the interviews that follow, these 1-day silicone hydrogel advocates explain why they are committed to this material for 1-day fits and share advice on how to always recommend the lens you trust the most.

Is hydrogel good enough for most 1-day lens wearers?

Dr. Rosinski: I strongly believe that silicone hydrogel 1-day lenses provide better long-term eye health for my patients than hydrogel 1-day lenses. Furthermore, 91% of my colleagues agree according to recent research. We also need to consider the increasing demands of modern life. In this digital era, patients are prone to dryness, discomfort and fluctuating vision. Silicone hydrogel lenses outperform hydrogel in terms of all-day comfort and eye health. Furthermore, we know from experience with frequent replacement lenses that increased oxygen permeability leads to clinically meaningful outcomes. It has an impact on corneal edema, limbal hyperemia, neovascularization, refractive error change, epithelial thinning, and more. With all this in mind, I would say silicone hydrogel is an obvious choice for the health and comfort of 1-day lens wearers.

The Practitioners



Melanie Frogozo
OD, FAAO, FSLs
The Contact Lens Institute of San Antonio
San Antonio, Texas



Ethan E. Huisman
OD, FAAO
Elite Eye Care
West Des Moines, Iowa



Steve Rosinski
OD
Crozet Eye Care
Charlottesville, Virginia

Dr. Huisman: I have a relatively young patient population, so I'm very focused on preserving ocular surface health for 20, 30 or even 40 years or more. In my practice, making compromises isn't in the patient's long-term best interests. Also,

consider the fact that more than 75% of contact lens wearers admit to napping in their lenses and 28% admit to sleeping in their lenses at least once a month. Whether they are telling you about it or trying to hide from you, these patients need as much oxygen as they can get—no matter how frequently they replace their lenses.

Dr. Frogozo: I agree. We need to be more realistic about how our patients are wearing their lenses. The reality is that most patients don't wear their lenses for just a few hours per day. Research shows that 1-day wearers in the U.S. habitually wear their contact lenses for at least 15 hours per day, seven days per week. Before reaching for a 1-day hydrogel, ask yourself if hydrogel would be your first choice for the patient if he or she was wearing a frequent replacement lens. If the answer is no, then why would you deprive the 1-day wearer of this same opportunity?

What meaningful advantages does silicone hydrogel have in a 1-day lens?

Dr. Frogozo: I agree with 92% of ECPs who say silicone hydrogel 1-day lenses are the best choice to safeguard patients' eye health related to contact lens wear. This same study shows that 92% likewise believe that silicone hydrogel 1-day lenses provide the best benefits to their patients. In terms of my own personal beliefs and how that guides how I practice, I'm concerned that the hydrogel wearer will develop hypoxia and eventually drop out of lens wear. It's a familiar story that we've seen play out when hydrogel was the go-to lens in frequent replacement.

Dr. Huisman: Doctors want health, but patients care about comfort. Silicone hydrogel 1-day lenses offer both.



with the current lenses, I shift the conversation focus around preventative care.

Dr. Frogozo: My practice is primarily referral-based, which means patients walk in wearing many different types

of lenses. Despite this, I fit my sphere patients almost exclusively in 1-day silicone hydrogel lenses. And, as the toric parameters expand, I'm fitting more and more astigmats in 1-day silicone hydrogel as well. Patients rarely object to my recommendation. I proactively educate my patients on the need for oxygen in lens wear and advise them that silicone hydrogel is healthiest.

Dr. Rosinski: I go beyond generic, traditional questioning. You won't get much information by asking, "how are your contacts?" Patients are likely to say, "FINE," which in my view means "Feelings I've Not Expressed." The more pointed questions you ask, the more you are likely to discover something to improve upon. Upgrading to silicone hydrogel doesn't require a huge change in mindset for a current 1-day wearer. On the contrary, it's an obvious choice because 1-day patients are already health conscious. Moving to silicone hydrogel is simply a logical next step.

Does the lens trial play a significant role in convincing 1-day wearers about the benefits of silicone hydrogel?

Dr. Frogozo: In my practice, the conversation is usually more powerful

than the trial. A strong recommendation from a doctor is all most patients need to hear. If you believe silicone hydrogel is a superior material, the patient will likely believe it too. However, if you have a patient who is already wearing a 1-day lens in a hydrogel material and you want to switch to silicone hydrogel, the lens trial can be a tipping point. In these cases, I tell the patient that their current lenses are based on older technology, so I'm offering them an opportunity to trial something newer and healthier.

Dr. Huisman: I agree. Trials are great but the conversation has to precede it. I don't want patients to think I'm making a change for change's sake. Eighty-two percent of ECPs believe that silicone hydrogel should be the standard of care for 1-day contact lens patients and 87% say silicone hydrogel material should be the first choice of material for daily disposable lenses. When patients hear that from us, they're more likely to approach the lens trial with enthusiasm.

Dr. Rosinski: Trialing silicone hydrogel 1-day lenses also helps strengthen our relationships with patients. First, we make the recommendation and educate the patient on the benefits. Next, they take the lens for a test drive. Finally, when they return satisfied with the comfort and vision of their new lenses, they're more confident than ever in our knowledge and our commitment to providing the best possible care.

Silicone hydrogel 1-day lenses are great for my younger patients because they're so easy to insert and remove—plus they're extremely comfortable. My patients aren't rushing home from work so they can take out their lenses. That's a meaningful, practical advantage.

Dr. Rosinski: The number one advantage is ocular health. When the clariti 1 day family of lenses was introduced, it was a no-brainer for me to switch my 1-day patients. Silicone hydrogel creates a highly "breathable" lens that promotes whiter, brighter** eyes.

How do you get patients on board with your decision to switch to a silicone hydrogel material—especially if they seem happy with their current hydrogels?

Dr. Huisman: Patients are confident in your recommendation when you cite a specific reason for change. I educate them on the benefits and advantages of silicone hydrogel generally and for their case specifically. Quite often, my hydrogel patients have signs of neovascularization or hyperemia, so I take a photo of this and show it to the patient, explaining that this is the reason change is needed. In the event that the patient has no signs and is very happy

More Options Help You Offer What's Best, More Often

Offer your 1-day contact lens patients a healthier lens-wearing experience. CooperVision's broad range of silicone hydrogel 1-day contact lenses can provide up to four times more oxygen transmissibility than traditional hydrogel contact lenses. From the clariti® 1 day family to MyDay®, you can fit virtually all patients into a 1-day contact lens that provides high oxygen, comfort, and convenience.

For more information, visit Coopervision.com



* With higher oxygen permeability than hydrogel materials, silicone hydrogel contact lenses minimize or eliminate hypoxia-related signs and symptoms during lens wear.

** Data on file; clariti® 1 day offers whiter eyes than 1-DAY ACUVUE® MOIST®.



Just Say Yes to (Some) Drugs

Don't shy away from prescribing the right medications when your patients need them. **By Paul M. Karpecki, OD, Chief Clinical Editor**

Optometrists manage more anterior segment disease than anyone, and it's critical that we have the pharma knowledge to treat these patients appropriately. This month's annual pharmaceutical issue provides detailed advice to elevate your practice so you can give patients much-needed relieve and recovery. I'd like to preface this article series with a few thoughts from my perspective as both a clinician and an educator.

Antibiotics

Just because we haven't seen a new antibiotic in a few years doesn't mean we should get complacent in drug selection. Drug resistance, while steady, is incredibly high.¹ The most recent ARMOR study—a yearly review of over 3,000 ocular isolates in the United States—found methicillin-resistant *Staphylococcus* is resistant to 30% to 40% of antibiotics; for coagulase-negative *Staph.*, it's nearly 50%. Because we don't typically culture conjunctivitis and it takes so long to get a culture for an infectious keratitis, we have to be knowledgeable and judicious when treating empirically.¹ Most bacteria are susceptible to newer agents such as Besivance (besifloxacin, Bausch + Lomb).¹

Dry Eye Drugs

Although artificial tears continue to advance with a number of new and increasingly effective options, they still play a palliative role, with little value in addressing inflammation. Both Restasis (cyclosporine, Aller-

gan) and Xiidra (lifitegrast, Shire) have made significant contributions to treating the underlying inflammation of dry eye disease.² Xiidra may bring symptom improvement in as little as two weeks, and some studies of Restasis show improvement at one month.³

Topical Steroids

Don't fear these drugs. For superficial punctate keratitis (SPK), few treatments are more effective.⁴ There are risks to withholding steroids when managing inflammatory diseases such as corneal neovascularization, synechiae, persistent SPK, progressive dry eye, corneal haze and scarring.

At the same time, don't be cavalier with steroids. Although the only absolute contraindication is epithelial herpetic disease, there are times when you should apply caution in their use. For example, be wary of steroids when treating an early infectious keratitis (especially without a confirmed diagnosis), an abrasion or when using a bandage contact lens. There still may be a role for steroids in such cases, but exercise greater caution. Always check intraocular pressure within three to five weeks for any patient on a corticosteroid. To help ensure the patient returns for the check, I often provide no refills on steroid-containing drops in new patients.

Systemic Medications

An optometrist without access to systemic meds is in a difficult position to effectively care for patients.

Many cases necessitate systemic therapy, and in today's healthcare system, a referral before treatment leaves the patient vulnerable to significant morbidity. Soft tissue infections such as dacryocystitis, hordeola, canaliculitis and preseptal cellulitis are just one category that comes to mind (orbital cellulitis requires referral to an emergency room for intravenous antibiotics).

Systemic medications are also required to fully control chronic conditions such as ocular rosacea, multiple or repeat hordeola and chalazia, and chronic ocular surface disease. Severe allergies, dermatological disorders and immune responses may require a short course of oral prednisone. One cannot manage most cases of ocular herpes simplex virus without oral antivirals, and even over-the-counter oral nonsteroidals can greatly aid a patient with a corneal abrasion.

It's nearly impossible to effectively manage ocular disease without occasionally having to reach into the bag for an oral medication. Give this hard-won legal right the recognition—and use—it deserves. ■

Note: Dr. Karpecki is a consultant for many companies discussed here.

1. Asbell PA, Sanfilippo CM, Pillar CM, et al. Antibiotic resistance among ocular pathogens in the United States: five-year results from the Antibiotic Resistance Monitoring in Ocular Microorganisms (ARMOR) Surveillance Study. *JAMA Ophthalmol.* 2015;133(12):1445-54.
2. Stern ME, Gao J, Schwalb TA, et al. Conjunctival T-cell subpopulations in Sjögren's and non-Sjögren's patients with dry eye. *Invest Ophthalmol Vis Sci.* 2002;43(8):2609-14.
3. Deveci H, Kobak S. The efficacy of topical 0.05% cyclosporine A in patients with dry eye disease associated with Sjögren's syndrome. *Int Ophthalmol.* 2014;34(5):1043-8.
4. Coursey TG, de Paiva CS. Managing Sjögren's syndrome and non-Sjögren syndrome dry eye with anti-inflammatory therapy. *Clin Ophthalmol.* 2014;8:1447-58.

Are you tired of...

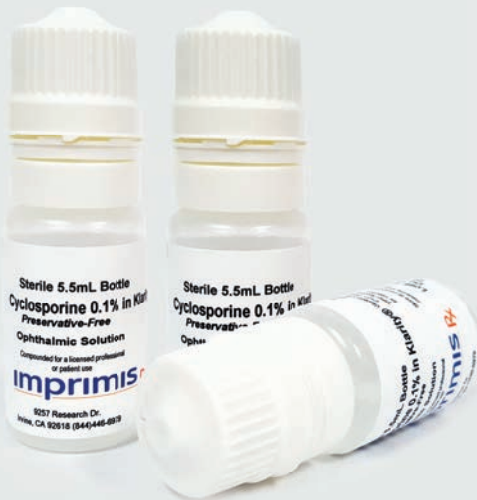...countless **prior authorizations**
with **repeat denials?**

...handing out **stacks of coupons** that often
don't work for many of your patients?

... multiple **call backs** from pharmacies
and patients taking up your **valuable time?**



We have the solution for you and your patients:



TOTALTEARS™

**Cyclosporine 0.1% / Chondroitin
Sulfate Ophthalmic Emulsion***
(preservative-free) 5.5mL Bottles

First 3 bottles \$99⁹⁹

No Prior Authorizations

No Coupons

No Pharmacy Call Backs

Learn more at www.imprimisrx.com/RevOfOpt2018

*For professional use only. Imprimis Pharmaceuticals specializes in customizing medications to meet unique patient and practitioner needs. Imprimis Pharmaceuticals dispenses only to individually identified patients with valid prescriptions. No compounded medication is reviewed by the FDA for safety or efficacy. Imprimis Pharmaceuticals does not compound copies of commercially available products. References available upon request.

Total Tears and ImprimisRx are trademarks of Imprimis Pharmaceuticals, Inc. ©2018 Imprimis Pharmaceuticals, Inc. All Rights Reserved. IMPO0242 3/18

imprimis **Rx®**
844.446.6979

The Extinction of the Ink Pen

...and other things. What's in your pile of office junk you never use anymore?

By Montgomery Vickers, OD

Now that we are all techno post-pseudo-Millennials, I cannot find an ink pen anywhere. That's right, people from the South call it an ink pen. If you do *not* call it an ink pen, you are either a transplant from the North or pretentious. Either way is fine by me.

I do have a couple of ink pens that survived the Great Ink Pen Purge created by the Feds in an attempt to protect patient records by making it easier for any basement-dwelling hacker get *all* of them with the stroke of a key. Before, they had to break into my office and carry them out, which is way more effort than any hacker would expend.

There are so many other things that have become extinct in the new frontier of optometry:

Pen lights. There may be a few holdouts who test every pupil every time with a penlight, but most of us know if anything's messed up by the time we hit them with a slit lamp.

PD ruler. Why bother? ODs are always griping about not being paid for giving patients PDs. Folks, anything on the patient's chart is *their* information, not *yours*. If you like to fight over releasing PDs, just quit measuring them. You can't give them what you don't have.

Trifocals. Now and then a patient wanders in who loves his version of "start, step and stumble," but most aren't very excited to have any lines on their glasses, much less two.

Double segs. Another victim of the tech age where mechanics and electricians plug a gizmo in to reset

everything instead of actually doing anything real. Have you noticed how soft their hands are these days?

Quarterly soft contact lenses. What? You still have some patients disposing of their lenses once every 90 days? That's just two 90 packs of dailies lasting 22 years.

Bandage contact lenses. You remember, the ones that were actually studied and approved by the FDA for this use only. I'll bet I know what you really use.

Paper Snellen charts. OK, these are not extinct, but 100% of them are at the pediatrician's office where your patient's kid "just had an eye exam." To be fair, they don't need to see the pediatrician for a physical either because, well, they seemed healthy enough when we saw them.

Last-minute cancellations. I just stuck this in here because I knew you'd laugh.

Shirt and tie. The last time I saw this in the office was me passing by a mirror. The staff and the patients absolutely loved it, so try it.

Being on time. Now that we have 200 separate pretesting instruments, we might see our 9am by 9pm, but at least we'll know the exact wavelength color of

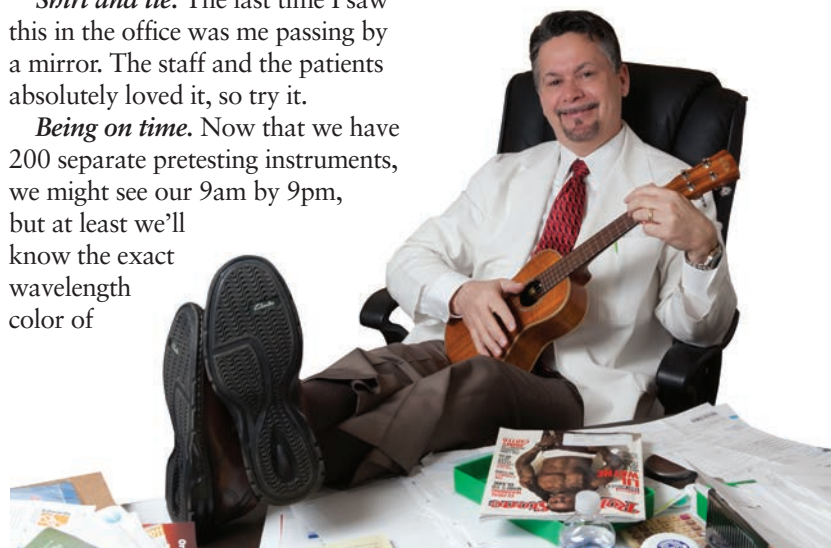their irides and how long they slept.

Confirmation calls. When patients had one phone in the house, two rings garnered an answer. Now everyone has a phone glued to their ear, but no one answers.

Lunchtime office hours. I blame myself for this one. I started closing the office for lunch in 2006. This attracted patients like bears to honey, and they all came to pick up stuff as soon as I locked the door.

Elevator music. Once a staple of every reception area, the soothing orchestral versions of the Beatles' White Album has given way to big TVs explaining progressive spectacle lenses to people wearing ear buds listening to orchestral versions of the Beatles' White Album.

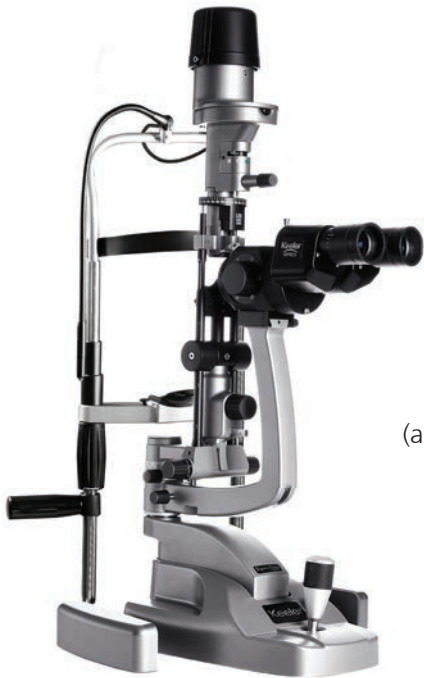It's OK, time marches on. The next generation will look back fondly on extinct stuff, too. Like ODs, if we don't watch out. ■



The Keeler³ Trade In Program

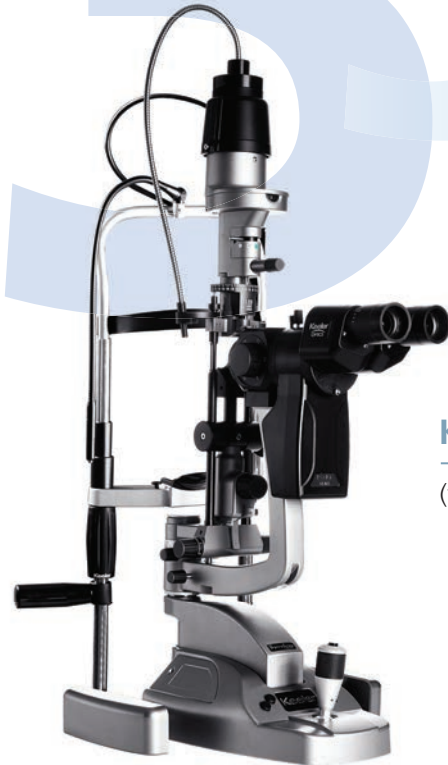Buy 3 // Trade 3 // Get 1 Free

The Power of 3. Purchase any 3 Keeler Slit Lamps and trade in 3 of your old Slit Lamps and we'll send you a 4th Keeler Slit Lamp absolutely free of charge.



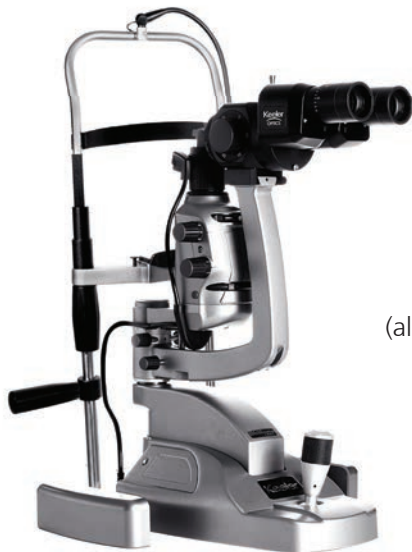KSL-H

(also in Digital Ready)



KSL-H-D

(full Digital)



KSL-Z

(also in Digital Ready)



KSL-H-D

(full Digital)



Keeler Instruments, Inc. • 3222 Phoenixville Pike, bldg. 50 • Malvern, PA 19355
Tel: (800) 523-5620 • Fax: (610) 353-7814 • email: keeler@keelerusa.com

Offer valid until June 30, 2018.

Contact Keeler or one of our authorized dealers for more information.



Taking the Floor on Fractures

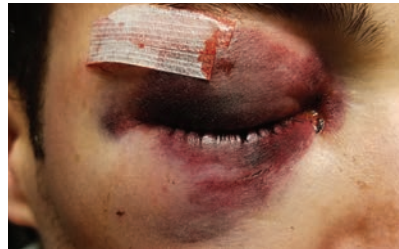When a mishap puts an orbital floor fracture in your chair, know how to look past the gore and devise a plan. **Edited by Paul C. Ajamian, OD**

Q A patient called me Sunday evening after being on the losing end of a bar brawl Friday night. When seen in the ER on Saturday, a CT scan revealed an orbital floor fracture. He was told to see an eye doctor. How do you examine this swollen eye and how do you know when surgery is in order?

A “First of all, don’t panic,” says James Milite, MD, an oculoplastic surgeon from Omni Eye Services in Iselin, NJ. In many cases, the impact of the injury will make the eye look worse than it is. “Take a step back and take your time doing a thorough exam,” he says.

A comprehensive history is your next step. You’ll want to know how the injury happened and what struck the eye. “Ask if there was any loss of consciousness at the scene of the incident; also find out if there have been any flashes, floaters or double vision. Check their lateral gaze and downgaze, ability to open and close the mouth, and look for evidence of decreased sensitivity in the distribution of the maxillary division of the trigeminal nerve,” says Dr. Milite.

After ruling out head trauma and foreign bodies, conduct your typical eye exam—acuties, confrontation fields, pupils and a careful anterior and posterior segment exam. “Make sure the retinal periphery is OK, and look out for corneal abrasions, hyphema, iridodialysis, uveitis, cataract, vitreous hemorrhage and retinal detachment,” adds Dr. Milite. Also, examine the orbit. “This can be the trickiest part due to the eye swelling,” he says. “Observe if the globe is sunken or displaced downward



A 25-year-old male with orbital floor fracture raises questions about the need for reconstructive surgery.

away from the midline. This might indicate a fracture of the cheek bone or cheek complex,” he says. Left untreated, it could permanently pull the lower lid down or flatten the malar region.

To Refer or Not to Refer?

After examination, you should have a sense of whether or not you have a surgical candidate on your hands, says Dr. Milite. “You’re looking for either or both of the following: entrapment causing restriction of extraocular muscles (EOMs) and diplopia in functional fields, and enophthalmos greater than 2mm.” However, the degree of periorbital edema often makes assessment of globe position and motility difficult.

“It’s also important to look out for signs of proptosis of the eye,” adds Dr. Milite. “This is an indicator of a retrobulbar hemorrhage.” Though uncommon, it necessitates an urgent referral to an oculoplastic specialist. All these patients require CT imaging if not already obtained prior to your exam.


Typically, if the primary injury is an orbital floor fracture, you won’t

need to send for emergency surgery. However, there are a few extenuating circumstances. Young kids, for example, can more easily present with entrapment and require immediate surgery. “I usually see this in kids under age 13,” adds Dr. Milite, “as their bones are pliable and don’t crack—they bend and snap back, causing tight EOM entrapments.” This can lead to nausea, vomiting and a decrease in blood pressure.

Since the fracture snaps closed almost like a trap door, it might not seem significant on the scan, but these signs represent a potentially urgent case and require a rapid referral to an oculoplastic surgeon. Failure to refer could result in irreparable damage to the tightly entrapped muscle.

When choosing to treat these cases with antibiotics or steroids, a few simple rules will suffice. “Antibiotics are given due to theoretical risk of infection, so a five-day course of prophylactic antibiotic can’t hurt,” says Dr. Milite. “If you have a patient with a moderate-size fracture and excessive swelling, an oral steroid will cut the window down for edema resolution to unmask the development of enophthalmos and help determine the need for repair.”

Consult a specialist if in doubt. In this case, referral resulted in surgery later that week. “Describe the fracture, explain motility issues and record everything,” Dr. Milite says. “If it’s a surgical candidate, ask what you can do to prepare the patient before sending them along.” ■

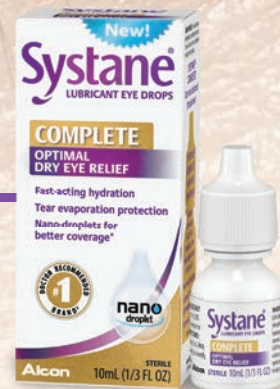

SYSTANE® COMPLETE:

OUR MOST ADVANCED SOLUTION. ONE SIMPLE CHOICE.¹⁻²

Our most innovative drop works to restore the tear film. It provides optimal relief by addressing **every major type of dry eye**.¹⁻⁷

- Evaporative Dry Eye**
- Aqueous-deficient Dry Eye**
- Mixed Dry Eye**



The Relief is Real™



With **advanced, lipid nano-droplet technology**, the lubricant is rapidly delivered across the ocular surface—resulting in **better coverage*** to provide fast hydration and locking in moisture for long-lasting relief.^{1-2,5,6,8}

TALK TO A REPRESENTATIVE TO LEARN MORE

*Compared to SYSTANE® BALANCE.

1. Ketelson H, Rangarajan R. Pre-clinical evaluation of a novel phospholipid nanoemulsion based lubricant eye drops. Poster presented at: The Annual Meeting of the Association for Research in Vision and Ophthalmology (ARVO); May 7-11, 2017; Baltimore, Maryland, USA. 2. Data on file. Alcon; 2017. 3. Fernandez KB, Epstein SP, Raynor GS, et al. Modulation of HLA-DR in dry eye patients following 30 days of treatment with a lubricant eyedrop solution. *Clin Ophthalmol*. 2015;9:1137-1145. 4. Davitt WF, Bloomstein M, Christensen M, Martin AE. Efficacy in patients with dry eye after treatment with a new lubricant eye drop formulation. *J Ocul Pharmacol Ther*. 2010;26(4):347-353. 5. Korb D, Blackie C, Meadows D, Christensen M, Tudor M. Evaluation of extended tear stability by two emulsion based artificial tears. Poster presented at: 6th International Conference of the Tear Film and Ocular Surface: Basic Science and Clinical Relevance; September 22-25, 2010; Florence, Italy. 6. Lane S, Paugh J, Webb JR, Christensen MT. An evaluation of the in vivo retention time of a novel artificial tear as compared to a placebo control. Poster presented at: The Annual Meeting of the Association for Research in Vision and Ophthalmology (ARVO); May 3-7, 2009; Fort Lauderdale, FL. 7. Craig JP, Nichols KK, Akpek EK, et al. TFOS DEWS II definition and classification report. *Ocul Surf*. 2017;15:276-283. 8. Torkildsen G. The effects of lubricant eye drops on visual function as measured by the Inter-blink interval Visual Acuity Decay test. *Clin Ophthalmol*. 2009;3:501-506.



PRINTED IN USA

FOUNDING EDITOR, FREDERICK BOGER
1891-1913

EDITORIAL OFFICES

11 CAMPUS BLVD., SUITE 100
NEWTOWN SQUARE, PA 19073

WEBSITE • WWW.REVIEWOFOPTOMETRY.COM

SUBSCRIPTION INQUIRIES

1-877-529-1746

CONTINUING EDUCATION INQUIRIES

1-800-825-4696

EDITOR-IN-CHIEF • JACK PERSICO

(610) 492-1006 • JPERSICO@JOBSON.COM

MANAGING EDITOR • REBECCA HEPP

(610) 492-1005 • RHEPP@JOBSON.COM

SENIOR EDITOR • BILL KEKEVIAN

(610) 492-1003 • BKEKEVIAN@JOBSON.COM

ASSOCIATE EDITOR • MICHAEL IANNUCCI

(610) 492-1043 • MIANNUCCI@JOBSON.COM

ASSOCIATE EDITOR • FRANCESCA CROZIER-FITZGERALD

(610) 492-1021 • FCROZIER@JOBSON.COM

SPECIAL PROJECTS MANAGER • JILL HOFFMAN

(610) 492-1037 • JHOFFMAN@JOBSON.COM

ART DIRECTOR • JARED ARAUJO

(610) 492-1032 • JARAUJO@JOBSON.COM

DIRECTOR OF CE ADMINISTRATION • REGINA COMBS

(212) 274-7160 • RCOMBS@JOBSON.COM

EDITORIAL BOARD

CHIEF CLINICAL EDITOR • PAUL M. KARPECKI, OD

ASSOCIATE CLINICAL EDITORS • JOSEPH P. SHOVLIN, OD;
ALAN G. KABAT, OD; CHRISTINE W. SINDT, OD

DIRECTOR OPTOMETRIC PROGRAMS • ARTHUR EPSTEIN, OD

CLINICAL & EDUCATION CONFERENCE ADVISOR

PAUL M. KARPECKI, OD

CASE REPORTS COORDINATOR • ANDREW S. GURWOOD, OD

CLINICAL CODING EDITOR • JOHN RUMPAKIS, OD, MBA

CONSULTING EDITOR • FRANK FONTANA, OD

COLUMNISTS

CHAIRSIDE • MONTGOMERY VICKERS, OD

CLINICAL QUANDARIES • PAUL C. AJAMIAN, OD

CODING CONNECTION • JOHN RUMPAKIS, OD

CORNEA & CONTACT LENS Q+A • JOSEPH P. SHOVLIN, OD

DIAGNOSTIC QUIZ • ANDREW S. GURWOOD, OD

THE ESSENTIALS • BISANT A. LABIB, OD

FOCUS ON REFRACTION • MARC TAUB, OD;

PAUL HARRIS, OD

GLAUCOMA GRAND ROUNDS • JAMES L. FANELLI, OD

NEURO CLINIC • MICHAEL TROTTINI, OD;

MICHAEL DELGIODICE, OD

OCULAR SURFACE REVIEW • PAUL M. KARPECKI, OD

RETINA QUIZ • MARK T. DUNBAR, OD

REVIEW OF SYSTEMS • CARLO J. PELINO, OD;

JOSEPH J. PIZZIMENTI, OD

SURGICAL MINUTE • DEREK N. CUNNINGHAM, OD;

WALTER O. WHITLEY, OD, MBA

THERAPEUTIC REVIEW • JOSEPH W. SOWKA, OD;

ALAN G. KABAT, OD

THROUGH MY EYES • PAUL M. KARPECKI, OD

URGENT CARE • RICHARD B. MANGAN, OD

JOBSON MEDICAL INFORMATION LLC



Outlook

By Jack Persico, Editor-in-Chief



A Significant Proposal

Want better clinical outcomes? Demand better study design, experts say.

Lies, they say, come in three varieties: lies, damn lies and statistics. Cynical though it may sound, that rings true for anyone whose profession revolves around numbers. Medicine, of course, is rife with statistics: the incidence and prevalence of diseases, the efficacy of therapies, optimal dosing regimens, adverse events, risk factors, survival rates—all are expressed in numeric terms, sometimes to a hundredth of a decimal point. Even quality of life, by its very name a qualitative measure, gets quantified in health care.

Do doctors rely too much on the statistics in medical literature? The people in charge of medicine and the people in charge of statistics think so. An editorial in the *Journal of the American Medical Association*, echoing the American Statistical Association, argues that probabilities (expressed by the P value) “are misinterpreted, overtrusted and misused.”¹

Actually, it’s fairer to say that the problem isn’t so much reliance on statistics but rather the way in which we ascribe validity to medical ‘facts’ that are expressed numerically. The two groups seek to tighten that up by advocating for “lowering the routine P value threshold for claiming statistical significance from 0.05 to 0.005 for new discoveries.” That means the likelihood of a random (rather than causative) association in a study would drop from 5% to 0.5%, raising the bar for what gets called significant. This would “shift about one-third of the statistically significant results of past biomedical literature to the category of just ‘suggestive,’” the editorial states.

Poof, one-third of your ‘facts’ just went up in smoke.

It’s a scary proposition, but may be for the best. Such a move would cut a lot of noise out of the conversation. Too many studies using P values in the 0.05 range are quoted and promoted as gospel, in eye care and other disciplines. “Most claims supported with P values slightly below 0.05 are probably false (i.e., the claimed associations and treatment effects do not exist),” the editorial states. “Even among those claims that are true, few are worth acting on in medicine and health care.”

And yet, many of those claims are the lifeblood of medical practice today. Health care would be better off, says the editorial, “with fewer, larger, and more carefully conceived and designed studies with sufficient power to pass these more demanding thresholds.”

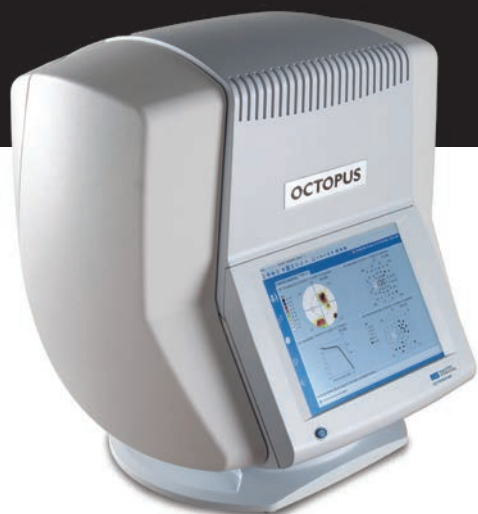Of course, this would be no panacea. Those with a vested interest, most notably for-profit entities more interested in finding a marketing angle rather than the purity of truth, could just move the goalposts. “Selected study end points may become even less clinically relevant because it is easier to reach lower P values with weak surrogate end points than with hard clinical outcomes,” *JAMA* warns.

It’s not easy to think of scientific validity as a tunable instrument: turn the dial up and certainty goes down. But this proposal reminds us that our facts are only as ‘real’ as our methods—and motives—demand. ■

1. Ioannidis JP. The proposal to power P value thresholds to .005. *JAMA*. March 22, 2018 [Epub ahead of print].

OCTOPUS 600.

YOU'LL DETECT A DIFFERENCE RIGHT AWAY.



Reach threshold in just 2.5 minutes
with the fast, accurate TOP strategy.

With the Octopus 600, the differences start with TOP, an exclusive strategy that maximizes patient compliance and minimizes chair time with thresholds in a blazing 2.5 minutes. Our Pulsar stimulus detects glaucomatous changes far earlier, and true fixation control eliminates bad data due to fixation losses, while EyeSuite allows you to look at it all with a click of a button.

Learn more at HSoctopus.com.

800.787.5426
HSoctopus.com

© 2018 Haag-Streit USA. All Rights Reserved.

 HAAG-STREIT
USA



No Sneaking Around this Code

Modifier -59 should be a last resort. Here's how to use it wisely.

By John Rumpakis, OD, MBA, Clinical Coding Editor

Consider this scenario: A patient comes in for a glaucoma workup after being identified as a suspect during last week's annual exam. During this follow-up office visit (9921X) you want to do: optical coherence tomography (OCT) optic nerve (92133), fundus photography (92250), pachymetry (76514) and threshold visual fields (92083).

The Temptation

You know fundus photography and OCT of the optic nerve are not allowed on the same date of service. However, you have heard certain modifiers, such as -59, can “override” these rules on the claim form so you can get paid for both services. So what should you do? Let's take a look.

Where to Start

The rules that govern situations such as this one are the National Correct Coding Initiative (NCCI) edits, which are found in CMS's *NCCI Policy Manual For Medicare Services*, published yearly and updated quarterly. These edits control the pairing of procedures on the same date of service.¹

Understanding these code pairing rules and their context is crucial, especially when applying a modifier that will override a claim pair denial. One of the most abused modifiers is -59.

CMS Definition

To properly use a modifier, you must know both the definition and

its proper application. Modifier -59 is used to identify procedures/services, other than E/M services, that are not normally reported together, but are appropriate under the circumstances. Documentation must support a different session, different procedure or surgery, different site or organ system, separate incision/excision, separate lesion or separate injury (or area of injury if extensive) not ordinarily encountered or performed on the same day by the same individual. Modifier -59 can be used appropriately in these situations (remember, the eye is considered a single anatomic structure and site):^{2,3}

1. “Modifier -59 is used appropriately for different anatomic sites during the same encounter only when procedures which are not ordinarily performed or encountered on the same day are performed on different organs, or different anatomic regions, or in limited situations on different, non-contiguous lesions in different anatomic regions of the same organ.”³
2. “Another common use of modifier -59 is for surgical procedures, non-surgical therapeutic procedures or diagnostic procedures that are performed during different patient encounters on the same day and that cannot be described by one of the more specific NCCI-associated modifiers—i.e., 24, 25, 27, 57, 58, 78, 79 or 91. As noted

in the CPT definition, modifier -59 should only be used if no other modifier more appropriately describes the relationship of the two procedure codes.”³

Limitations

Modifier -59 should not be appended to an E/M service. To report a separate E/M service with a non-E/M service performed on the same date, use modifier -25.⁴

You should never use modifier -59 to bypass a PTP edit unless you meet and document the proper criteria required by any NCCI-associated modifier. The use of modifier -59 does not require a different diagnosis for each HCPCS/CPT coded procedure; conversely, different diagnoses are not adequate criteria for use of modifier -59. The HCPCS/CPT codes remain bundled unless the procedures are performed at different anatomic sites or separate patient encounters.⁴

Misuse

Modifier -59 is used inappropriately if the basis for its use is simply that the narrative description of the two codes is different.

One of the common misuses of modifier -59 is related to the portion of the definition allowing its use to describe a “different procedure or surgery.” The code descriptors of the two codes of a code pair edit usually represent different procedures, even though they may be overlapping. The edit indicates that the two procedures should not

be reported together if performed at the same anatomic site and same patient encounter, as those procedures would not be considered “separate and distinct.”

However, if the two procedures are performed at separate anatomic sites or at separate patient encounters on the same date of service, modifier -59 may be appended to indicate that they are different procedures on that date of service.

-59 in Your Office

In ophthalmic practice, the most common combination with which modifier -59 is improperly used is CPT codes 92250 and 92133/92134. The NCCI manual specifically states: “Fundus photography (92250) and scanning ophthalmic computerized diagnostic imaging (e.g., 92133, 92134) are generally mutually exclusive of one

another in that a provider would use one technique or the other to evaluate fundal disease.

As with most rules, a few exceptions exist, and there are a limited number of clinical conditions where both techniques are medically reasonable and necessary on the ipsilateral eye. In these situations, both CPT codes may be reported appending modifier -59 to CPT code 92250.”⁵

Those limited number of clinical conditions must meet the definition of medical necessity, i.e., patient harm could be a result if the two tests aren’t performed on the same date of service. This does not mean there is a wholesale acceptance of this code combination with modifier -59 just because the doctor thinks it’s appropriate or because it is convenient for either the doctor or the patient.

For our case example, using modifier -59 on the fundus photography code might get you paid, but it is not appropriate. You must first establish proper medical necessity for each procedure that you need to perform. Remember, modifier -59 is a last resort and should be used sparingly in clinical practice. ■

Send questions and comments to rocodingconnection@gmail.com.


1. Centers for Medicare and Medicaid Services (CMS). National Correct Coding Initiative Edits. www.cms.gov/Medicare/Coding/NationalCorrectCodingInitiative/index.html. Accessed February 22, 2018.
2. CMS. Modifier 59 Article. www.cms.gov/Medicare/Coding/NationalCorrectCodingInitiative/Downloads/modifier59.pdf. Accessed February 22, 2018.
3. CMS. Proper Use of Modifier 59. www.cms.gov/Outreach-and-Education/Medicare-Learning-Network-MLN/MLNMattersArticles/Downloads/SE1418.pdf. Accessed February 22, 2018.
4. CMS. NCCI Policy Manual For Medicare Services – Effective January 1, 2018:I-20, I-25, III-18, IV-23, V-29, VI-19, VII-20, VIII-26, IX-25, XI-12, XI-52, XII-21, XIII-10. www.cms.gov/Medicare/Coding/NationalCorrectCodingInitiative/index.html. Accessed February 22, 2018.
5. CMS. NCCI Policy Manual For Medicare Services – Effective January 1, 2018:XI-12. www.cms.gov/Medicare/Coding/NationalCorrectCodingInitiative/index.html. Accessed February 22, 2018.



OPTOMETRIST RECRUITING

Need help recruiting an Optometrist
to join your practice?

Email us:
recruiting@localeyesite.com





Fresnel Prism to the Rescue

Finding the perfect prism can take time and patience, but once it fits, it sticks.

By **Marc B. Taub, OD, MS**, and **Paul Harris, OD**

When we are called to see patients at a rehabilitation facility, and occasionally when patients are scheduled for vision therapy evaluations at Southern College of Optometry, we truly do not know what we are going to encounter. Brain injury cases range from visual field and acuity loss to visual inattention to vague complaints that something simply “feels off.” Of course, some patients are in such a state of decreased mental and physical capacity that they cannot respond in a traditional manner. Those are the most challenging, but can reap huge rewards for the patients in the long run.

Perhaps the most common

complaint we encounter is double vision. This occurs for a multitude of reasons, including muscle and nerve injury, and can be quite severe. In these situations, the extent may vary depending on the gaze and head position. In the short term, we often use occlusion—either binasal or spot—to eliminate the double vision and evaluate the visual system weeks later as the visual, and cognitive and control systems come back online. For comitant diplopia, we often investigate the use of prism to attempt to restore single vision. The two cases presented here demonstrate how the use of temporary Fresnel prism can get your patients on the road to recovery quickly and effectively.

Case One

One morning, a 44-year-old male reported that, several days prior, he was pulling into a parking spot at work, and when backing in, he turned his head to get a better view and suddenly felt different. It turns out, he had a major aneurysm and did something to the blood vessels and supply to his brainstem. Ever since, he had double vision. When he presented, he was wearing an eye patch. Luckily, he was still operating at a high cognitive level, a crucial aspect when considering the use of Fresnel prism.

Visual acuity, confrontation fields, pupils and eye movements were all normal. His primary complaint was the double vision, which he described as “vertical.” Upon visual inspection, the eyes appeared aligned. Cover testing at distance and near revealed a six prism diopter right hypertropia. The magnitude was not changed by altering his head posture or gaze. This was confirmed subjectively and objectively via cover test with loose prism. Not all patients suffering from brain injury double vision can obtain single vision so soon after, so we considered this a good opportunity to use temporary prism. However, the higher the prism strength, the more the visual acuity is degraded. Some patients are not willing or are unable to adjust to the degraded acuity. As his acuity without glasses was excellent, tried frames with plano lenses we had handy.



These frames, fit binocularly with Fresnel prism, can be used to restore single vision to patients such as the one in our first case.

Why 13.6?



Meet Nina.

She has smaller than average diameter corneas. Fact is, 27% of patient corneas fall outside the norm.

Select **Extreme H2O 13.6** for Nina. Easy to handle, 13.6 fits her smaller corneal size.

If you explain why the 13.6 size is right for her eyes, she is more likely to remain a loyal patient, not someone shopping for a deal.

Don't put her in a one size fits all lens she can get anywhere. Fit Extreme H2O specialty disposable soft contact lenses.

extremeH2O[®] 13.6

The right solution for your patients who:

- Have small corneas or lid apertures
- Need easy insertion and removal
- Need a comfortable lens

Extreme H2O 13.6 is available in daily, weekly and monthly modalities to match her lifestyle and her pocketbook.

13.6 is just one example of how we cater to your needs. Challenge us to help you protect your contact lens practice. **Call X-Cel Specialty Contacts at 877.336.2482 today.**



These frames are similar to the ones on page 28, but are only fit monocularly with Fresnel prism. The other lens is plano.

The use of prism follows a pattern we have presented over and over in this column: less is typically more. Over our careers, we have both found that patients need less prism for fusion than measured on the cover test or even as measured with standard von Graefe or other methods. Giving less prism than measured also serves a therapeutic role in leaving degrees of freedom in which the system can operate.

With two base down over the right eye and two base up over the left eye, the patient reported seeing single vision. We informed him that these were full-time glasses and confirmed with the rehabilitation team that there were no visual restrictions. We checked back several days later and the patient was still smiling. The rehab team reported good progress on balance and hand-eye coordination activities. He will follow up with the vision rehab service at the college in several weeks.

You may be wondering why we chose to split the prism. With a patient who sees well, even though he comprehends the potential for

degraded vision, we tend to split the prism to even out the acuity decrease. Essentially, this brings down both eyes equally instead of penalizing one; lessening the visual acuity in one eye would throw off the binocular system we are working so hard to rehabilitate. If one eye has decreased acuity for whatever reason, choosing not to split the prism may be a better option. In that instance, we tend to put the full amount of the prism or the bulk of it in front of the eye with the worse visual acuity or was turned all the time.

Case Two

Immediately following the previous patient, a 63-year-old male who suffered a head injury after a fall presented to the clinic. The patient was in good spirits and was joking around with me, which is always a good sign. Unlike the patient described in case one, he was not wearing a patch, indicating that either the magnitude of the diplopia was especially high or fairly low. If the magnitude of the diplopia is large, one of the images

may be out of the patient's line of sight. On the other hand, if the magnitude of the diplopia is small, there is potential that the patient is indeed fusing some of the time. In this case, it was fortunately the latter. As with the first case, the patient was refractively normal. The double vision was intermittent, occurring 50% of the time without a recognizable pattern on the part of the patient or therapists. Cover testing showed a three diopter left hyperphoria.

We grabbed our plano spectacles and Fresnel powers of one and two prism diopters from the kit. Subjectively, the patient reported good fusion with the lower power but felt more comfortable with the higher one. We allowed him to sit with the prism on and questioned him regarding the acuity difference. Since he was thrilled to not see double, he was not fazed by the slight acuity difference. We ended up with two prism diopters base down in the right eye on the plano spectacles and the patient was happy.

The therapists were ecstatic at the improvement in skills several days later. He too will be re-evaluated in several days. We are hoping to either reduce or eliminate the prism if symptoms abated.

Fresnel prisms can aid your patient care regardless of whether or not you treat patients with stroke or traumatic brain injury.

If you are considering grinding in prism, the temporary prism can help confirm the amount needed. In some cases, the use of the prism has a therapeutic effect and the amount of prism can be reduced over time. This is especially true of patients in vision therapy.

For some reason, optometrists seem afraid of prism. With the use of Fresnel prism, this fear should be eliminated. ■

OPEN YOUR EYES TO A FRESH START:

EYE HEALTH OF PATIENTS WHO SLEEP IN THEIR CONTACT LENSES



Reed Bro, OD

Optometrist
Eye Care Center of Colorado Springs
Colorado Springs, CO

Dr Reed Bro was compensated by Alcon for his participation in this advertorial.

Sleeping in contact lenses that aren't approved for such use has been associated with discomfort, as well as with more serious eye health problems.¹ Even so, a survey of contact lens wearers found that 64% of those who sleep in their lenses for at least a week at a time are not wearing extended/overnight use lenses.² A separate study found that about one-third of contact lens patients report wearing their lenses to bed.³

In our practice, many patients want extended-wear contact lenses because of lifestyle demands, such as new moms, shift workers and on-call physicians and nurses. One of my patients—a law student—spends endless hours studying in the school library and sleeps for a few hours at a time, taking naps when his schedule allows. He recently complained of lens discomfort and frequent redness, and his history revealed that he often wore 2-week replacement lenses continuously and overnight for a week at a time (for which his lenses were not approved). I explained that sleeping in lenses like his could cause the discomfort he was describing, and that it also increased his risk of ulcerative keratitis, a serious condition that can lead to loss of vision, which is usually caused by a microbial infection. I switched him to AIR OPTIX® NIGHT & DAY® AQUA contact lenses because, unlike some overnight lenses that are available, I find that AIR OPTIX® NIGHT & DAY® AQUA contact lenses provide continuous comfort,⁴ and are specifically designed for continuous wear, even while napping and sleeping. The lenses are FDA approved for daily wear and up to 30 nights of continuous wear.*

AIR OPTIX® NIGHT & DAY® AQUA contact lenses are made from lotrafilcon A, a lens material with an established safety profile including a low rate of microbial keratitis.⁵ In a study of more than 6,000 lotrafilcon A wearers, only 0.18% of patients were diagnosed with presumed microbial

Unpredictable Work Schedules	Busy Professionals	Frequent Travelers	Moms with Young Kids
Need immediate vision waking up for shift	Eyes feel strained looking at my mobile devices	Travel too often to hassle with my lenses	Can't see clearly getting up throughout the night

keratitis, and less than 0.04% with presumed microbial keratitis and a loss of visual acuity.

My patients' eye health is important to me and my practice, but I also want to make sure that overnight lens wearers remain comfortable throughout the full recommended wearing period. AIR OPTIX® NIGHT & DAY® AQUA contact lenses feature SmartShield® Technology, a proprietary surface technology that protects against the inherent hydrophobic properties of silicone.^{6,7} SmartShield® Technology acts as a protective barrier, limiting exposure of silicone on the surface of AIR OPTIX® contact lenses, and thereby helping to maintain excellent surface wettability and deposit resistance. With this technology, my patients can experience clear vision and consistent comfort from the first day they put on their lenses, waking up

to these benefits for up to 30 days thereafter.

Since the health of my patients is very important to me, I'm concerned that so many may be inappropriately wearing their contact lenses overnight. As their eye doctor, my job is to educate them and provide the best lenses to meet their needs. Thanks to the many benefits of AIR OPTIX® NIGHT & DAY® AQUA contact lenses, I can provide comfort to my overnight lens-wearing patients, ensuring that they see, look and feel their best.




Our passion is to help your patients see, look and feel their best.



*Extended wear for up to 30 continuous nights, as prescribed by an eye care practitioner

Important information for AIR OPTIX® NIGHT & DAY® AQUA (lotrafilcon A) contact lenses: Indicated for vision correction for daily wear (worn only while awake) or extended wear (worn while awake and asleep) for up to 30 nights. **Relevant Warnings:** A corneal ulcer may develop rapidly and cause eye pain, redness or blurry vision as it progresses. If left untreated, a scar, and in rare cases loss of vision, may result. The risk of serious problems is greater for extended wear vs. daily wear and smoking increases this risk. A 1-year postmarketing study found 0.18% (18 out of 10,000) of wearers developed a severe corneal infection, with 0.04% (4 out of 10,000) of wearers experiencing a permanent reduction in vision by two or more rows of letters on an eye chart. **Relevant Precautions:** Not everyone can wear for 30 nights. Approximately 80% of wearers can wear the lenses for extended wear. About two-thirds of wearers achieve the full 30 nights continuous wear. **Side Effects:** In clinical trials, approximately 3-5% of wearers experience at least one episode of infiltrative keratitis, a localized inflammation of the cornea which may be accompanied by mild to severe pain and may require the use of antibiotic eye drops for up to one week. Other less serious side effects were conjunctivitis, lid irritation or lens discomfort including dryness, mild burning or stinging. **Contraindications:** Contact lenses should not be worn if you have: eye infection or inflammation (redness and/ or swelling); eye disease, injury or dryness that interferes with contact lens wear; systemic disease that may be affected by or impact lens wear; certain allergic conditions or using certain medications (eg. some eye medications). **Additional Information:** Lenses should be replaced every month. If removed before then, lenses should be cleaned and disinfected before wearing again. Always follow the eye care professional's recommended lens wear, care and replacement schedule. Consult package insert for complete information, available without charge by calling (800) 241-5999 or go to myalcon.com.

References 1. Stapleton F, et al. The Incidence of Contact Lens-Related Microbial Keratitis in Australia. *Ophthalmology*. 2008;115:1655-62. 2. Alcon data on file, 2012. 3. In a survey of 2,115 daily and extended wear contact lens patients. Alcon data on file, 2012. 4. Alcon data on file, 2012. 5. Schein OD, McNally JJ, Katz J, et al. The incidence of microbial keratitis among wearers of a 30-day silicone hydrogel extended-wear contact lens. *Ophthalmology*. 2005;112:2172-9. 6. Alcon data on file, 2012, 2013. 7. Epstein AB, et al. Surface and polymer chemistry: the quest for comfort. *Rev Cornea Contact Lens*. 2010;247:15-9.



Hold 'em or Fold 'em?

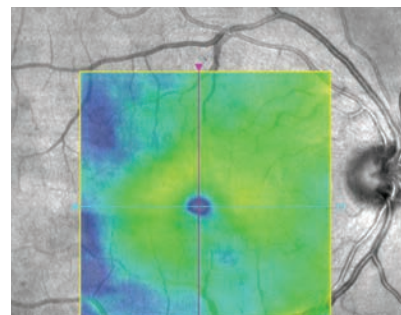
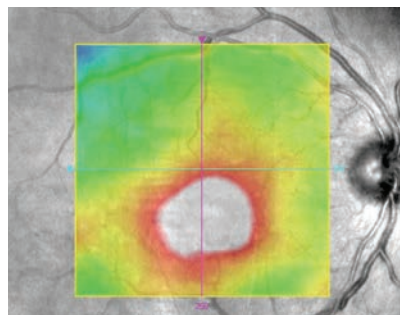
Better treatment options for DME give us more flexibility, but also more responsibility.

We need to use anti-VEGF prudently—if at all. **By Diana Shechtman, OD, and Jay M. Haynie, OD**

Diabetic macular edema (DME) contributes significantly to vision loss in diabetes patients and is the most common cause of vision loss among young adults. Previously, these patients were subjected to focal or grid laser photocoagulation. Although this method was effective in reducing vision loss by 50%, it was ineffective in restoring lost vision. All patients who participated in the original Early Treatment Diabetic Retinopathy Study (ETDRS) had visual acuity of 20/40 or worse.¹

Fortunately, management of DME has improved over the last decade and has increased the potential of visual restoration with the approval of anti-VEGF compounds Lucentis (ranibizumab, Genentech) and Eylea (aflibercept, Regeneron), and the off-label use of Avastin (bevacizumab, Genentech). Given the role inflammation plays in the development of DME, steroids have also become an effective option in DME management. Ozurdex (dexamethasone, Allergan) is a time-release intravitreal implant that emits a low dose of dexamethasone over 90 to 120 days. Another implant, Iluvien (fluocinolone acetonide, Alimera Sciences), the most recent therapy approved to treat DME, has an efficacy of up to 36 months. Focal or grid macular laser is also still used for clinically significant macular edema.

The ways we detect and define DME have evolved, too.



Figs. 1 and 2. This patient's center-involved DME (left) responded well to anti-VEGF (right).

Classification of DME is now based more on optical coherence tomography (OCT) images than funduscopy. The world of ophthalmology and retina in general is moving away from the classification of clinically significant macular edema (CSME), which primarily relied on funduscopic findings, and more towards spectral-domain OCT (SD-OCT) findings and retinal thickness. Now, DME is broken down into “center involved” (CI-DME) and “non-center involved” (NCI-DME) cases based on SD-OCT subfields.

These advances have given retina specialists and comanaging optometrists more options for management of DME—but also more room for doubt and debate regarding whether, when and how to intervene.

A Tale of Two Patients

By Dr. Haynie

Case 1. A 51-year-old white female presented for an evaluation with a six-month history of blurred vision in the right eye. Her medical

history includes hypertension and 12 years of Type 2 diabetes. Her medication history included metformin and glyburide for diabetes, and lisinopril for hypertension. Her best-corrected visual acuity measured 20/40 in the right eye and 20/20 in the left eye. The anterior segment exam was unremarkable, and she was phakic. Dilated examination revealed moderate nonproliferative diabetic retinopathy (NPDR) with multiple dot-blot hemorrhages and central macular thickening). SD-OCT confirmed CI-DME (Figure 1).

She was treated with serial anti-VEGF injections, variously using bevacizumab and aflibercept. She responded well, achieving resolution of the edema and a recovery in vision to 20/20 with stable OCT images (Figure 2).

This case may seem straightforward, and the retinal referral was considered both necessary and unremarkable. Now let's look at another case of DME and discuss how the referral and management may differ.



SMART SYSTEM[®] 2 20/20

NEW!

Give your
patients
the best

Call today
1/847-763-0500



Learn more about the Visual Acuity Testing System which includes the best USA-based customer service and technical support in the industry!

ACCURACY • RELIABILITY • REPEATABILITY

Experience the **NEW** All-in-One **Smart System[®] 2**. This state-of-the-art System delivers enhanced performance. Its sleek, compact appearance will streamline and innovate the look of your office.

50 Different Vision Tests, including VA, contrast, stereopsis, binocular balance and color vision.

Near, Intermediate and Distance Testing

DVD Functionality allows the user to play DVDs directly providing immediate fixation on retinoscopies.

Patient Education includes 26 pre-loaded patient education images with the flexibility for additional images and videos

Internal Marketing Load PowerPoint slides, images or videos to promote your practice and educate your patients.

LEA SYMBOLS[®] & LEA NUMBERS[®] The standard in testing children.

M&S
TECHNOLOGIES [®] The First Choice in Vision Testing Systems

Toll Free: 877-225-6101
mstech-eyes.com



M&S holds US Patents 7,354,155; 7,926,948; 8,425,040; 8,167,429; 8,419,184 & 8,550,631. Other Patents Pending.

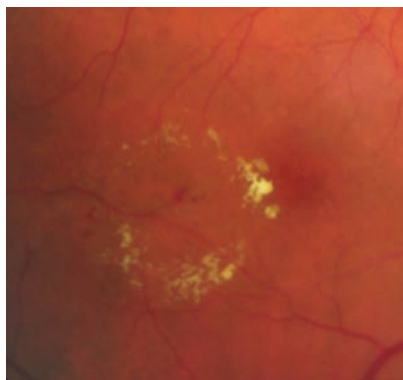


Fig. 3. Circinate lipid ring in case 2.

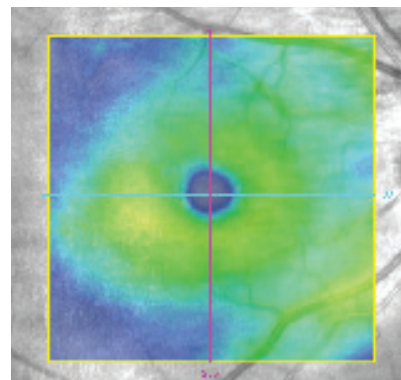
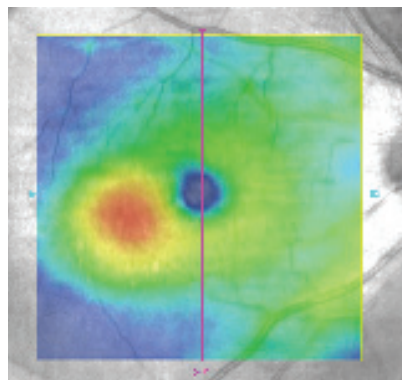
Case 2. This 68-year-old Native American female was referred for an evaluation of diabetic retinopathy and macular edema. She reported that her vision had been stable with no recent symptoms. Her medical history included Type 2 diabetes of 12 years' duration, hypertension and cardiac arrhythmia. Medications included glargine and metformin for diabetes, and amlodipine, metoprolol and clopidogrel for hypertension. Entering best-corrected visual acuity measured 20/25 in each eye. Anterior segment evaluation revealed grade 2 nuclear cataracts in each eye. Dilated fundus examination revealed mild NPDR in each eye with a circinate ring of lipid in the temporal macula of the right eye (Figure 3). SD-OCT imaging revealed NCI-DME with a normal foveal contour and thickness.

After a discussion of the available treatment options, including serial anti-VEGF intravitreal injections, she elected to observe rather than treat. After three months, the NCI-DME resolved and her vision was maintained at 20/25 in the right eye (Figures 4 and 5).

How Our Practice Compares

By Dr. Shechtman

Given that I practice in a retina clinic in South Florida, we are inundated with cases similar to the



Figs. 4 and 5. The macular edema (left) resolved without therapy at three months (right).

ones described above. The question of whether to treat or observe has become increasingly controversial. DME is dynamic and, as Dr. Haynie points out in case 2, may have the potential for resolution without intervention. Hence, it is critical to educate the patient about the importance of tight glycemic control.

Yet, many cases will progress and, if untreated, result in decreased visual acuity. Thus, all five surgeons at my practice would agree with the management of case 1. In the presence of decreased visual acuity (i.e., <20/25) and CI-DME, anti-VEGF therapy is initiated at our practice. Patients are often treated for about three months. If further assistance is necessary, we'll consider a steroid implant such as Ozurdex or Iluvien. Keep in mind that prior to the use of Iluvien, it is recommended to have the patient on a steroid challenge to minimize the potential of complications such as glaucoma.

Case 2 may not be as straightforward. In cases of NCI-DME with good visual acuity, we may observe but still evaluate for the presence of CSME as defined by the ETDRS (retinal thickening and hard, yellow exudates within 500µm of the foveal center and at least one disc area of thickening within one disc diameter of the foveal center). These cases often show increased focal macular

edema on the ETDRS retinal thickness OCT grid, but the increased thickness is not confined to the central area. In our practice, many cases defined as CSME may still benefit from focal laser. Yet, the management of each case is assessed on an individual basis.

Studies such as the Diabetic Retinopathy Clinical Research Network's Protocol V may in fact help us to better assess the efficacy of anti-VEGF therapy in cases where the visual acuity is 20/25 or better.² This study compares three approaches to management in patients with center-involved DME but good visual acuity: (1) prompt use of laser plus deferred anti-VEGF, (2) observation plus deferred anti-VEGF and (3) prompt use of anti-VEGF therapy.

Researchers hope the results will reveal how long anti-VEGF therapy can be deferred and the impact of observation or laser treatment in such cases. There is still debate as to the prompt use of anti-VEGF: does the benefit justify accepting the known risks, and what is the optimal number of injections needed to maintain vision? Hopefully, Protocol V's results will shed some light. ■

1. Early Treatment Diabetic Retinopathy Study Research Group. Early photocoagulation for diabetic retinopathy. ETDRS report number 9. *Ophthalmology*. 1991 May;98(5 Suppl):766-85.
2. Treatment for CI-DME in Eyes With Very Good VA Study (Protocol V). <https://clinicaltrials.gov/ct2/show/NCT01909791>. Accessed March 20, 2018.

Technology in balance



Health



Vision




Comfort

Miru 1month: a unique family of silicone hydrogel monthly lenses.

Coming Spring 2018

MeniSilk™ and Nanogloss™ technologies designed to meet the demands of today's contact lens wearer.*



Material and surface technologies

MeniSilk™

- Ultra high Dk/t - 161 @ -3.00D
- Exceptional hydration
- Optimized transparency

Nanogloss™

- Super smooth surface
- Resistance to bacteria
- Excellent wettability



www.meniconamerica.com

*Menicon data on file April 2016



FRONTLINE OCULAR SURFACE DISEASE CARE

A contemporary approach to dry eye using early detection and proactive intervention to slow the cascade of disease.

*By Paul M. Karpecki, OD, FAAO; Lyndon Jones, PhD, FCOptom, FAAO;
Kelly K. Nichols, OD, MPH, PhD, FAAO; Leslie O'Dell, OD, FAAO*

Dry eye, as we understand it today, is entirely different than it was 20—or even 10—years ago. Of course, the disease itself has not changed, but our understanding of it has. As a result, we can now offer our patients comfort, relief, improved ocular health, better vision and a quality of life that we struggled in vain to attain just a few years ago.

Thanks to tremendous amounts of clinical research and the compilation of that research in the recently published Tear Film and Ocular Surface Society (TFOS) Dry Eye Workshop (DEWS) II reports, anyone practicing optometry can make this specialty as fundamental to primary care as a dilated fundus exam. As you'll discover in this

continuing education program, you don't need expensive equipment to provide high-quality, comprehensive ocular surface care. New technology makes it easier in higher-volume settings and in clinics that want to build a strong dry eye specialty presence, but by no means is this necessary. However, a current understanding of dry eye is essential. This is what TFOS DEWS II offers.

The following discussion breaks down these extensive reports into an easy-to-follow, five-step process. As you will learn, a contemporary approach to dry eye involves early detection and proactive intervention to slow the cascade of disease. This is in stark contrast to the old approach, when we would watch-and-wait for identifiable

Release Date: April 15, 2018

Expiration Date: December 31, 2018

Goal Statement: Upon completing this educational activity, optometrists should have increased knowledge about research from the recent DEWS II report that redefines DED and further illuminates its pathophysiology, and new strategies for diagnosing and managing the disease and its inflammatory response in order to provide patients with the highest level of care.

Faculty/Editorial Board: Lyndon Jones, PhD, FCOptom, FAAO; Paul M. Karpecki, OD, FAAO; Kelly Nichols, OD, MPH, PhD, FAAO; Leslie O'Dell, OD, FAAO

Credit Statement: This course is COPE approved for 2 hours of CE credit. COPE ID is **56784-AS**. Please check your state licensing board to see if this approval counts toward your CE requirement for relicensure.

Joint-Sponsorship Statement: This continuing education course is joint sponsored by the University of Alabama School of Optometry.

Disclosure Statement: **Dr. Jones** is a consultant for Alcon, CooperVision and J&J Vision; and a principal investigator for Alcon, Allergan, CooperVision, GL Chemtech, J&J Vision, Nature's Way, Novartis, Santen and Shire Pharmaceuticals.

Dr. Nichols is a consultant for Bruder Healthcare Company, InSite Vision, Parion Pharmaceuticals, SARcode Bioscience, Shire Pharmaceuticals, Sun Pharmaceuticals, Kala Pharmaceutical, Eleven Biotherapeutics, Science Based Health, Allergan, Santen Pharmaceutical.

Dr. Karpecki is a consultant for Aerie Pharmaceuticals, Alcon, Abbott Medical Optics, Akorn, Allergan, Anthem Bausch + Lomb, Bio-Tissue, BlephEx, Beaver-Visitec, Bruder Healthcare, Cambium Pharma, Essilor, Eyes4Lives, Focus Labs, Glaukos, iCare USA, Imprimis Pharmaceuticals, J&J, Konan Medical, Maculogix, Oasis, Ocular Therapeutix, Oculus, OcuSoft, Regeneron, SightRisk, Reichert, Shire Pharmaceuticals, Science Based Health, Smart Vision Labs, TearScience, Topcon, TLC Vision, Vision Care Inc., Vmax and Visiometrics; a research grant principal investigator for Eleven BioTherapeutics, Fera Pharmaceuticals, Shire Pharmaceuticals; has received honoraria for the speaker's bureaus of Glaukos and Oculus; is director/clinical advisor for Optometric Medical Solutions; and is on the board of directors for TearLab.

Dr. O'Dell is a consultant to Eye Eco and Shire Pharmaceuticals; and is a speaker for Allergan, Shire and Genzyme.

Supported by: An unrestricted educational grant from Shire.

Administered by
Review of Optometry®



Supported by an unrestricted
educational grant from
Shire

signs of moderate to late-stage disease. Our current approach to more advanced cases is also very different today than it was a few years ago, because we now have a better understanding of effective strategies to quell disease and safeguard the ocular surface, lids and meibomian glands from further compromise. All of this is good news for patients and great news for the doctors on the frontlines who encounter this complex disease all day, every day.

STEP ONE: TRIAGE

Dr. Karpecki: *TFOS DEWS II lays out a very structured and methodical way of getting to the bottom of dry eye disease.³ From a practical perspective, in most offices, this would begin when the patient first checks in at your office. The recommendation of the Diagnostic Committee is to begin with a set of triaging questions. Do you find this helpful in terms of practice flow and identifying dry eye?*

Dr. O'Dell: I find it very helpful. The recommended triaging questions save a lot of time, error and oversight.

Dr. Karpecki: *Which questions do you find most useful?*

Dr. O'Dell: I find, "How long have your symptoms lasted and was there any triggering event?" the most beneficial. Most times, a dry eye patient has a gradual onset of symptoms. They can't say that everything went wrong on Sept 28th. But when you have a patient who can pick the exact day, you're onto something you may never have otherwise discovered. Sometimes, you'll find that patients you thought had dry eye in fact have recurrent corneal erosion or epithelial basement membrane dystrophy. The other big time-saver is, "Are the symptoms or any redness much worse in one eye than the other?" Having this information before you step into the exam room is incredibly valuable.

THE BIRTH OF A NEW DEFINITION FOR DRY EYE

The revised definition of dry eye that was created by TFOS in the TFOS DEWS II report states: "Dry eye is a multifactorial disease of the ocular surface characterized by a loss of homeostasis of the tear film, and accompanied by ocular symptoms, in which tear film instability and hyperosmolarity, ocular surface inflammation and damage, and neurosensory abnormalities play etiological roles."¹

This definition is different from the original TFOS DEWS definition in meaningful ways.² It was important to this subcommittee that the definition has international relevance. A lot of time was spent talking about individual words and how they would translate in different languages.

Next, important terms were identified. For example, it's important that dry eye is recognized as a disease because this suggests that there must also be diagnostic and management criteria, whereas a syndrome might be viewed as simply a nuisance. "Multifactorial" is another important term that puts dry eye into clearer perspective. However, the words the committee focused on most were "loss of homeostasis." This is new to the definition. It was included because we know that there are things about dry eye that we can't yet grasp, but the term "loss of homeostasis" is an umbrella term that accounts for these unknowns. As such, this new definition may not need to be changed for quite some time.

The new definition also recognizes that symptoms are important but don't need to be specifically defined, since they present in many different ways and affect comfort and/or vision to varying degrees.

Finally, the latter part of the definition reflects our current knowledge of the etiological pathways, but leaves an opening for what we might learn in the future. For example, neurosensory abnormalities were included in the new definition as a direct result of a preponderance of new research in that area.

Panel Participation in Tear Film and OcularSurface Society (TFOS) Dry Eye Workshop II (DEWS II) Report



Dr. Karpecki: TFOS Diagnostic Methodology Subcommittee member and TFOS Global Ambassador



Dr. Nichols: Co-chair of the TFOS Definition and Classification Subcommittee and Steering Committee member

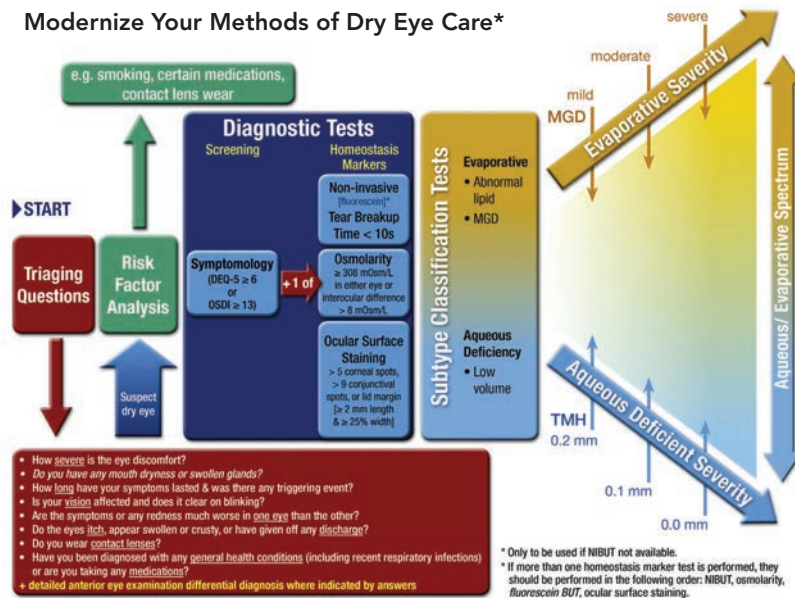


Dr. Jones: TFOS Treatment and Management Subcommittee Chair and Steering Committee member



Dr. O'Dell: TFOS Public Awareness and Education Subcommittee member and TFOS Global Ambassador

Modernize Your Methods of Dry Eye Care*



*Adapted and reprinted from Ocular Surface (2017) 544–579, Wolffsohn JS, Arita R, Chalmers, R, et al. TFOS DEWS II diagnostic methodology report, p. 561, © 2017, with permission from Elsevier.

TFOS DEWS II TRIAGING QUESTIONS³

- How severe is the eye discomfort?
- Do you have any mouth dryness or swollen glands?
- How long have your symptoms lasted and was there any triggering event?
- Is your vision affected and does it clear on blinking?
- Are the symptoms or any redness much worse in one eye than the other?
- Do the eyes itch, appear swollen or crusty, or have they given off any discharge?
- Do you wear contact lenses?
- Have you been diagnosed with any general health conditions (including recent respiratory infections) or are you taking any medications?

STEP TWO: RISK FACTOR ANALYSIS

Dr. Karpecki: The second step, after triaging questions, is risk factor analysis. Risk factors for dry eye include the patient's environment, smoking, medications, contact lens wear, ocular surgery and systemic disease and others. Do any of these stand out as areas that require a change in approach?

Dr. Jones: Depending on what study you're reading, broadly speaking, roughly 50% of patients who wear contact lenses complain of dryness and discomfort toward the end of the day. The problem is that many practitioners are either numb to these complaints or try to solve the issue by spending an inordinate amount of time switching lens materials and solutions and flip-flopping between different ones. What we're overlooking when we do this is that you can have the best contact lens material and the best contact lens solution in the world, but these strategies

aren't going to work well if you've got a patient whose ocular surface is damaged. We need to address the ocular surface before we start making other changes in contact lens wearers. Looking for meibomian gland dysfunction and Demodex is a great place to start in any symptomatic contact lens wearer. Always look for those two things before changing anything else. Then, if you still need to change the lens, the previous TFOS report on contact lens discomfort offers adequate evidence to support switching to a daily disposable modality.⁴

Dr. Karpecki: Moving on to medications, what role do glaucoma drops play in terms of being a risk factor for dry eye disease?

Dr. O'Dell: Topical glaucoma therapy creates ocular surface disease, so we need to screen these patients, whether or not they're complaining about their drops burning or end-of-the-day discomfort. Many patients require multiple medications to control their disease, which increases their dry eye symptoms

exponentially. Fortunately, we are starting to see a paradigm shift in the way we manage glaucoma, with the introduction of alternative preservatives, preservative-free options and first-line surgical options including selective laser trabeculoplasty (SLT) and minimally invasive glaucoma surgery (MIGS).

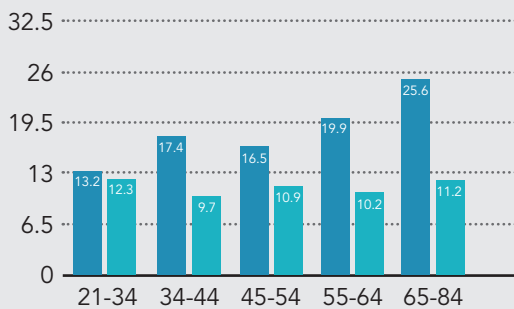
Dr. Karpecki: Are you seeing dry eye at an earlier age?

Dr. O'Dell: Absolutely. Future research needs to take a closer look at what's happening in the under-40 crowd. Everyone is staring at screens, including young children. Consider the effects of this over time.

Dr. Karpecki: Indeed, we're starting to see those effects even now. We're all familiar with the original Beaver Dam research, but when researchers looked at the participants' offspring in the Beaver Dam Offspring Study (BOSS), they discovered that the incidence of dry eye in the patients between age 21 and 34 was about 13%, which is about the same incidence

DRY EYE IN THE BEAVER DAM OFFSPRING STUDY*

DED prevalence is similar in both younger and older age groups.



* Paulsen AJ, Cruickshanks KJ, Fischer ME, et al. Dry eye in the beaver dam offspring study: Prevalence, risk factors, and health-related quality of life. *Am J Ophthalmol.* 2014 Apr;157(4):799-806.

as their parents.⁵ That's a pretty high number. Does it strike you as unrealistic?

Dr. Jones: It doesn't surprise me at all. In our clinics at the University, the number of patients who report symptoms has definitely increased because of this digital world—even when patients are not wearing their lenses. Digital device use reduces blink rate, which increases evaporation, which in turn is leading to an increase in symptoms. The take-home message here is that you need to routinely ask patients of all ages whether they are suffering from symptoms of dry eye. This includes the whole under-40 crowd, including kids.

Dr. Nichols: It's also important to look at the young people in your practice and think about prevention, because if they're showing signs in their 20s, imagine what they're going to be living with when they are 50, 60 or 70 years old. We need to try and halt progression and prevent dry eye from emerging in the first place.

Dr. Jones: Many kids also are at much greater risk due to acne medications, such as isotretinoin derivatives. This is commonly prescribed and can cause brutal dry eyes, dry mouth and dry skin.

Dr. O'Dell: Acne medications aren't the only culprits. Some of the acne face washes have been linked to keratitis. There's still a lot to learn about the chemicals in cosmetics including soaps, shampoos, lotions and face wash. Our patients are being exposed to these products every day without knowing the residual effects to the ocular surface.

Dr. Karpecki: Why specifically are we still seeing a predilection after age 35 towards women?

Dr. O'Dell: I learned so much from the TFOS DEWS

II Sex, Gender, and Hormones Committee.⁶ First, to clarify terms, "sex" refers to your biological makeup, and "gender" relates to what the environment does to influence your behavior. In both male and female patients, the level of hormones and androgens in every part of the lacrimal system—from meibomian glands to the lacrimal gland to the accessory glands—is unique based on sex. In post-menopausal patients especially, androgens play an enormous role.

STEP THREE: DIAGNOSTIC TESTS

Dr. Karpecki: Step three is diagnostic testing, which includes a symptomology screening questionnaire plus at least one of three diagnostic tests to measure homeostasis. Do you rely heavily on a particular dry eye questionnaire?

Dr. Nichols: We tend to use the Ocular Surface Disease Index (OSDI) because it provides a great benchmark, and has excellent reliability and validity, and good sensitivity and specificity.⁷ If you choose to ask more questions yourself, you don't need a survey, but if you are pressed for time, as most doctors are, the detailed surveys allow you to see other patients while you collect critical information.

Dr. Jones: Asking about symptomology using a questionnaire is very helpful for diagnosis. It's also great for management because it gives you a benchmark, so when you do begin therapy you can reliably measure any shift that occurs.

Dr. Nichols: And these two are selected because they've been validated or have shown a shift with treatments. And so, you're right. If you don't see any change at all, maybe you need to approach your management structure a bit differently.

Dr. Karpecki: That's an excellent point. Like OSDI, the Dry Eye Questionnaire-5 (DEQ-5) and the SPEED questionnaire also offer a score, which helps in diagnosis and later in terms of management so you know whether or not your treatment plan is working.⁸

Dr. Karpecki: The list of dry eye symptoms is long. It includes burning, stinging, transient blur, dryness, photophobia, epiphora, blurred vision, contact lens intolerance, injection, increased blink rate, foreign body sensation and grittiness. Among these, is there any area that you're starting to look more closely at in recent years?

Dr. O'Dell: I'm taking a more serious look at increased blink rate because it leads to a vicious cycle of inflammation that's hard to break, even with today's topical therapies. In some cases, we've had to use botulinum toxin injections to slow the blinking. But even

this is tricky because if you slow it too much you can cause even more dry eye. I often first notice blink rate issues at the slit lamp when patients appear to be overly photophobic during the exam.

Dr. Nichols: I agree. I also elicit information on blink problems by asking patients whether they stop and close their eyes during a work day or at the end of the day. Many patients—especially contact lens wearers—say their eyes are tired and they need to blink a lot to try and clear the vision. The visual parts of the symptomatology are central to how I gather meaningful information about dry eye. These patients generally think there's something wrong with their prescription when, in fact, it has more to do with blinking too much. The body is trying to maintain adequate tear breakup on an unstable tear film.

Dr. Karpecki: After screening, the three tests identified in the TFOS DEWS II report for measuring homeostasis are non-invasive tear breakup time, osmolarity or ocular surface staining testing. Which of these do you perform?

Dr. Nichols: The guidelines point out that you only need to perform one of these, but we often do all of them.

STEP FOUR: SUBTYPE CLASSIFICATION

Dr. Karpecki: After your screening and symptomatology review, the TFOS DEWS II guidelines call for subtype classification testing. In other words, is the dry eye primarily evaporative or is it mostly aqueous

deficient? It's often mixed, but the new guidelines suggest looking at that scale and determining the severity of each subtype to figure out where the patient is on the dry eye spectrum. What is the benefit of going through this classification exercise? Does it offer a better explanation about why signs and symptoms don't always correlate?

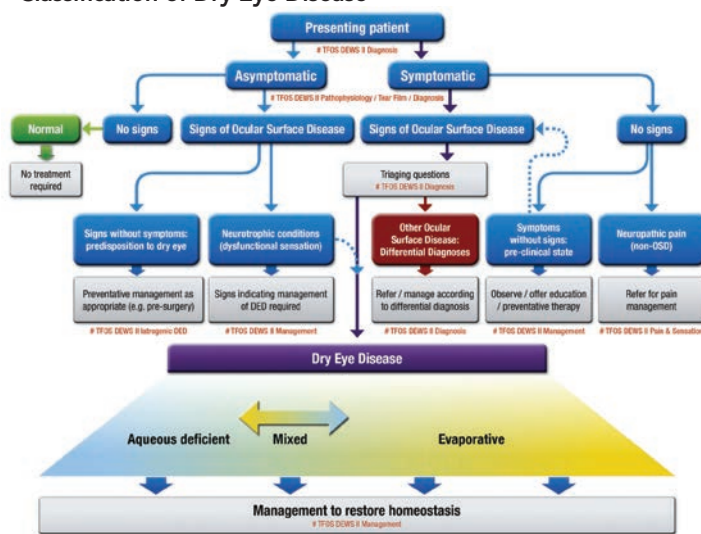
Dr. Nichols: This is where I think we stopped short in previous definitions. DEWS II offers a new classification scheme that makes it clear that dry eye isn't either aqueous deficient or evaporative. It is often a combination of both, occurring on a sliding scale, which makes it necessary to treat both.

Dr. Karpecki: What is your testing protocol?

Dr. Nichols: You have to look at the meibomian glands and tear volume. There are many high- and low-tech ways to test for evaporative vs. aqueous deficient dry eye. Taking a thorough look and taking your findings seriously are what matters. For example, if you see only one isolated blocked gland in a contact lens patient, don't ignore it. Treat it because this patient is on a road to a place they don't want to go. They already have disease.

Dr. Jones: It is worthwhile reading the entire TFOS DEWS II report, but if you had to read just one part, it would be the diagnostic report. It dissects every single dry eye test that could or should be done in succinct detail. When you see it put together like this, you realize that this isn't rocket science. Every single one of us can do this using readily accessible tools.

Classification of Dry Eye Disease*



In the figure to the left, the upper portion represents a clinical decision algorithm, beginning with the assessment of symptoms and followed by review for signs of ocular surface disease. DED exhibits both symptoms and signs, and can be differentiated from other ocular surface disease with the use of triaging questions and ancillary testing. It is to this DED group that diagnostic subtyping, and conventional dry eye management strategies, apply. The lower portion of the figure represents the etiological classification of DED and highlights the two predominant and non-mutually exclusive categories: aqueous deficient dry eye (ADDE) and evaporative dry eye (EDE).

*Adapted and reprinted from Ocular Surface (2017) 276–283, Craig JP, Nichols KK, Nichols JJ, et al. TFOS DEWS II definition and classification report, p. 281, © 2017, with permission from Elsevier.

STEP FIVE: TREATMENT

Dr. Karpecki: *Once you know what you're trying to combat, treatment becomes much more straightforward. But have we reached the point where we can pick a single treatment based on our diagnostics and know it's going to be the silver bullet?*

Dr. Jones: One of the biggest challenges for the Management and Therapy Committee was grouping the incredibly diverse list of therapies and suggesting when to use them. To give you an idea of how much research there is on this topic, the Management and Therapy Committee report has 1,002 references.⁹ What we found was that one treatment alone often doesn't work. Instead, you may need to mix and match a few things. To simplify this process, the committee developed a four-step process, progressing from the simplest therapies to the more complex. (See *TFOS DEWS II Staged Management and Treatment Recommendations*).

Dr. Nichols: Indeed, the Management and Therapy section is not the cookbook that we may wish it could be, but it provides a level of evidence that puts us on the right path. One outcome that we hope for most as a result of this report is that it will be a call to action, inspiring more head-to-head studies that will help us select those silver bullets.

Dr. Karpecki: In the meantime, one thing we do know about dry eye is that inflammation needs to be addressed at every level.

Dr. Jones: That's very true. By definition, dry eye has an inflammatory component. It's worthwhile bearing in mind that many of our mildly symptomatic patients have low levels of inflammatory response that now we can effectively manage at this earlier stage, getting them out of the vicious cycle of the inflammatory response that precipitates further damage to the ocular surface, more tear film break-up time and more inflammation. You've got to get in there and break that cycle.

ACT SOONER RATHER THAN LATER

Dr. Karpecki: *A recent study looked at patients preparing for cataract surgery. The patients who had osmolarity scores within normal limits were within a half diopter of intent, whereas 17% of those with hyperosmolarity would have missed their IOL calculation by more than a diopter.¹⁰ What is your protocol for cataract surgery candidates?*

Dr. Jones: You should always aim to have a primed, pristine optical surface before referring a patient for

TFOS DEWS II STAGED MANAGEMENT & TREATMENT RECOMMENDATIONS

Step 1:

- Education regarding the condition, its management, treatment and prognosis
- Modification of local environment
- Education regarding potential dietary modifications (including oral essential fatty acid supplementation)
- Identification and potential modification/elimination of offending systemic and topical medications
- Ocular lubricants of various types (if MGD is present, consider lipid-containing supplements)
- Lid hygiene and warm compresses of various types

Step 2:

If above options are inadequate, consider:

- Non-preserved ocular lubricants to minimize preservative-induced toxicity
- Tea tree oil for Demodex (if present)
- Tear conservation
- Punctal occlusion
- Moisture chamber spectacles/goggles
- Overnight treatments (such as ointment or moisture chamber devices)
- In-office, physical heating and expression of the meibomian glands (including device-assisted therapies, such as LipiFlow [TearScience])
- In-office intense pulsed-light therapy for MGD
- Prescription drugs to manage DED
- Topical antibiotic or antibiotic/steroid combination applied to the lid margins for anterior blepharitis (if present)
- Topical corticosteroid (limited duration)
- Topical secretagogues
- Topical non-glucocorticoid immunomodulatory drugs (such as cyclosporine)
- Topical LFA-1 antagonist drugs (such as lifitegrast)
- Oral macrolide or tetracycline antibiotics

Step 3:

If above options are inadequate, consider:

- Oral secretagogues
- Autologous/allogeneic serum eye drops
- Therapeutic contact lens options
- Soft bandage lenses
- Rigid scleral lenses

Step 4:

If above options are inadequate, consider:

- Topical corticosteroid for longer duration
- Amniotic membrane grafts
- Surgical punctal occlusion
- Other surgical approaches (e.g., tarsorrhaphy, salivary gland transplantation)

Adapted and reprinted from *Ocular Surface* (2017) 580–634, Jones L, Downie LE, Korb D, et al. *TFOS DEWS II management and therapy report*, p. 615, © 2017, with permission from Elsevier.

cataract surgery. Especially if you have a patient who demonstrates an interest in a multifocal or other pre-

mium IOL, you have to make sure that the ocular surface is healthy. It makes a big difference.

Dr. O'Dell: If I have a patient that I'm sending out for cataract surgery, I always have them come back for a dry eye evaluation with me before they go to the cataract surgeon so I can start therapy several weeks before it's time for surgery.

Dr. Karpecki: Dry eye disease is a chronic, progressive disease that affects millions of people, yet too often it is approached as a mere nuisance, as evidenced by the fact that so few people are receiving medical treatment.^{5,11} It's encouraging that there appears to be a growing commitment to action, at least before surgery.

Dr. Nichols: That's true, but the next step needs to be acting sooner rather than later. Our changing environment and increased dependence on digital technology only adds to this growing problem, making intervention and prevention that much more critical to sustained qual-

ity of life as patients age. ■

1. Craig JP, Nichols KK, Akpek EK, et al. TFOS DEWS II Definition and Classification Report. *Ocul Surf.* 2017 Jul;15(3):276-83.
2. The definition and classification of dry eye disease: Report of the definition and classification subcommittee of the international dry eye workshop (2007). *Ocul Surf.* 2007;5(2):75-92.
3. Wolffsohn JS, Arita R, Chalmers R, et al. TFOS DEWS II Diagnostic Methodology report. *Ocul Surf.* 2017 Jul;15(3):539-74.
4. Jones L, Brennan NA, Gonzalez-Meijome J, et al: The TFOS International Workshop on Contact Lens Discomfort: report of the contact lens materials, design, and care subcommittee. *Invest Ophthalmol Vis Sci* 2013; 54: TFOS37-70.
5. Paulsen AJ, Cruickshanks KJ, Fischer ME, et al. Dry eye in the beaver dam offspring study: Prevalence, risk factors, and health-related quality of life. *Am J Ophthalmol.* 2014 Apr;157(4):799-806.
6. Sullivan DA, Rocha EM, Aragona P, et al. TFOS DEWS II Sex, Gender, and Hormones Report. *Ocul Surf.* 2017 Jul;15(3):284-333.
7. Schiffman RM, Jacobsen CG, Hirsch J, et al. Reliability and validity of ocular surface disease index. *Arch Ophthalmol.* 2000 May;118(5):615-21.
8. Chalmers RL, Begley CG, Caffery B. Validation of the 5-item dry eye questionnaire (DEQ-5): Discrimination across self-assessed severity and aqueous tear deficient dry eye diagnoses. *Cont Lens Anterior Eye.* 2010 Apr;33(2):55-60.
9. Jones L, Downie LE, Korb D, et al. TFOS DEWS II Management and Therapy Report. *Ocul Surf.* 2017 Jul;15(3):575-628.
10. Epitropoulos AT, Matossian C, Berdy GJ, et al. Effect of tear osmolarity on repeatability of keratometry for cataract surgery planning. *Journal Cataract Refract Surg.* 2015 Aug;41(8):1672-7.
11. Gayton JL. Etiology, prevalence, and treatment of dry eye disease. *Clin Ophthalmol.* 2009;3:405-12.

CE TEST

To obtain two hours of continuing education credit, complete the exam by recording the best answer to each self-assessment question online

at: <https://www.reviewofoptometry.com/ce/frontline-ocular-surface-disease-care-march18>

Or, mail the Examination Answer Sheet on the next page to: Jobson Medical Information, Dept.: Optometric CE, 440 9th Avenue, 14th Floor, New York, NY 10001. A minimum score of 70% is required to obtain a certification of completion. The fee for this course is free.

1. TFOS DEWS II refers to dry eye as a _____.

- a. Syndrome
- b. Disease
- c. Nuisance
- d. None of the above

2. The TFOS DEWS II revised definition of dry eye disease includes the following: "Dry eye is a multifactorial disease of the ocular surface characterized by a loss of _____ of the tear film and accompanied by ocular symptoms..."

- a. Equilibrium
- b. Homeostasis
- c. Balance
- d. Equanimity

3. The following is a true statement about the TFOS DEWS II definition of dry eye?

- a. Symptoms must be specifically defined
- b. Symptoms are unimportant
- c. Symptoms affect comfort and/or vision to varying degrees
- d. None of the above

4. The Beaver Dam study found that the incidence of dry eye in the patients between age 21 and 34 was about _____.

- a. 4
- b. 11

- c. 13
- d. 24

5. In what demographic population should you routinely ask patients whether they are suffering from symptoms of dry eye?

- a. Individuals under 40 years of age
- b. Women over 40
- c. Men over 40
- d. All of the above

6. What is a true statement when classifying patients into types of dry eye disease?

- a. Patients can't be diagnosed with both aqueous deficient dry eye and evaporative dry eye simultaneously
- b. Many patients have some element of both aqueous deficient dry eye and evaporative dry eye
- c. Patients with aqueous deficient dry eye always exhibit more signs and symptoms than those with evaporative dry eye
- d. Patients with evaporative dry eye exhibit more signs and symptoms than those with aqueous deficient dry eye

7. What aspect of glaucoma might contribute to increasing the risk for ocular surface disease?

- a. Higher intraocular pressure
- b. Visual field loss
- c. Topical therapies that use preservatives
- d. MIGS procedures

8. Though the TFOS DEWS II report left symptoms open, what common symptoms of dry eye do patients often present with?

- a. Increased blink rate
- b. Blur
- c. Drooping lids
- d. A and B

9. The TFOS DEWS II Diagnostic Committee set forth the need to first begin asking patients _____ questions to help an eye care practitioner make an assessment

about whether a patient might have dry eye disease and the type.

- a. Trick
- b. Triaging
- c. Undercover
- d. Rapid-fire

10. The TFOS DEWS II report recommended which of the following diagnostic tests as homeostasis markers?

- a. Noninvasive tear break-up time
- b. Osmolarity
- c. Ocular surface staining
- d. All of the above

11. The TFOS DEWS II report suggested that, to classify subtypes of dry eye disease into evaporative and aqueous deficiency, it is important to investigate abnormal lipids as well as possible _____.

- a. Ocular hypertension
- b. Corneal abrasions
- c. Meibomian gland dysfunction
- d. Retinal tears

12. Expressing the meibomian glands and assessing tear volume can especially help with what aspect of dry eye diagnosis?

- a. Differentiating signs from symptoms
- b. Differentiating symptoms from signs
- c. Differentiating the type of dry eye
- d. Determining the severity of dry eye

13. Which of the following triaging questions is recommended?

- a. Do you have any mouth dryness or swollen glands?
- b. How long have your symptoms lasted and was there any triggering event?
- c. Are the symptoms or any redness much worse in one eye than the other?
- d. All of the above

14. What commonly prescribed medication puts kids at

CE TEST

risk of developing dry eye disease?

- a. Amoxicillin
b. Azithromycin
c. Isotretinoin derivatives
d. Ibuprofen

15. What was one of the biggest challenges for the TFOS DEWS II Management and Therapy Committee in preparing recommendations for the report?

- a. Large number of management and therapy options available
b. Lack of management and therapy options available
c. Unwillingness of doctors to utilize available management and therapy options available
d. Lack of patient access to management and therapy options available

16. How many steps did the Management and Therapy Committee come up with as eye care practitioners progress through from the simplest therapies through to the more complex?

- a. 3
b. 4
c. 5
d. 6

17. What is a true statement about the four therapeutic steps?

- a. The steps are unchangeable
b. The steps should not be customized to the patient
c. They're not mutually exclusive
d. They are mutually exclusive

18. Step 1 includes which of the following recommendations:

- a. Education on dry eye, and environmental and dietary modifications
b. Identification and potential modification of offending medications
c. Various types of ocular lubricants, lid hygiene and warm compresses
d. All the above

19. Step 2 prescribes which possible strategies if Step 1 approaches are inadequate:

- a. Non-preserved ocular lubricants, tea tree oil for Demodex (if present) and tear conservation (punctal occlusion and moisture chamber spectacles/goggles)
b. Overnight treatments (such as ointment or moisture chamber devices); in-office physical heating and expression of the meibomian glands, as well as intense pulsed light therapy for MGD
c. Prescription drugs including topical antibiotics/or steroid combinations for lid margins if blepharitis is present; topical corticosteroids, non-glucocorticoid immunomodulatory drugs and LFA-1 antagonists; and oral macrolide or tetracycline antibiotics
d. All the above

20. What strategies are not mentioned in Step 3 for dry eye that is nonresponsive to therapy?

- a. Amniotic membrane treatment and scleral lenses
b. Intraocular lenses
c. LASIK procedures
d. B and C

The opinions expressed in this supplement to Review of Optometry do not reflect the views of or imply endorsement by the publisher of the host publication. Copyright 2018 Jobson Medical Information LLC.

Examination Answer Sheet

Valid for credit through December 31, 2018

This exam can be taken online at:

https://www.reviewofoptometry.com/ce/frontline-ocular-surface-disease-care-march18

Upon passing the exam, you can view your results immediately and download a real-time CE certificate. You can also view your test history at any time from the website.

Frontline Ocular Surface Disease Care

Directions: Select one answer for each question in the exam and completely darken the appropriate circle. A minimum score of 70% is required to earn credit.

Mail to: Jobson Medical Information, Dept.: Optometric CE, 440 9th Avenue, 14th Floor, New York, NY 10001.

COPE approved for 2 hours of CE credit. COPE ID is 56784-AS.

This course is supported by an unrestricted educational grant from Shire.

There is an eight- to 10-week processing time for this exam.

- 1. Rate how well the activity supported your achievement of these learning objectives: 1=Poor, 2=Fair, 3=Neutral, 4=Good, 5=Excellent
21. Improved my knowledge about the latest research about ocular surface and dry eye disease in the United States
22. Learned about some of the risk factors for ocular surface and dry eye disease from the TFOS DEWS II report
23. Became familiar with some of the TFOS DEWS II report's findings about dry eye disease, including its new definition and detection of the disease
24. Better understood the TFOS DEWS II report's recommendations for diagnosis, and treatment and management of dry eye disease
25. Obtained a basic understanding about strategies to classify the type of dry eye disease (i.e., aqueous deficient dry eye and evaporative dry eye)
26. Gained basic knowledge about the obstacles of differential diagnosis for dry eye disease
27. The content was evidence-based.
28. The content was balanced and free of bias.
29. The information presented was clear and effective.
30. Additional comments on this course:

Please retain a copy for your records. Please print clearly.

You must choose and complete one of the following three identifier types:

1 SS # [] - [] - []
Last 4 digits of your SS # and date of birth State Code and License #: (Example: NY12345678)
2 [] - [] - [] - []
3 [] - [] - [] - []
First Name []
Last Name []
E-Mail []
The following is your: Home Address Business Address
Business Name []
Address []
City [] State []
ZIP []
Telephone # [] - [] - []
Fax # [] - [] - []

By submitting this answer sheet, I certify that I have read the lesson in its entirety and completed the self-assessment exam personally based on the material presented. I have not obtained the answers to this exam by any fraudulent or improper means.

Signature _____ Date _____

Know Your Systemic Meds: The Top 10 to Track

Here's what you need to know about the ocular effects of the heavy-hitters.

By Megan Hunter, OD, and Michelle Marciniak, OD

While systemic medications are often necessary for the patient's long-term health, ocular side effects, as minor as dry eye and as serious as macular toxicity, can challenge the treatment process, often leading to modification or even discontinuation of the medication.

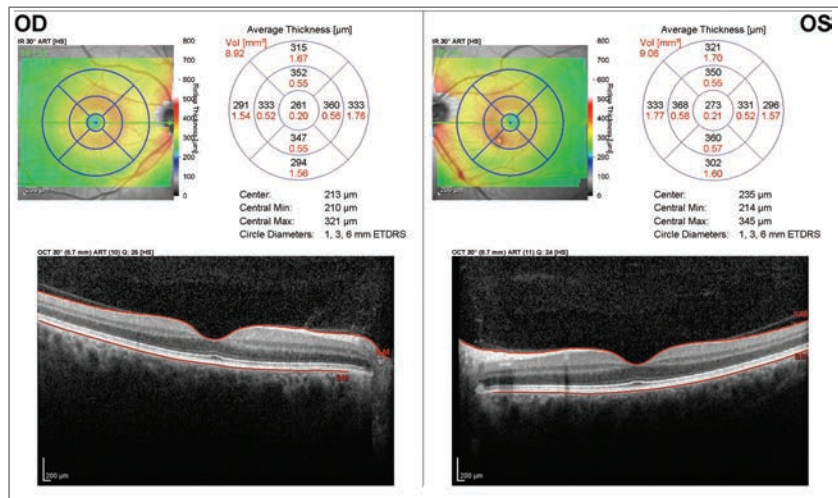
Optometrists must be prepared to manage and comanage patients who present with concurrent medication use and ocular concerns. Here, we discuss some of the commonly prescribed systemic medications with serious ocular side effects, and what to look out for.

Hydroxychloroquine

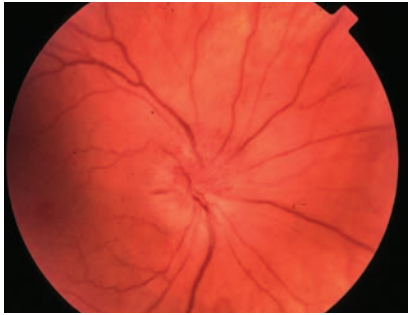
In the United States, Plaquenil (hydroxychloroquine, Sanofi-Aventis) is commonly used to treat rheumatic conditions such as rheumatoid arthritis, systemic lupus erythematosus and Sjögren's syndrome. Plaquenil use has the potential risk of retinal toxicity.¹ Overall, the incidence is low; however, risk depends on the length of therapy and cumulative dosage. After five years of use, the risk of toxicity is <1%, but increases to 2% after 10 years and nearly 20% after 20 years.¹ The underlying pathophysiology of the toxicity is not well understood, although researchers do know that Plaquenil affects

the metabolism of retinal cells, including the photoreceptors.² Since the toxicity predominately affects the macula, light absorption, cone metabolism or both may play a role.³ Hydroxychloroquine binds to melanin, which concentrates in the retinal pigment epithelium and prolongs the effects, even after discontinuation of the medication. Tamoxifen use and renal disease can also result in increased risk.

Optometrists must screen patients taking Plaquenil for early functional and structural changes associated with toxicity, because once a clinically evident bull's



This SD-OCT of a patient taking 400mg of Plaquenil daily shows no signs of maculopathy, as each eye's inner/outer segment line is intact.



NAION, seen here, has been linked to the use of PDE 5 inhibitors.

eye maculopathy is present, the damage cannot be reversed.³ The current American Academy of Ophthalmology (AAO) recommendations advise screening with objective test for functional retinal

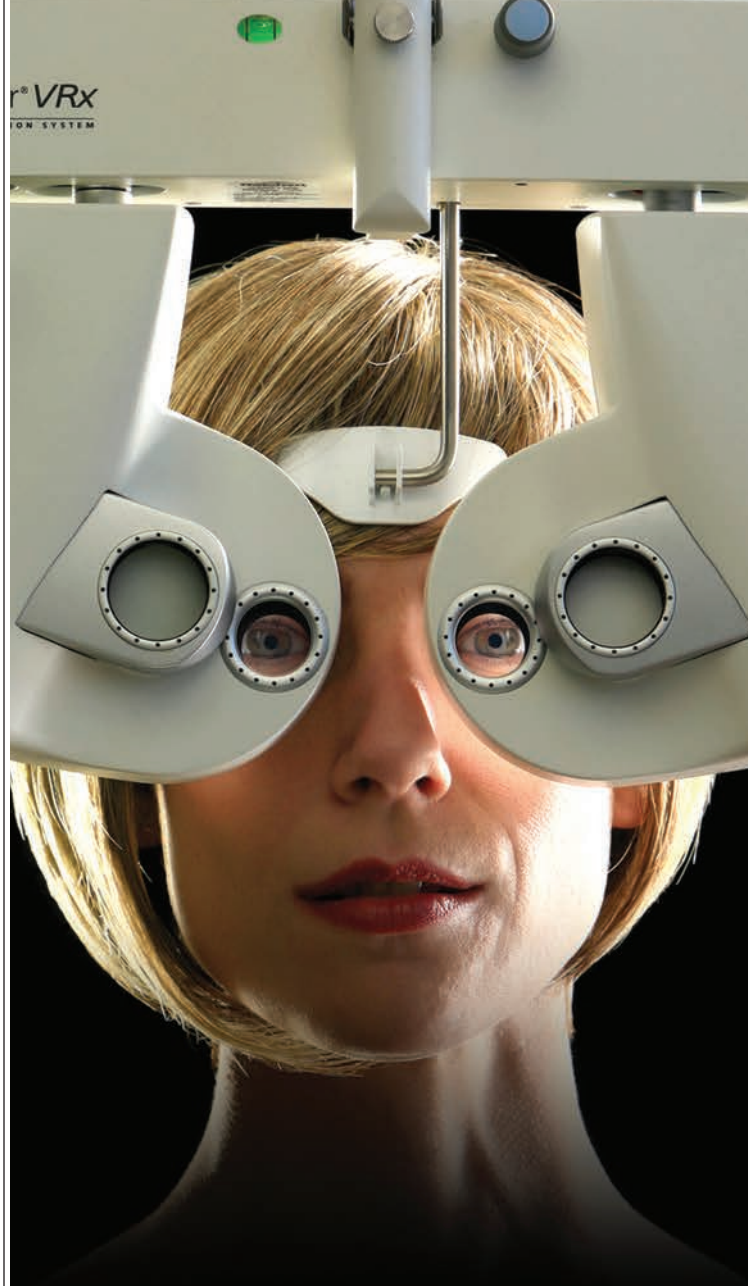damage—such as spectral-domain (SD) optical coherence tomography (OCT), fundus autofluorescence or multifocal electroretinogram (ERG)—in addition to a dilated fundus exam and 10-2 visual fields.¹ Clinicians should use wider visual field test patterns (24-2 or 30-2) for patients of Asian descent, as research shows this patient population has early damage in a more peripheral, rather than paracentral, pattern.¹

High-resolution OCT can detect localized thinning in the parafoveal region, and loss of the inner/outer segment line, known as the ellipsoid zone, on SD-OCT is considered one of the earliest signs of potential toxicity. Fundus autofluorescence abnormalities have been reported prior to visual field loss and early photoreceptor damage will show an increase in autofluorescence due to outer segment debris accumulation.² Multifocal ERG produces local responses across the posterior pole and will show paracentral ERG depression in early Plaquenil toxicity.

The medication dosage is also an important factor in monitoring for toxicity. Plaquenil is typically prescribed as 200mg or 400mg daily. Clinicians should use real weight rather than ideal weight when calculating dosage because ideal weight can cause an overdose in thin individuals.¹ The target dosage is usually less than or equal to 5mg/kg of real weight. Because the cumulative dose poses the highest risk of retinal toxicity, the AAO's recommendations call for a baseline examination at the initiation of therapy and then annual screening after five years of treatment for low risk patients.¹⁻³ More frequent screening is recommended for high-risk patients, including those on a higher dose and those with renal or liver disease.¹

Topiramate

This sulfa-derived monosaccharide is an effective anti-seizure medication that enhances the action of gamma-aminobutyric acid, decreases the action of glutamate



PASSIONATE ABOUT PATIENT EXPERIENCE?

The most advanced Phoroptor® ever.





Phoroptor® VRx Digital Refraction System

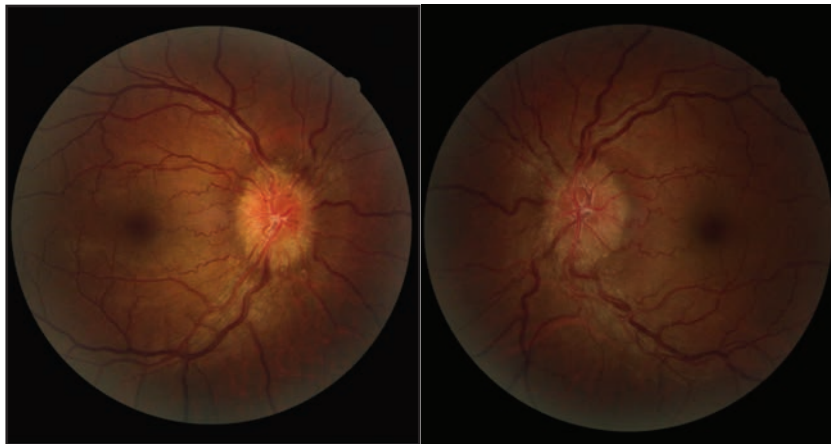
A premium refraction experience. Incredibly fast.
Ultra-quiet. Effortless integration. Made in USA.

Watch the video at reichert.com/vrx

Reichert
TECHNOLOGIES

AMETEK © 2018 AMETEK, Inc. & Reichert, Inc. (03-2018) · Made in USA

Phoroptor is a registered trademark of Reichert, Inc. · www.reichert.com ·    



Six weeks after starting isotretinoin for the treatment of acne, this patient with increased intracranial hypertension presented with bilateral optic disc edema.

and blocks sodium channels. It is also a common treatment option for migraine and any number of other conditions such as bipolar, post-traumatic stress and obsessive-compulsive disorders.⁴

ODs must carefully monitor patients taking topiramate, as it can cause ciliary body effusion, which relaxes the zonules and allows lens thickening, resulting in a myopic shift of as much as -9.00D.^{5,6} It can also cause anterior rotation of the ciliary processes, possibly inducing appositional acute angle-closure glaucoma.^{7,8} Topiramate-induced angle-closure typically occurs within the first two weeks of starting the medication or within hours of doubling the dose.⁶

The incidence of myopia and acute angle-closure with topiramate use is a well-recognized adverse reaction, but the true incidence is generally thought to be low. A 2004 study cited only 86 cases of topiramate-associated acute angle closure and 17 cases of acute bilateral myopia in the literature at the time.⁹ Since 2004, fewer than 50 additional case reports have been published.¹⁰

B-scan ultrasound, ultrasound biomicroscopy and anterior segment OCT can reveal the anatomic changes that create this reaction.

Most ocular issues associated with topiramate resolve after discontinuing the medication. Oral hypotensives can help control intraocular pressure, and cycloplegics can help retract the ciliary processes.

Phosphodiesterase Inhibitors

The active ingredient in erectile dysfunction drugs, phosphodiesterase 5 (PDE 5) inhibitors block the predominant metabolizer of cyclic guanosine monophosphate that stimulates the smooth muscle relaxation

necessary for erection.

The most common ocular complaint with PDE 5 inhibitors is a bluish tinge or haze to vision along with increased light sensitivity. Other ocular side effects include decreased color vision, blurred or transitory decreased vision with central haze, changes in light perception, transient ERG changes, conjunctival hyperemia, ocular pain, mydriasis (may be an emotional effect) and retinal vascular occlusions and subconjunctival hemorrhages, which may be secondary to exertion.

Ischemic optic neuropathy (ION) is the most concerning potential side effect. Although infrequent (3% of cases) in those taking low doses (25mg to 50mg), incidence can reach 11% in those taking 100mg and 50% at 200mg.¹¹ Symptoms begin 15 to 30 minutes after taking the medication and peak at 60 minutes. Research suggests ION has a temporal association with PDE 5 inhibitors, but this remains controversial.¹² For one, many patients taking these medications also have risk factors for ION, and the vascular risk factors for nonarteritic anterior ION (NAION) often overlap with vascular risk factors for erectile dysfunction.

Fingolimod

Gilenya (fingolimod, Novartis), the first oral treatment for relapsing-remitting multiple sclerosis (MS), is effective in reducing the number of relapses and improving overall disability progression over long-term follow up.¹³ Fingolimod is an immunomodulating agent that binds to sphingosine-1-phosphate (S1P) receptors on the lymphocytes and prevents lymphocyte release from the lymph nodes, reducing lymphocyte migration into the central nervous system.¹⁴ This spares the system from attack by these myelin-reactive lymphocytes.

As sphingolipids are the third most numerous lipid in the retina, fingolimod-associated macular edema (FAME) is a possible side effect, reported in two pivotal studies that investigated the drug's safety and efficacy.^{13,15} S1P receptors in retinal blood vessel endothelial cells are responsible for maintaining cell adhesion complexes, so when fingolimod downregulates the S1P receptors, it also downregulates adhesion complexes and increases retinal vascular permeability, resulting in macular edema.¹⁶ In one study, 0.5% of patients receiving 0.5mg of daily fingolimod and 1.0%

of those receiving 1.25mg of daily fingolimod developed macular edema.¹⁵

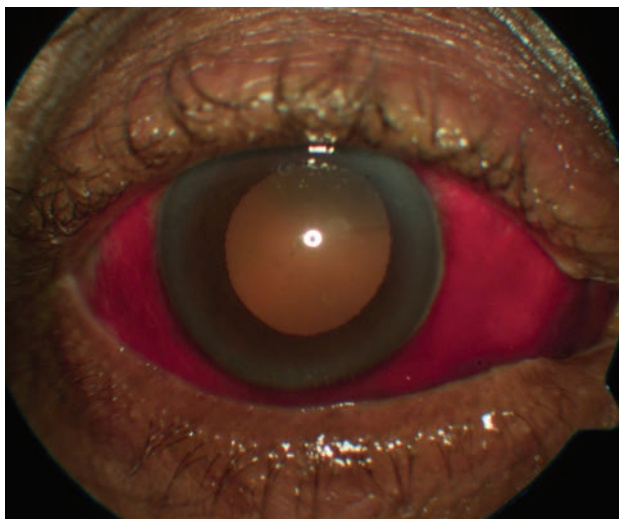Most patients who develop FAME do so within four months of starting treatment, and it resolves after the drug is discontinued.¹⁶ Clinicians should screen patients taking fingolimod with a complete eye examination and macular OCT at baseline and again in three to four months. Clinicians should exercise caution when treating diabetic patients due to the preexisting blood-retinal barrier compromise.

Isotretinoin

An analog of vitamin A, this is used to treat severe, recalcitrant nodular acne, psoriasis and disorders of keratinization. It alters skin lipid composition, reduces sebaceous gland size and decreases sebum production, in addition to having anti-inflammatory properties.¹⁷

Isotretinoin-induced meibomian gland dysfunction leads to eye dryness, ocular surface irritation, decreased contact lens tolerance, photophobia, blepharoconjunctivitis, decreased vision and even an increase in hordeolum and chalazion frequency.¹⁸ Studies link isotretinoin to the development of secondary increased intracranial hypertension due to increased resistance to cerebrospinal fluid outflow.

Patients will often present with headaches (typically postural), blurred vision, subjective visual obscurations and tinnitus. Increased intracranial pressure can cause bilateral optic nerve head edema, which can last for weeks after discontinuing the medication and can be vision-threatening if left undetected. While a serious complication, increased intracranial pressure is rare.



This patient being anti-coagulated with warfarin presented with subconjunctival hemorrhage.



PASSIONATE ABOUT PATIENT EXPERIENCE?


Pixel-perfect acuity testing.





ClearChart® 4 · 4X · 4P Digital Acuity Systems

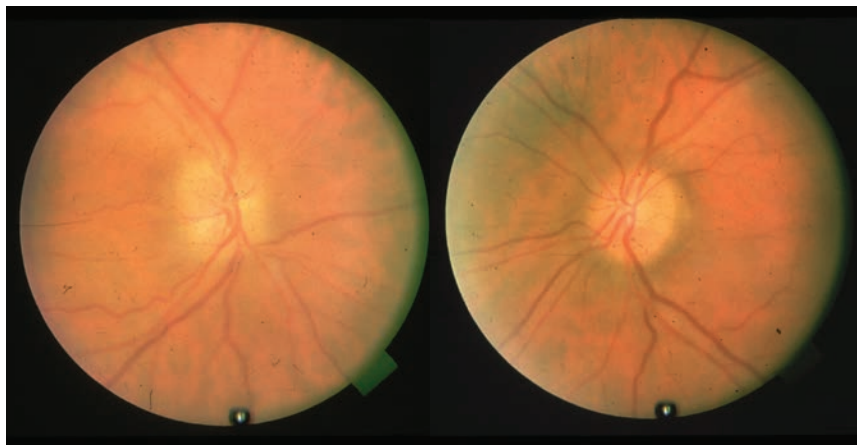
Simple-to-use interface. 24-inch, LED backlit display.
Custom developed for acuity testing. Made in USA.

See the full line at reichert.com/clearchart

Reichert®
TECHNOLOGIES

AMETEK® © 2018 AMETEK, Inc. & Reichert, Inc. (03-2018) - Made in USA 

ClearChart is a registered trademark of Reichert, Inc. · www.reichert.com ·    



This patient's toxic optic neuropathy is due to amiodarone use.

Tamoxifen

This oral anti-estrogen medication is used to treat advanced metastatic breast cancer and as an adjunctive endocrine therapy following resection in early disease. Endocrine therapy works to combat steroid hormone assisted tumor growth in hormonally dependent breast cancer cells. Tamoxifen competes with estradiol for receptors in breast, uterine and vaginal tissues as well as in tumors containing high concentrations of estrogen receptors.¹⁹

Ocular toxicity from tamoxifen presents as a crystalline retinopathy with yellow-white refractile bodies confined to the plexiform and nerve fiber layers, typically found in the macular and paramacular areas. Sometimes, it can be associated with macular edema and a whorl-like superficial keratopathy.²⁰ Ocular toxicity is typically associated with high doses in excess of 120mg daily; it is not common with the standard daily dose of 20mg.^{21,22}

SD-OCT imaging helps to detect subtle maculopathy associated with tamoxifen use. Low dose usage, for example, can produce pseudo-cystic cavities in the macula, which do not leak on fluorescein angiography and do not increase retinal thickness.²²

Research suggests Müller cell dysfunction contributes to tamoxifen ocular toxicity because the medication inhibits the glutamate-aspartate transporter present in Müller cells.²³ Excess glutamate, in turn, may cause Müller cell dysfunction and neuronal apoptosis, creating cavitory spaces.²⁴ One study found that full-thickness macular holes were five times more likely in patients taking tamoxifen, possibly caused by the foveal cavities.²⁵ All patients on tamoxifen should have a baseline and yearly dilated eye examination with SD-OCT of the macula.

Ethambutol

This medication is most commonly used as part of the lengthy quadruple antibiotic regimen for the treatment of tuberculosis (TB) and in the multi-drug therapy for mycobacterium avid complex lung disease.²⁶ It is a metal chelator, which prevents cell wall synthesis in mycobacteria by inhibiting arabinosyl transferase.²⁷

Ethambutol is known to cause optic neuropathy characterized by bilateral central vision loss, color vision loss, central or cecentral visual field scotomas and even-

tual optic atrophy. The exact mechanism is unknown, but researchers theorize it is due to either decreased mitochondrial copper, which is necessary for oxidative phosphorylation, or the chelation of zinc, which inhibits lysosomal activation.^{28,29}

Toxicity is dose related with an incidence of 18% with more than 35mg/kg/day, 5% to 6% with doses of 25mg/kg/day, 3% with 20mg/kg/day and less than 1% at less than or equal to 15 mg/kg/day.³⁰

Between 30% and 64% of patients will show some visual recovery if the optic neuropathy is detected early and the medication is discontinued.²⁷ Patients should have a baseline exam with vision screening, color vision, Amsler grid and visual field testing, in addition to a dilated fundus exam and nerve fiber layer OCT. They should be re-examined monthly while on the ethambutol therapy.

Tamsulosin

Flomax (tamsulosin, Boehringer Ingelheim Pharmaceuticals) is a selective α 1A-adrenergic receptor antagonist used to treat benign prostate hyperplasia by relaxing smooth muscles in the neck of the bladder and in the prostatic urethra. These receptors are also found on the iris dilator muscle, leading to ocular effects of the medication. Selective α 1A antagonists are known to cause intraoperative floppy iris syndrome (IFIS) during cataract extraction and a likelihood of iris prolapse through the surgical wound.³¹ The exact mechanism of IFIS is unknown, although one study suggests chronic blockade of the α 1A-adrenergic receptors can decrease smooth muscle tone and cause diffuse atrophy of the iris dilator.³² The researchers found histologic evidence of decreased iris dilator muscle thickness in cadaver eyes with a history of tamsulosin use compared with

cadaver control eyes.³² Surgeons and comanaging ODs must be aware that IFIS may still occur several years after discontinuing the drug, and stopping tamsulosin preoperatively is of uncertain benefit.

Atrial Fibrillation Agents

Several vascular medications come with significant ocular effects ODs must be on the lookout for:

Amiodarone is an effective anti-arrhythmic medication for ventricular tachycardia and fibrillation and atrial fibrillation. It blocks calcium, potassium and sodium channels in cardiac tissue, which prolongs the cardiac action potential and refractory period. It is also a weak beta blocker and vasodilator.

Ocular side effects of amiodarone include corneal verticillata or whorl-like keratopathy, which occur in 70% to 100% of patients. This keratopathy is related to the dose and duration of treatment, generally appears after at least one month of therapy and will resolve upon discontinuation of the medication. Amiodarone can also cause anterior lenticular subcapsular opacities in 50% to 60% of patients. Both the corneal and lenticular deposits are typically asymptomatic.³³

Amiodarone has also been linked to optic neuropathy, with a clinical presentation similar to NAION. Amiodarone-induced optic neuropathy should be a diagnosis of exclusion, considering most patients taking amiodarone have vascular risk factors already increasing their NAION risk. One report found an incidence of amiodarone-induced optic neuropathy at roughly 2% compared with a general incidence of 0.3%.³⁴ It has an insidious onset, milder degree of vision loss, longer duration of disc edema and is more commonly bilateral than NAION.³⁵ Amiodarone has a long half-life, averaging 58 days, but up to 142 days, and accumulates in the lysosomes of multiple tissues, including the optic nerve, so optic disc swelling can persist for months after discontinuing the medication.^{36,37}

Digoxin inhibits the cell membrane Na⁺/K⁺-ATPase, creating an increase in intracellular calcium and sodium and extracellular potassium. This leads to stronger myocardial contraction and excitability and a decrease in the conduction and depolarization velocity in the atrioventricular node, which resets the rhythm of the heart rate. Digoxin is a second-line treatment for atrial fibrillation and in severe symptomatic systolic heart failure.³⁸

Approximately 95% of patients in the toxic range will report ocular symptoms, the most common being xanthopsia, or yellowing vision.³⁹ Cyanopsia (blue vision) and chloropsia (green vision) have also been reported.⁴⁰ Other ocular symptoms include flashing,



PASSIONATE ABOUT PATIENT EXPERIENCE?

Elements of pre-test.

OptoChek™ Plus Auto Refractor + Keratometer
LensChek™ Plus & Pro Digital Lensometers

Reichert® combines technology, simplicity,
and value at the core of your exam.

Learn more at reichert.com/exam

Reichert
TECHNOLOGIES

AMETEK © 2018 AMETEK, Inc. & Reichert, Inc. (03-2018)

www.reichert.com

Systemic Therapy

scintillating or moving lights or spots, blurred, hazy, misty or snowy vision and difficulty reading. Clinical ocular findings include decreased visual acuity, central scotoma, color vision defects and delayed b-wave time and decreased b-wave amplitude on ERG. While still under debate, most presume ocular symptoms are related to Na⁺/K⁺ ATPase inhibition.³⁸ Symptomatic patients should be referred back to their cardiologist for monitoring.

Anticoagulants are used to help prevent clotting in a wide variety of systemic disorders. The ocular and systemic side effects occur with varying frequencies depending on the specific medication. Platelet inhibitors such as clopidogrel, dipyridamole and aspirin are effective but with a lower incidence of side effects.

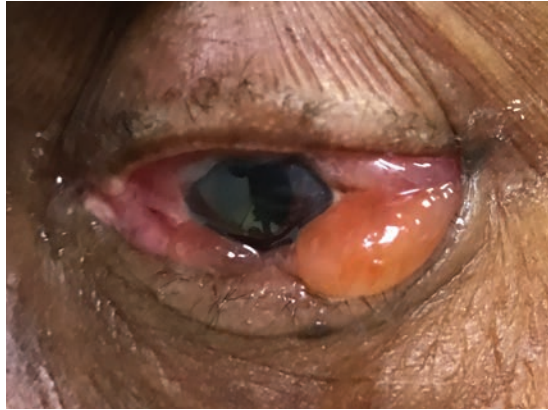
Warfarin is a potent oral anticoagulant that poses a high risk of bleeding disorders. It inhibits vitamin K-dependent gamma-carboxylation of coagulation factors II, VII, IX and X. Warfarin can be affected by other medications, as well as a patient's dietary intake of vitamin K. Because of its narrow therapeutic window, warfarin requires frequent monitoring via laboratory testing.⁴¹

Direct-acting oral anticoagulants (DOACs) are used to treat patients with venous thromboembolism and nonvalvular atrial fibrillation.⁴² Research shows DOACs are as effective as warfarin in preventing stroke due to atrial fibrillation while also having a lower overall bleeding risk, especially intracranial bleeding. In addition, they are less affected by diet and medication interactions.⁴³

Atrial fibrillation agents all carry the risk of increased bleeding. The most worrisome is the potential for intracranial hemorrhage. Ocular side effects of anticoagulants include subconjunctival hemorrhage, retinal hemorrhage, orbital hemorrhage causing mass effect and exacerbation of bleeding from other ocular conditions such as proliferative diabetic retinopathy and exudative macular degeneration.

Bisphosphonates

These are widely used in the treatment of osteoporosis, Paget's disease, metastatic bone disease, multiple myeloma and hypercalcemia of malignancy. Bisphosphonates



This patient presented two days after bisphosphonate infusion with severe ocular inflammation.

are rapidly cleared from circulation and are absorbed into bone mineral surfaces, where they slow osteoclasts to allow osteoblasts to rebuild bone.⁴⁴

The most common ocular side effect of bisphosphonates is a self-limiting conjunctivitis.⁴⁵ Uveitis and scleritis, two serious possible ocular side effects, might not resolve unless the medication is discontinued.⁴⁵ One study found scleritis and uveitis were rare in bisphosphonate users and that 43% of the patients who developed either condition had a systemic condition already associated with uveitis or scleritis.⁴⁶ Researchers can only speculate that bisphosphonates use might be a precipitating factor for ocular inflammation in patients already prone to these conditions.⁴⁴ Patients who develop serious ocular inflammation need oral and topical anti-inflammatories and often require discontinuation of bisphosphonates for resolution.

Ocular side effects from systemic medications can be serious and sight threatening. It is crucial for ODs to catalogue each patient's systemic medications, discuss the possible side effects and monitor appropriately. Often, additional testing is warranted to screen for effects and detect early toxicity. ■

Ocular side effects from systemic medications can be serious and sight threatening. It is crucial for ODs to catalogue each patient's systemic medications, discuss the possible side effects and monitor appropriately. Often, additional testing is warranted to screen for effects and detect early toxicity. ■

Dr. Hunter is an assistant professor of ophthalmology at Loyola University Medical Center in Maywood, IL. She is the current national chair of the American Academy of Optometry's admittance committee.

Dr. Marciniak works at the Jesse Brown VAMC, teaches at Illinois College of Optometry and works in private practice. She is a member of the Advanced Competency in Medical Optometry committee.

1. Armor MF, Kellner U, Lai TY, et al. Recommendations on screening for chloroquine and hydroxychloroquine retinopathy (2016 revision). *Ophthalmology*. 2016;123(6):1386-94.
2. Marmor MF, Kellner U, Lai TY, et al. Revised recommendations on screening for chloroquine and hydroxychloroquine retinopathy. *Ophthalmology*. 2011;118(2):415-22.
3. Marmor MF, Carr RE, Easterbrook M, et al. Recommendations on screening for chloroquine and hydroxychloroquine retinopathy. *Ophthalmology*. 2002;109(7):1377-82.
4. Silberstein SD, Lipton RB, Dodick DW, et al. Efficacy and safety of topiramate for the treatment of chronic migraine: A randomized, double-blind, placebo-controlled trial. *Headache*. 2007;47(2):170-80.
5. Grinbaum A, Ashkenazi I, Gutman I, Blumenthal M. Suggested mechanism for acute transient myopia after sulfonamide treatment. *Ann Ophthalmol*. 1993;25(6):224-6.
6. Mitra A, Ramakrishnan R, Kader MA. Anterior segment optical coherence tomography documentation of a case of topiramate induced acute angle closure. *Indian J Ophthalmol*. 2014;62(5):619-22.
7. Maddalena MA. Transient myopia associated with acute glaucoma and retinal edema. *JAMA*

Ophthalmol. 1968;80:186-8.

8. Banta JT, Hoffman K, Budenz DL, et al. Presumed topiramate-induced bilateral acute angle-closure glaucoma. *Am J Ophthalmol*. 2001;132(1):112-4.
9. Frauenfelder FW, Frauenfelder FT. Adverse ocular drug reactions recently identified by the National Registry of Drug-Induced Ocular Side Effects. *Ophthalmology*. 2004;111(7):1275-9.
10. Pubmed search. www.pubmed.gov. Accessed March 13, 2018.
11. Armor MF, Kessler R. Sildenafil (Viagra) and ophthalmology. *Surv Ophthalmol*. 1999;44(2):153-62.
12. Frauenfelder F. Visual side effects associated with erectile dysfunction agents. *Am J Ophthalmol*. 2005;140(4):723-4.
13. Kappas L, Radue EW, O'Connor P, et al. A placebo-controlled trial of oral fingolimod in relapsing multiple sclerosis. *N Engl J Med*. 2010;362(5):387-401.
14. Groves A, Kahara Y, Chun J. Fingolimod: direct CNS effects on sphingosine 1-phosphate (S1) receptor modulation and implications in multiple sclerosis therapy. *J Neurol Sci*. 2013;328(1-2):9-18.
15. Cohen FA, Barkhof F, Comi G, et al. Oral fingolimod or intramuscular interferon for relapsing multiple sclerosis. *N Engl J Med*. 2010;362(5):402-15.
16. Mandal P, Gupta A, Fusi-Rubiano W, et al. Fingolimod: therapeutic mechanisms and ocular adverse effects. *Eye*. 2017;31(2):232-40.
17. Tan J, Boyal S, Desai K, Knezevic S. Oral Isotretinoin: New developments relevant to clinical practice. *Dermatol Clin*. 2016;34(2):175-84.
18. Neudofer M, Goldshetin I, Shamai-Lubovitz O, et al. Ocular adverse effects of systemic treatment with isotretinoin. *Arch Dermatol*. 2012;148(7):803-8.
19. Rolf MM. Clinical implications of tamoxifen ocular toxicity. *Clin Eye Vis Care*. 1998;10(3):135-40.
20. McKeown C. Tamoxifen retinopathy. *Br J Ophthalmol*. 1981;65:177-9.
21. Burl DH, Sarraf D, Schwartz SD. Peripheral retinopathy and maculopathy in high-dose tamoxifen therapy. *Am J Ophthalmol*. 2007;144(1):126-8.
22. Yoshi RR, Fortun JA, Kim BT, et al. Pseudocystic foveal cavitation in tamoxifen retinopathy. *Am J Ophthalmol*. 2014;157(6):1291-8.
23. Maenpaa H, Mannerstrom M, Toimela T, et al. Glutamate uptake is inhibited by tamoxifen and toremifen in cultured retinal pigment epithelial cells. *Pharmacol Toxicol*. 2002;91(3):116-22.
24. Brinkmann A, Pannicke T, Grosche J, et al. Muller cells in the healthy and diseased retina. *Prog Retin Eye Res*. 2006;25(4):397-424.
25. Bernstein PS, DellaCroce JT. Diagnostic and therapeutic challenges. Tamoxifen toxicity. *Retina*. 2007;27(7):982-8.
26. Griffith DE, Brown-Elliott BS, Shepherd S, et al. Ethambutol ocular toxicity in treatment regimens for Mycobacterium avium complex lung disease. *Am J Respir Crit Care Med*. 2005;172(2):250-3.
27. Chamberlain PD, Sadak A, Berry S, Lee AG. Ethambutol optic neuropathy. *Curr Opin Ophthalmol*. 2017;28(6):545-51.
28. Kodak SF, Underlined CB, Hsu HY, et al. The role of copper on ethambutol's antimicrobial action and implications for ethambutol-induced optic neuropathy. *Diagn Microbiol Infect Dis*. 1998;30(2):83-7.
29. Chung H, Yoon YH. Ethambutol-induced toxicity is mediated by zinc and lysosomal membrane permeabilization in cultured retinal cells. *Toxicol Appl Pharmacol*. 2009;235:163-70.
30. Yang HK, Park MJ, Lee JH, et al. Incidence of toxic optic neuropathy with low-dose ethambutol. *Int J Tuberc Lung Dis*. 2016;20(2):261-4.
31. Chang DF, Campbell JR. Intraoperative floppy iris syndrome associated with tamsulosin. *J Cataract Refract Surg*. 2005;31(4):664-73.
32. Santaella RM, Destafeno JJ, Stinnett SS, et al. The effect of α 1-adrenergic receptor antagonist tamsulosin (Flomax) on iris dilator smooth muscle anatomy. *Ophthalmology*. 2010;117(6):1743-9.
33. Mantjarvi M, Tuppurainen K, Ikaheimo K. Ocular side effects of amiodarone. *Surv Ophthalmol*. 1998;42(4):360-6.
34. Reiner LA, Young BR, Kazmier FJ, et al. Optic neuropathy and amiodarone therapy. *Mayo Clin Proc*. 1987;62(8):702-17.
35. Macaluso DC, Suhlst Wt, Frauenfelder FT. Features of amiodarone-induced optic neuropathy. *Am J Ophthalmol*. 1999;127(5):610-2.
36. Amiodarone: guidelines for use and Monitoring. *Am Fam Physician*. 2003;68:2189-97.
37. Manor AM, Puklin JE, O'Grady R. Optic nerve ultrastructure following amiodarone therapy. *J Clin Neuro-ophthalmol*. 1988;8(4):231-7.
38. Renard D, Rubli E, Voide N, et al. Spectrum of digoxin-induced ocular toxicity: a case report and literature review. *BMC Res Notes*. 2015;8:368.
39. Piltz JR, Wertebaker C, Lance SE, et al. Digoxin toxicity. *J Clin Neuro-Oph*. 1993;13(4):275-80.
40. Towbin EJ, Pickens WS, Doherty JE. The effects of digoxin upon color vision and the electroretinogram. *Clin R*. 1967;15:60.
41. Go AS, Hylek EM, Borowsky LH, et al. Warfarin use among ambulatory patients with nonvalvular atrial fibrillation: the anticoagulation and risk factors in atrial fibrillation (Atrial) study. *Ann Intern Med*. 1999;131(12):927-34.
42. Chadha DS, Bharadwaj BP. Direct acting oral anticoagulant: bench to bedside. *Med J Armed Forces India*. 2017;73:274-81.
43. Lopez JA, Sterne JA, Thom HHZ, et al. Oral anticoagulants for prevention of stroke in atrial fibrillation: systematic review, network metaanalysis, and cost effectiveness analysis. *Br J Ophthalmol*. 2017 Nov 28;359:j5058.
44. Papapetrou PD. Bisphosphonate-associated adverse events. *Hormones*. 2009;8(20):96-110.
45. Frauenfelder FW, Frauenfelder FT, Jensvold B. Scleritis and other ocular side effects associated with pamidronate disodium. *Am J Ophthalmol*. 2003;135(2):219-22.
46. French DD, Margo CE. Postmarketing surveillance of uveitis and scleritis with bisphosphonates among a national veteran cohort. *Retina*. 2008;28:889-93.



PASSIONATE ABOUT PATIENT CARE?

His sight depends
on your confidence.

Ocular Response Analyzer® G3

Corneal Hysteresis, a more objective predictor
of glaucoma progression. CPT code 92145.

Watch the videos at reichert.com/glaucomaconfidence

Reichert
TECHNOLOGIES

AMETEK © 2018 AMETEK, Inc. & Reichert, Inc. (03-2018) · Made in USA

Ocular Response Analyzer is a registered trademark of Reichert, Inc. · www.reichert.com ·

One Size Won't Fit All: Treating Ocular Infection

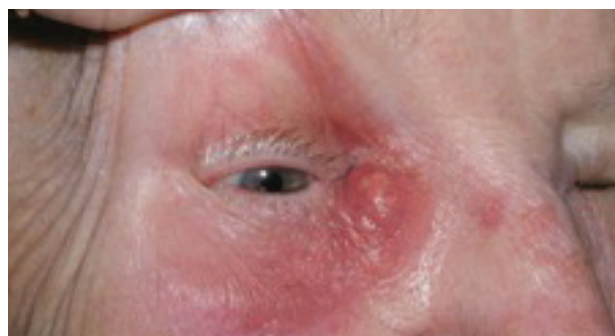
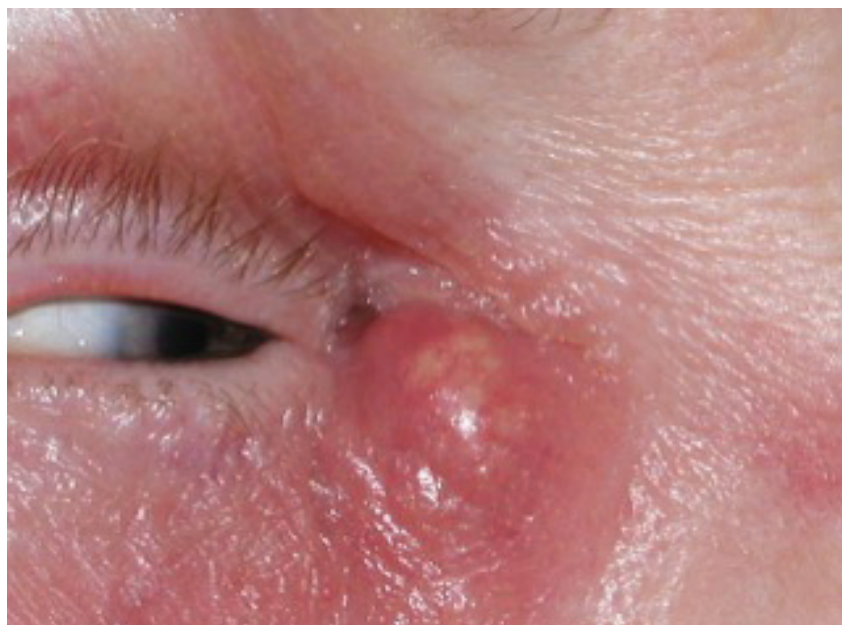
Knowing which antibiotic to choose and how to use it are critical when treating and beating ocular infection. **By Tracy Offerdahl-McGowan, PharmD, and Greg Caldwell, OD**

Due to their complexity and temperament, ocular infections can be a pain to treat. Finding the right antibiotic requires a thorough understanding of the most likely causative organisms, resistance patterns, patient-specific data and pharmacologic information that may impact the patient's response to the drug. And we have to do it all while the clock is ticking—the earlier treatment begins, the better the prognosis. However, sometimes, less is more. Exercising discretion in situations where the infection is most likely to be caused by a virus, such as in non-purulent infectious conjunctivitis, has been proven to decrease the spread of resistant organisms.^{1,2}

Into this thicket walks the optometrist, who must navigate carefully and make many decisions to move forward safely.

Chiefs of Staph.

The first key question is whether to use an oral or a topical agent. Oral antibiotics are accepted as the standard of care when treating infections

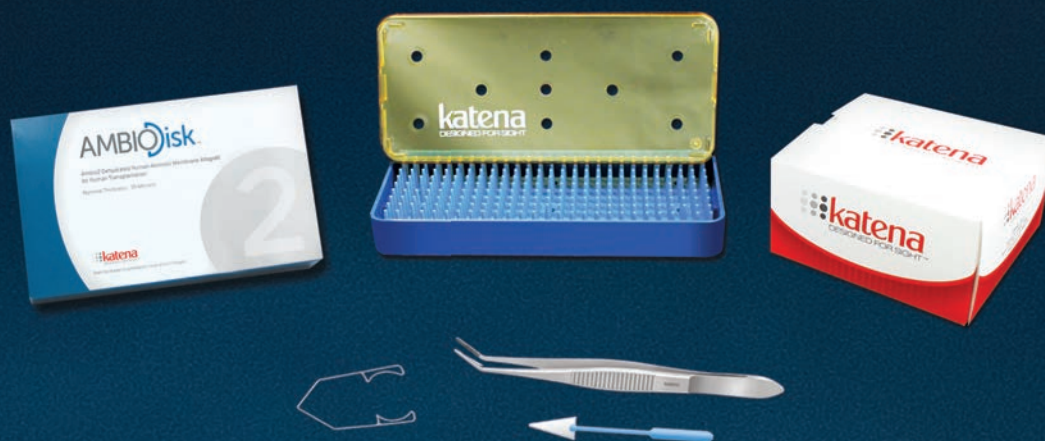

These images show a patient with dacryocystitis and preseptal cellulitis before being treated with antibiotics.

HIT THE DRY EYE MARK WITH AMBIOisk®



Launch your adoption of amniotic membrane
with the **Jump Start Kit**. *Call Katena for details!*



Amniotic membrane is considered an appropriate end stage treatment option to address conditions outlined in the DEWS II step 4 guidelines for severe dry eye.*



800.225.1195 • info@katena.com • www.katena.com

*Physicians may choose to use amniotic membrane at their discretion.
REFERENCE: Craig JP et al., TFOS DEWS II Report Executive Summary,
The Ocular Surface (2017), <http://dx.doi.org/10.1016/j.jtos.2017.08.003>

KB-Adv-011518-Rev0



Antibiotics

such as hordeolum, preseptal cellulitis and dacryocystitis.^{3,4} Compared with topical antibiotics, orals produce significant levels in the bloodstream, which provide superior penetration of the lacrimal apparatus and surrounding tissues. For this reason, these infections are more effectively treated with an oral agent.³

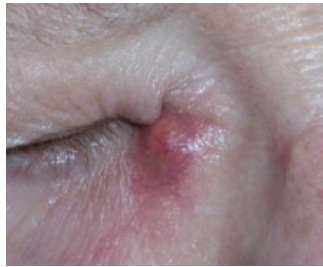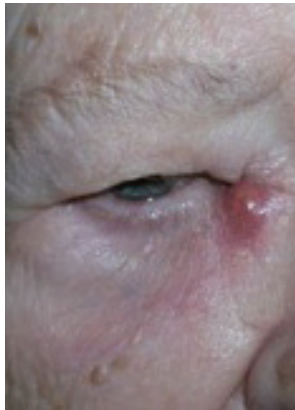Most corneal and conjunctival infections are best managed with a topical fluoroquinolone, perhaps with an oral agent added for more coverage if circumstances warrant.

Common organisms associated with hordeolum, dacryocystitis and preseptal cellulitis include the gram-positive organisms *Staphylococcus aureus*, *Staphylococcus epidermidis* and *Streptococcus pneumoniae* (Table 1). But they also include gram-negative organisms such as *Haemophilus influenzae* and occasionally *Pseudomonas aeruginosa*.⁵⁻⁷

When choosing an oral antibiotic to treat these relatively common ocular infections, inquire about the presence of allergy, pregnancy, breastfeeding, comorbidities, drug interactions, prior antibiotic use and ability to pay out of pocket for the more costly medications.

MRSA Matters

Since methicillin-resistant *Staphy-*



These images show the same patient from page 52 a week after initiating antibiotic treatment.

lococcus aureus (MRSA) is a common colonizer on skin, clinical consideration should be given to determine whether a patient needs antibiotic coverage for this organism. This is typically determined by local prevalence and risk factors.⁵⁻⁷

While sulfamethoxazole-trimethoprim (SMX-TMP), doxycycline and clindamycin may not be an OD's typical "go to" drugs when treating hordeolum, preseptal cellulitis and dacryocystitis, they are important to consider, especially when managing community-acquired (as opposed to hospital-acquired) resistant *Staph. aureus* MRSA infections (Table 2).³³

In the past, practitioners relied on intravenous vancomycin to treat MRSA infections, but today we are fortunate to have SMX-TMP, doxycycline and clindamycin in our MRSA arsenal. Doxycycline is generally considered a "last-line" in the trio of agents that cover MRSA, mainly because of tolerability issues. When a patient fails

traditional therapy that covers *Staph. aureus*, or when a patient is colonized with MRSA, it's a good time to consider a potential MRSA infection. Susceptibility to MRSA is also heightened in young patients, prisoners and athletes.^{29,30,33}

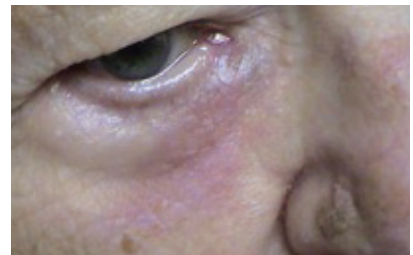
Beta-Lactams

These antibiotics are widely used to treat upper respiratory tract infections and ocular infections. (Table 3).

Amoxicillin and amox + clavulanate. These agents are considered amino-penicillins or extended spectrum penicillins because the amino side-chain extends its coverage to include more gram-negative organisms such as *Haemophilus influenzae* and the *Enterobacteriaceae* family, such as *Escherichia coli*, when compared with penicillin VK.

Additionally, these agents have good coverage against sensitive *Staph. aureus* and even *Streptococcus pneumoniae* when given in high doses. Keep in mind that coagulase-negative *Staph.* species (e.g., *Staph. epidermidis*) show a decent amount of resistance to these agents and may not be a reasonable choice in a patient infected with this organism. Neither MRSA nor *Pseudomonas aeruginosa* is susceptible to these agents.^{9,10}

Mechanistically, these agents




The resolution of this patient's dacryocystitis and preseptal cellulitis was achieved using antibiotics.

Table 1. Likely Organisms Responsible for Lid/Adnexal Infections

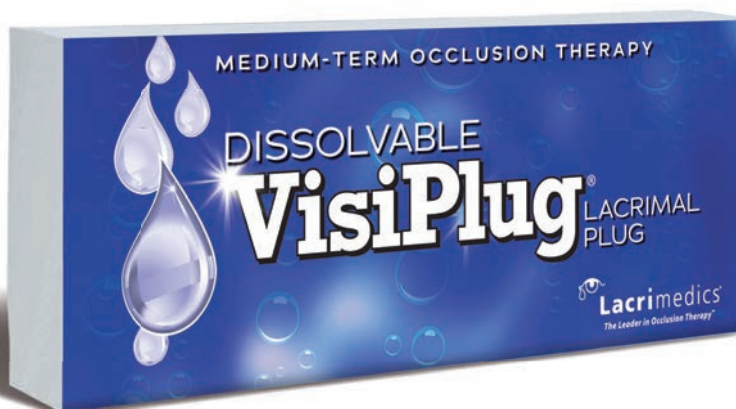Hordeolum	<i>Staphylococcus aureus</i>
Preseptal Cellulitis	<i>Staphylococcus aureus</i> , <i>Streptococcus pneumoniae</i> , <i>Haemophilus influenzae</i>
Dacryocystitis	<i>Staphylococcus aureus</i> , <i>Staphylococcus epidermidis</i> , <i>Pseudomonas aeruginosa</i>



41% of refractive or cataract surgery patients have ocular surface dysfunction levels requiring some treatment beyond artificial tears!¹



Lacrimedics' VisiPlug® is FDA approved for the treatment of the Dry Eye components of varying Ocular Surface Diseases (OSD) and to enhance the efficacy of topical medications.



Don't let 41% of your patients with OSD go untreated, especially when they need something more than artificial tears.

VisiPlug® – Provides approximately 180 days of occlusion so you can better manage your patient's treatment plan.


Lacrimedics®

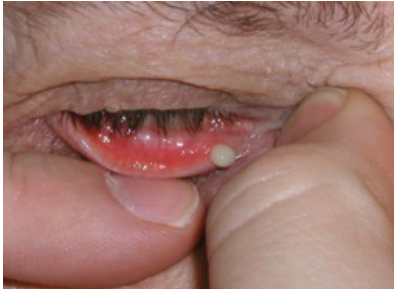(800) 367-8327

DuPont, WA 98327

info@lacrimedics.com • www.lacrimedics.com

©2018 Lacrimedics, Inc.

¹ASCRS Clinical Survey 2015. Global Trends in Ophthalmology and the American Society of Cataract and Refractive Surgery.



This patient presented with a visible dacryocystitis infection, which required antibiotic treatment.

inhibit bacterial cell wall synthesis by plugging into penicillin-binding proteins. This results in bacterial cell death. The addition of the beta-lactamase enzyme inhibitor clavulanate provides increased protection for amoxicillin against hydrolysis when it's exposed to infections caused by organisms that produce beta-lactamase, including *Haemophilus influenzae* and *Moraxella catarrhalis*.

While traditional penicillin has impaired gastrointestinal absorption when given with food, amoxicillin is relatively stable. Additionally, amoxicillin plus clavulanate has improved gastrointestinal tolerability when given with food and is generally recommended that patients take it with a meal. While both amoxicillin and amoxicillin plus clavulanate are both fairly well-tolerated, the latter is more likely to cause nausea and vomiting. Drug interactions with these two agents are miniscule, and the regimen is generally considered safe to take while pregnant.⁹⁻¹¹

Cephalexin. A first-generation cephalosporin, this has gram-positive coverage similar to amoxicillin, but is considered more stable against hydrolysis by beta-lactamase-producing organisms. MRSA and *Pseudomonas aeruginosa* are not susceptible to this agent. Side effects with cephalexin are well-tol-

Table 2. Dosing Regimens for Community-Acquired MRSA^{29,30,33}

Sulfamethoxazole+Trimethoprim DS	800mg/160mg; take one tab BID x 10 days
Clindamycin	300mg to 600mg TID x 10 days
Doxycycline	100mg BID x 10 days

erated and include miniscule drug interactions. In general, cephalexin has also been considered safe in pregnancy.^{9,10}

Allergy ambiguities. Decades of clinical research have allowed us to fine-tune our understanding of penicillin allergies and the potential cross-reaction between a penicillin allergy and other beta-lactam antibiotics (*Table 4*). While some sources report cross-reactions between penicillins and cephalosporins occurring as often as 10% of the time, other research suggests that this is an exaggeration. Nevertheless, the mere “potential” of this cross-reaction has created a culture in which physicians tend to avoid beta-lactam agents and overuse the broader spectrum agents such as macrolides and fluoroquinolones.

When evaluating a patient who claims to possess a “penicillin allergy,” practitioners should investigate the specific nature of the allergic reaction to the drug. Researchers estimate that 90% of patients who claim to be allergic to a penicillin are not actually allergic.^{9,10,12-14}

Typically, the cephalosporins, possessing similar side chains, increase the likelihood of a cross-

reaction. For example, cephalexin is more likely to cross-react with a patient who has penicillin allergy compared with a drug lacking the side chain (e.g., cefuroxime axetil). If a patient is listed as having an allergy to a cephalosporin, it's wise to consider that claim to be true. Also, a cross-reaction from a cephalosporin to a penicillin is rare.¹²⁻¹⁵

Meet the Macrolides

The macrolide class of agents includes erythromycin, clarithromycin and azithromycin. Erythromycin is incredibly well-known to cause nausea and vomiting and is typically taken three to four times per day. For obvious reasons, this agent is rarely used in eye care.

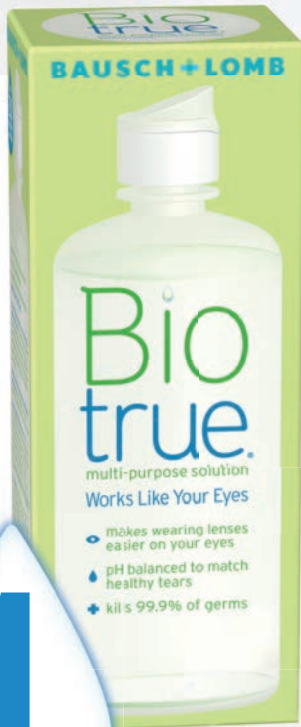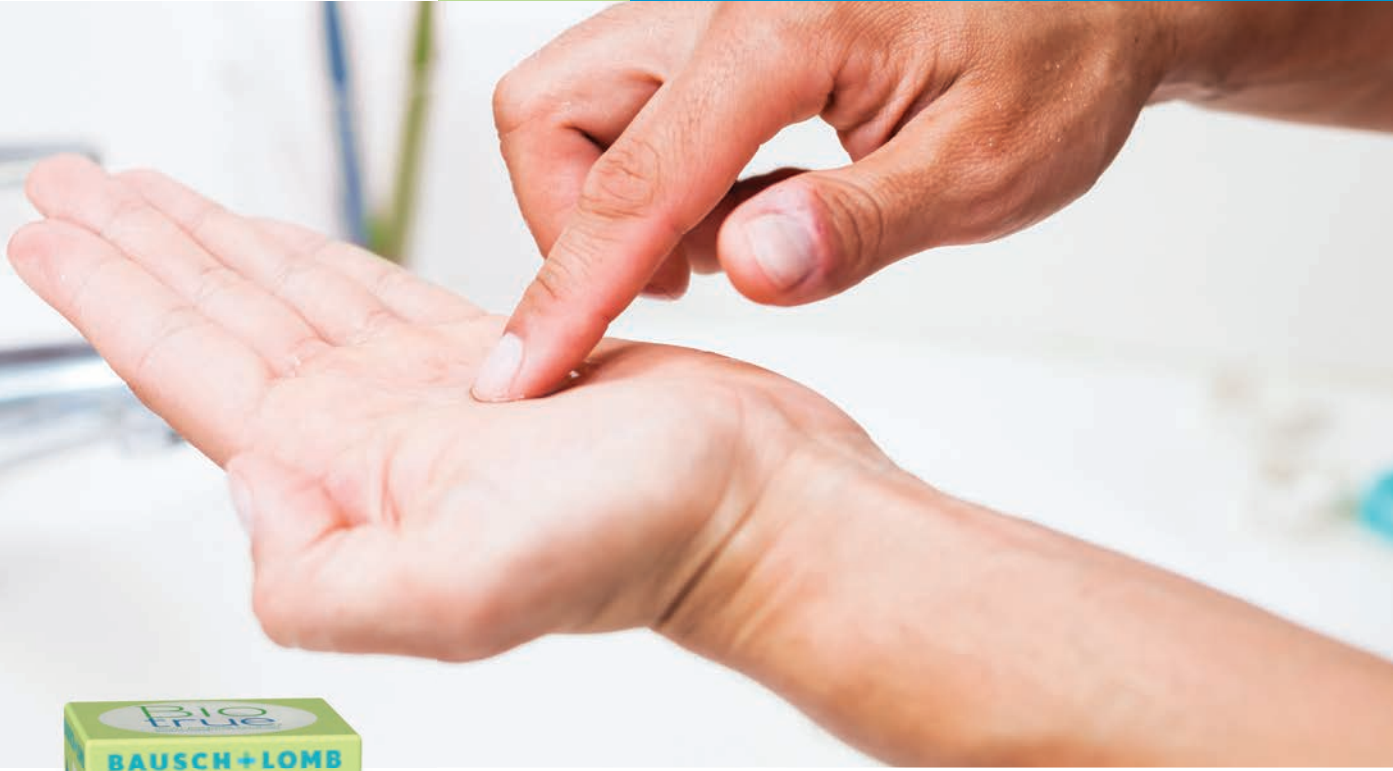Clarithromycin, on the other hand, causes a moderate amount of nausea and vomiting and is dosed BID. As it shows no real benefit over azithromycin, it is used less.

The third agent in this class, azithromycin, proves fairly well-tolerated and is reported as having the fewest drug interactions. It has become the drug of choice for infections requiring a macrolide treatment. It is taken twice daily on the first day and then once for another four days. Due to the

Table 3. Dosing Regimens for Beta-Lactam Agents

Amoxicillin	500mg BID-TID x 10 days 875mg BID x 10 days*
Amoxicillin+Clavulanate	500mg/125mg BID-TID x 10 days 875mg/125mg TID x 10 days*
Cephalexin	500mg BID x 10 days

* higher dose = increased *S. pneumoniae* coverage.



Biotrue[®] solution is unsurpassed in disinfection efficacy^{1*}

The following bio-inspired elements of Biotrue[®] enhance the dual disinfection system. Matching the pH of healthy tears optimizes the performance of the dual disinfectants, and keeping Lysozyme active longer helps maintain tears' inherent antimicrobial activity.^{1,2} No wonder it's the **#1 multi-purpose solution used in more households.**[‡]

3 BIO-INSPIRED INNOVATIONS



Matches the pH of healthy tears (7.5)¹



Keeps lenses moist for up to 20 hours with hyaluronan (HA)³



Keeps key beneficial tear proteins such as lysozyme active¹

Provide your patients with unsurpassed disinfection efficacy.^{1*}
Recommend Biotrue[®], because their solution matters.

For more information, call 1-800-828-9030 or visit bausch.com/biotruesolution

*Based on ISO 14729 testing against the 5 panel organisms.

†Among leading peroxides.

‡Highest household penetration among multi-purpose solutions; IRI Data MULO 52 weeks ending 6/11/17.

REFERENCES: 1. Data on file. Bausch & Lomb Incorporated, Rochester, NY. 2. A lysozyme activity assay was used to determine the ability of Biotrue[®] to prevent the denaturation of lysozyme, in comparison to multiple marketed multi-purpose solutions and leading hydrogen peroxide solution. This assay is based on the ability of lysozyme to digest the cell wall of micro-organisms in a suspension. The results indicate that Biotrue[®] has the ability to stabilize lysozyme in its native form under chemical denaturation conditions that typically denature lysozyme. Statistically significant greater stabilization of lysozyme was observed with Biotrue[®] compared to competitive solutions and a phosphate buffered saline control. 3. In vitro studies evaluated the rate of release of sodium hyaluronate (HA), a conditioning agent in the Biotrue[®] multi-purpose solution, from both conventional and silicone hydrogel contact lenses over a twenty-hour time period. HA was adsorbed on all traditional and silicone hydrogel contact lenses tested upon soaking in the solution overnight. HA is then released from the lenses throughout at least a twenty hour time period when rinsed with Hank's balanced salt solution at a rate mimicking tear secretions. The in-vitro performance of Biotrue[®] multi-purpose solution suggests that it will provide lens conditioning throughout a twenty hour time period.

post-antibiotic effect, five days of therapy treat bacteria systemically for approximately 72 hours past the last dose.¹⁸

When Side Effects Set In

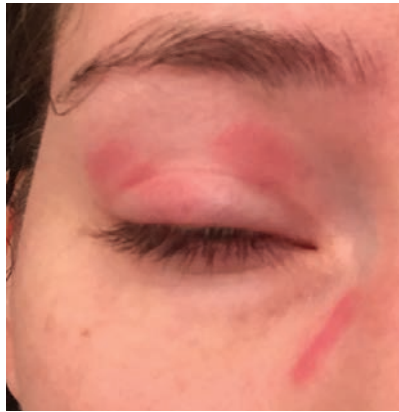Pharmacologically, once we move away from inhibitors of bacterial cell wall synthesis (beta-lactams), we begin to see more side effects from antibiotics because they have an effect on bacterial cells and mammalian cells that are rapidly dividing. Examples of these rapidly dividing cells include those found in the skin, gut and bone marrow.^{16,17}

Mechanistically, the macrolides are protein synthesis inhibitors and bind to the 50S ribosomal subunits in susceptible organisms. *Staph. aureus* and *Strep. pneumoniae* are generally less sensitive to azithromycin as compared with the beta-lactam agents.

On the contrary, *Haemophilus influenzae* is generally more sensitive to azithromycin than to the beta-lactam agents. While azithromycin is generally well tolerated, with occasional mild gastrointestinal complaints, it may cause QT prolongation (a heart arrhythmia) in susceptible patients. It has miniscule drug interactions and is generally considered safe in pregnancy.¹⁶⁻¹⁸

Face the Fluoroquinolones

The fluoroquinolone group of systemic antibiotics includes levofloxacin, ciprofloxacin, moxifloxacin and gemifloxacin, colloquially known as the “respiratory fluoroquinolones,” for their excellent *Strep. pneumoniae* coverage. The ophthalmic fluoroquinolones are also divided into two categories. The earlier-generation topical agents include ciprofloxacin and ofloxacin. The newer “fourth-gen-



This 28-year-old patient's redness is due to hordeolum and cellulitis.

Table 4. Penicillin Allergy Quick Facts¹²⁻¹⁴

- The natural penicillins—penicillin G and penicillin VK—are more allergenic than other penicillins.
- A true, life-threatening penicillin type-1 hypersensitivity reaction is rare, and is estimated at one to five per 10,000 cases of penicillin therapy.
- Parenteral rather than oral administration is more likely to cause an allergic reaction.
- Amoxicillin is most likely to cause a rash when inappropriately used to treat a viral illness.

eration” topical fluoroquinolones include besifloxacin, moxifloxacin, levofloxacin and gatifloxacin.²²⁻²⁶

Ciprofloxacin. This earlier-generation agent is another frequently used oral fluoroquinolone. While it no longer provides reliable *Strep. pneumoniae* coverage, it does have relatively good efficacy against *Pseudomonas aeruginosa*. Both ciprofloxacin and levofloxacin have decent coverage against *Haemophilus influenzae* but no appreciable MRSA coverage.

Levofloxacin. Due to the differences in spectrum of coverage between ciprofloxacin and levofloxacin, ocular infections are generally treated with levofloxacin

if and when a fluoroquinolone is necessary. If a pseudomonal infection is suspected or confirmed, consider ciprofloxacin instead. While levofloxacin may have sufficient pseudomonal coverage, it should be reserved for gram-positive infections to decrease potential resistance issues.^{11,19-26}

Gemifloxacin and moxifloxacin. As members of the “respiratory fluoroquinolone” group, gemifloxacin and moxifloxacin have bacterial coverage similar to levofloxacin. Occasionally, a *Strep. pneumoniae* isolate may be more sensitive to one agent than another in this group; however, they are generally considered fairly equivalent from an empiric treatment perspective. In some situations levofloxacin and moxifloxacin may have slightly broader coverage against highly resistant *Strep. pneumoniae* species. While less well known, both gemifloxacin and levofloxacin are generally considered interchangeable with levofloxacin in the management of gram-positive infections. Levofloxacin has slightly improved gram-negative activity.^{20,21,27,28}

These drugs are bacterial DNA synthesis inhibitors. It's generally accepted that fluoroquinolones have chelation drug interactions, which result in a decrease in systemic absorption when the drug is given with di- and trivalent cations (e.g., multivitamins, calcium, iron). As such, any dietary supplements that are cations should be given either two hours prior or four hours after the fluoroquinolone.¹⁹⁻²⁶

Adverse effects associated with fluoroquinolone antibiotics are perhaps their most notable drawback. They are generally contraindicated in pregnancy, breastfeeding and in children younger than 18 years old, due to the corresponding risk of

Earn up to
18-29 CE
Credits*

NEW TECHNOLOGIES
& TREATMENTS IN
2018 EYE CARE



REVIEW OF OPTOMETRY®
EDUCATIONAL MEETINGS OF CLINICAL EXCELLENCE

2018 MEETINGS



Program Chair:
Paul Karpecki, OD, FAO

APRIL 26-29, 2018

SAN DIEGO, CA**

San Diego Marriott Del Mar

www.reviewofoptometry.com/sandiego2018

MAY 17-20, 2018

ORLANDO, FL

Disney's Yacht & Beach Club

www.reviewofoptometry.com/orlando2018

NOVEMBER 2-4, 2018

ARLINGTON, VA

The Westin Arlington Gateway

www.reviewofoptometry.com/arlington2018

Visit our website for the latest information:

www.reviewofoptometry.com/events

email: reviewmeetings@jobson.com | call: 866-658-1772

Administered by
Review of Optometry®



*Approval pending



**15th Annual Education Symposium
Joint Meeting with NT&T in Eye Care

Review of Optometry® partners with Salus University for those ODs who are licensed in states that require university credit.
See Review website for any meeting schedule changes or updates.

Table 5. Oral Fluoroquinolone Dosing

Levofloxacin	500mg daily x 10 days
Moxifloxacin	400mg daily x 10 days
Gemifloxacin	320mg daily x 5 days*
Ciprofloxacin	500mg to 750mg BID x 10 days**

* Coverage for resistant *S. pneumoniae* may not be sufficient.^{20-21,27-28}
 ** Choose only if *P. aeruginosa* is suspected or documented.¹⁹⁻²¹

arthropathy.^{20,21} Photosensitivity of the skin, resulting from all fluoroquinolones (and QT prolongation from the respiratory fluoroquinolones) are listed as potential side effects for these agents as well.^{20,21}

Additionally, the risk of tendon rupture in the shoulder and Achilles has been well documented; it seems more likely to occur in elderly patients and in those taking systemic corticosteroids.³¹ While practitioners once suspected a correlation between fluoroquinolone use and the presence of a

retinal detachment, newer research has debunked this.³⁶ Additional research and clinical anecdotes will further determine the severity of this risk.^{32,33}

The expanding role of the optometrist requires a multi-dimensional perspective on the treatment of infections that typically require systemic therapy. Additionally, staying current on resistance patterns, drug interactions and side effects is critical to one's ability to choose the appropriate agent as well as one that will best encourage patient compliance. ■

Dr. Offerdahl-McGowan is an assistant professor of biomedicine at Salus University.

Dr. Caldwell is an ocular disease consultant in Duncansville and Johnstown, PA, and a past president of the Pennsylvania Optometric Association.

A Word About Resistance

Antibacterial resistance has been a concern since World War II, when we saw our first global distribution of penicillin. At the core of this problem lies the inability of practitioners to recognize how their individual prescribing practices can and will directly impact the future success or failure of antibiotics.

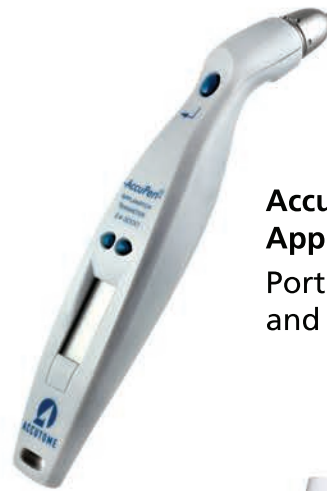Additionally, evolving organisms are growing resistant to antibiotics much faster than the rate at which we are able to produce new antibiotics to fight them. As physicians, it's our responsibility to practice discretion when managing infectious diseases, in hopes of preventing—at all costs—the rise of antibiotic-resistant organisms. This should be done by avoiding the use of antibiotics for infections that are likely of viral origin and by choosing narrow-spectrum antibiotics at therapeutic doses for appropriate durations of treatment.^{34,35}

- Morrow G, Abbott R. Conjunctivitis. *Am Fam Physician*. 1998;57(4):735-46.
- Colgan RC, Powers JH. Appropriate antimicrobial prescribing: approaches that limit antibiotic resistance. *Am Fam Physician*. 2001;64(6):999-1005.
- Spear C, Obenchain M. When a drop isn't enough. *Rev Optom*. 2015;152(1):38-44.
- Kabat A, Sowka J. Style vs. Styte. *Rev Optom*. 2016;153(3):111-3.
- Greenberg R, Dippold A. Current Diagnosis & Treatment: Emergency Medicine, 8 Ee. Eye emergencies. In: Stone K, Humphries R, eds. New York, NY: McGraw-Hill;2017.
- Vagefi MR. Lids and Lacrimal Approachs. Vaughan & Asbury's General Ophthalmology, 19 e. In: Riordan-Eva P, Augsburger J, eds. New York, NY: McGraw-Hill;2017.
- Carlisle R, Digiovanni J. Differential diagnosis of the swollen red eyelid. *Am Fam Physician*. 2015;92(2):106-12.
- Borgman CJ. Proteus mirabilis and its role in dacryocystitis. *Optom Vis Sci*. 2014;91(9):230-5.
- Beauduy E, Winston L. Beta-lactam & other cell wall- & membrane-active antibiotics. In: Katzung B, ed. Basic & clinical pharmacology, 14e. New York, NY: McGraw-Hill;2017.
- Hilal-Dandan R, Brunton LL, eds. Penicillins, Cephalosporins, and Other B-Lactam Antibiotics. In: Goodman and Gilman's Manual of Pharmacology and Therapeutics, 2e. New York, NY: McGraw-Hill.
- Frei C, Frei B. Upper respiratory tract infections. In: Pharmacotherapy: A pathophysiologic approach, 9 ed. DiPiro J, Talbert R, Yee G, et al., eds. New York, NY: McGraw-Hill, 2014;2014.
- Bhattacharya S. The facts about penicillin allergy: a review. *JAPTR*. 2010;1(1):11-17.
- Zagursky R, Pichichero M. Cross-reactivity in beta-lactam allergy. *J Allergy Clin Immunol*. 2018;6(1):72-81.
- Macy E. Penicillin and beta-lactam allergy: epidemiology and diagnosis. *Curr Allergy Asthma Reps*. 2014;14(11):476.
- Prematta T, Shah S, Ishmael F. Physician approaches to beta-lactam use in patients with penicillin hypersensitivity. *Allergy Asthma Proc*. 2012;33(2):145-51.
- Hilal-Dandan R, Brunton L, eds. Protein synthesis inhibitors and miscellaneous antibacterial agents. In: Goodman and Gilman's Manual of Pharmacology and Therapeutics, 2e. New York, NY: McGraw-Hill;2013.
- Beauduy C, Winston L. Tetracyclines, macrolides, clindamycin, chloramphenicol, streptogramins, & oxazolidinones. *Basic & Clinical Pharmacology*, 14 e. Katzung, ed. New York, NY: McGraw-Hill.
- Pfizer Labs; Zithromax 250 mg and 500 mg tablets and oral suspension (azithromycin) [prescribing information]. New York, NY: December 2015.
- Beauduy C, Winston L. Sulfonamides, trimethoprim, & quinolones. *Basic & clinical pharmacology*, 14e Katzung B, ed. New York, NY: McGraw-Hill.
- Bayer HealthCare Pharmaceuticals Inc; Cipro (ciprofloxacin) [prescribing information]. Whippany, NJ: July 2017.
- Janssen Pharmaceuticals Inc; Levaquin (levofloxacin) [prescribing information]. Titusville, NJ: February 2017.
- Alcon; Ciloxan (ciprofloxacin) solution [prescribing information]. Fort Worth, TX: March 2006.
- Ocuflox (ofloxacin) [prescribing information]. Irvine, CA: Allergan; February, 2012.
- Akon; Levofloxacin solution [prescribing information]. Lake Forest, IL: December 2010.
- Alcon; Moxeza (moxifloxacin) solution [prescribing information]. Fort Worth, TX: May 2013.
- Allergan Inc; Zymarid (gatifloxacin) solution [prescribing information]. Irvine, CA: January 2014.
- Merus Labs; Factive (gemifloxacin) tablet [prescribing information]. Toronto, Ontario, Canada: May 2016.
- Merck & Co; Avelox (moxifloxacin) [prescribing information]. Whitehouse Station, NJ: September 2016.
- Hilal-Dandan, Brunton L, eds. Sulfonamides, trimethoprim-sulfamethoxazole, quinolones, and agents for urinary tract infections. In: Goodman and Gilman's Manual of Pharmacology and Therapeutics, 2e. New York, NY: McGraw-Hill.
- Pfizer Labs; Vibramycin (doxycycline) oral [prescribing information]. New York, NY: August 2014.
- van der Linden PD, Sturkenboom MCJM, Herring RMC, et al. Increased risk of achilles tendon rupture with quinolone antibacterial use, especially in elderly patients taking oral corticosteroids. *Arch Intern Med*. 2003;163:1801-7.
- Etmian M, Foroghian F, Brophy JM, et al. Oral fluoroquinolone and the risk of retinal detachment. *JAMA*. 2012;307(13):1414-9.
- Marcinak JF, Frank AL. Treatment of community-acquired methicillin-resistant staph aureus in children. *Curr Opin Infect Dis*. 2003;16(3):265-9.
- Quinn R. Rethinking antibiotic research and development: World War II and the penicillin collaborative. *Am J Public Health*. 2013;103(3):426-34.
- Barbosa T, Levy S. The impact of antibiotic use on resistance development and persistence. *Drug Resistance Updates*. 2000;(3):303-11.
- FDA: fluoroquinolones not tied to retinal detachment, aortic aneurysm. *NEJM Journal Watch*. www.jwatch.org/fw112876/2017/05/12/fda-fluoroquinolones-not-tied-retinal-detachment-aortic. May 12, 2017. Accessed March 20, 2018.

Tonometry Done Right



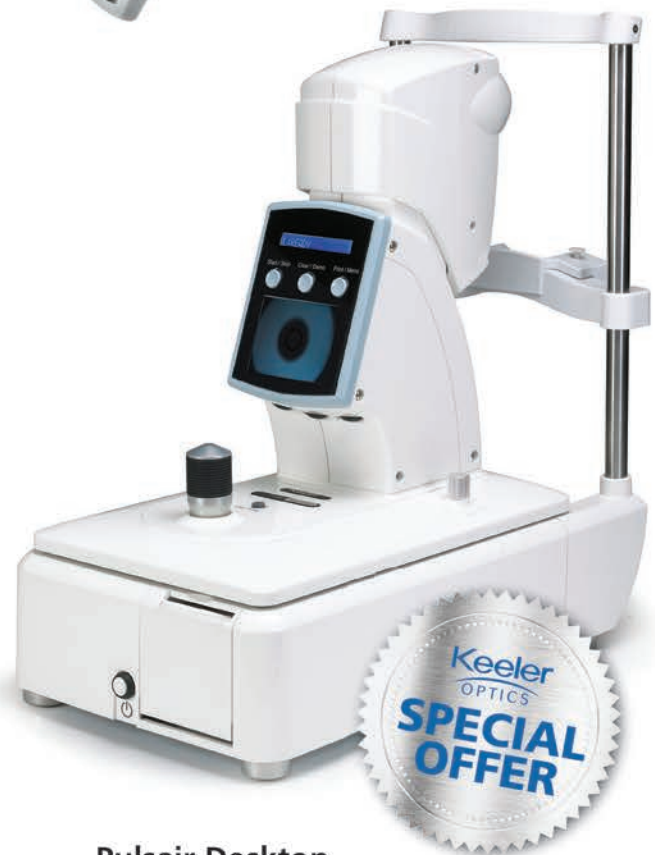D-KAT Digital
Keeler quality.



**AccuPen - Handheld
Applanation Tonometer**
Portable, versatile,
and easy-to-use.



Intellipuff
The standard for hand held mobility.



Pulsair Desktop
Smallest footprint and simple to use!

*Purchase a Pulsair Desktop by
June 30, 2018 and get a \$1,366
Instant Rebate!*

Buy Online!
keelerusa.com

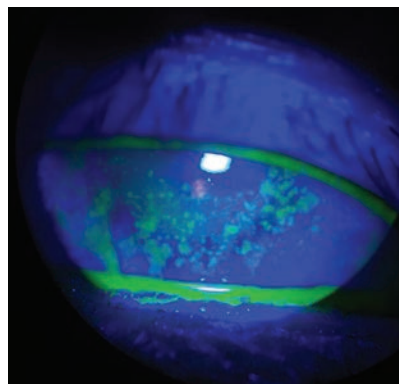
Keeler
OPTICS

Sizing Up Anti-Inflammatories in Dry Eye Disease

A practical guide for optometrists applying these medications. **By Vin Dang, OD**

Dry eye disease (DED) is a multifactorial disorder of the ocular surface that severely impacts vision and quality of life. Risk factors that contribute to DED include age, gender, hormones, autoimmune disorders, local environment, use of video displays, contact lens wear and exposure to medications/preservatives, all potentially leading to secretory or evaporative DED, or both.¹ Inflammation is another key risk factor. The Tear Film and Ocular Surface Society's Dry Eye Workshop II definition recognizes the impact of inflammation, saying, "Dry eye is a multifactorial disease of the ocular surface characterized by a loss of homeostasis of the tear film, and accompanied by ocular symptoms, in which tear film instability and hyperosmolarity, ocular surface inflammation and damage, and neurosensory abnormalities play etiological roles."

With this more finely honed understanding of DED in mind, optometrists must make controlling inflammation a priority. This article will review the optometrist's role in

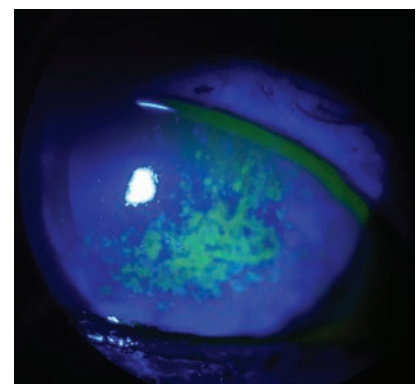


The sodium fluorescein staining used in these patients reveals a compromised corneal surface due to DED.

diagnosing inflammation in the clinical setting, including options to best treat inflammatory dry eye disease with the tools currently available.

Identification and Classification

Inflammation on the ocular surface can be overt or covert in its presence. Conjunctival hyperemia, or redness, is a hallmark of ocular inflammation that can be objectively evaluated by anterior segment photography or with the use of grading scales, such as the Efron Grading Scales.^{2,3} Vital dyes are also valuable



in the detection of ocular surface damage often seen alongside inflammation. The use of sodium fluorescein or lissamine green vital dyes are particularly helpful in identifying and visualizing the devitalized cells on the conjunctiva.

Tear chemistry can also be associated with ocular surface inflammation. Using a system designed to measure tear osmolarity (e.g., TearLab Osmolarity System, or I-Pen [I-Med Pharma]) is one way to quantify inflammation. For patients without inflammation, their hyperosmolarity will read less than

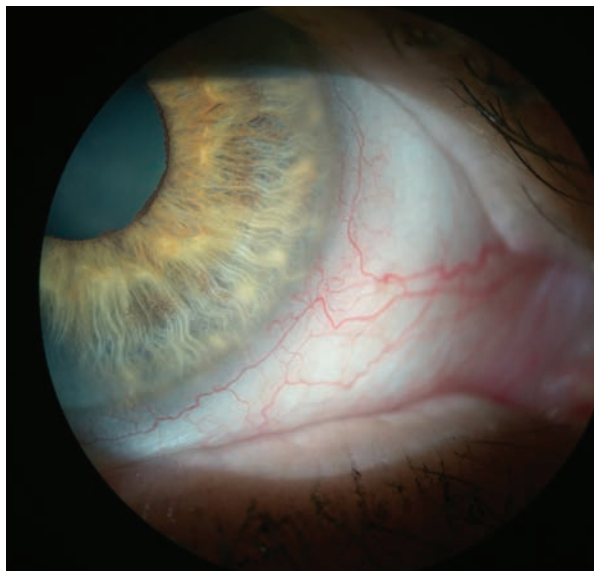300mOsm/L.^{1,4} With this quantification, physicians can engage their patients by providing pretreatment and post-treatment results. Research shows matrix metalloproteinases, specifically matrix metalloproteinase-9 (MMP-9), is a byproduct of inflammation and cell insult and, now that an MMP-9 detection test (e.g., InflammDry Detector, Quidel) is available, we can count that as yet another biomarker of inflammation.^{1,5}

The clinical symptoms of inflammation include end-of-day burning, stinging, dry, irritated, scratchy, watery and itchy eyes.² If a patient presents with these clinical signs and symptoms, therapeutic intervention is indicated. As soon as patients can be categorized as mild-to-moderate—by either exhibiting corneal staining signs, decreased tear film break-up time or complaining of DED symptoms—anti-inflammatory medications are justified.

The Right Stuff

When deciding which anti-inflammatory to use, keep in mind each drug's mechanisms of action.

Corticosteroids act on various inflammatory responses, including intercellular adhesion molecule-1 (ICAM-1)-mediated cell adhesion, cytokines/chemokines/MMPs expression and induction of lymphocyte apoptosis.⁶⁻⁸ Simply put, corticosteroids have a broad-spectrum mechanism of action when it comes to controlling inflammation. However, their long-term use in ocular conditions is not recommended because of steroid-related side-effects such as increased intraocular pressure and cataract formation.⁹



This patient's injected blood vessels indicate inflammation. In this eye, it can be seen without any vital dyes.

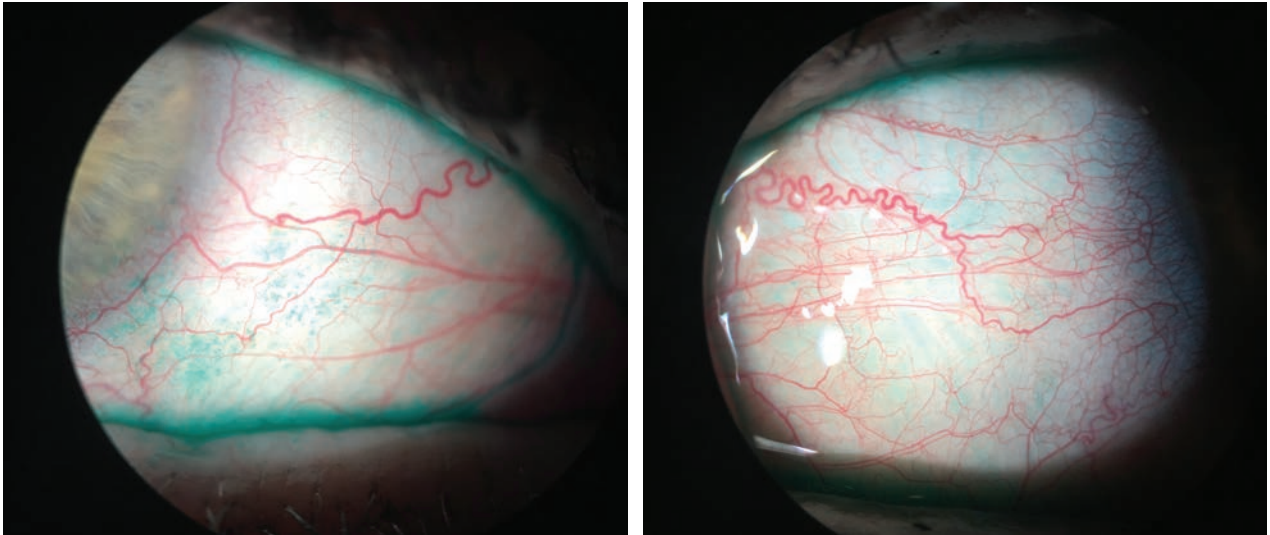
Thankfully, not all corticosteroids are created equal. A “soft” steroid such as loteprednol or fluorometholone could be used for four to six weeks without having to worry about the long-term side effects. Sometimes I will also pulse the soft steroid BID to TID dosage for one week on and two weeks off, then repeat as needed with close clinical follow ups.

Cyclosporine (CsA) is another anti-inflammatory medication used to combat inflammation associated with DED. In a large multicenter study, 0.05% to 0.1% CsA treatment significantly reduced HLA-DR expression and to a lesser extent expression of other inflammatory and apoptotic markers in patients with moderate-to-severe DED.^{10,11} Topical CsA increase goblet cell density and conjunctival production of immunomodulatory transforming growth factor beta-2 (TGF- β 2) in DED patients.¹² In 2003, Restasis (topical cyclosporine 0.05%, Allergan) received approval from the FDA to increase tear production in patients whose tear production is

presumed to be suppressed due to ocular inflammation associated with keratoconjunctivitis sicca.¹ Because of the mechanism of action of CsA, the anti-inflammatory effects usually won't take place until after at least four to six weeks of starting therapy.^{10,11} This won't be the best medication to use if you have a patient with acute inflammation. Also because of the immunomodulator properties of CsA, it is a good option to treat autoimmune disease associated dry eyes, such as Sjögren's syndrome.

Lifitegrast is an anti-inflammatory drug that was approved by the FDA in 2016 for the treatment of the signs and symptoms of DED. Xiidra (topical lifitegrast 5%, Shire) is the first dry eye medication that targets integrin signaling as a lymphocyte function-associated antigen-1 (LFA-1) antagonist that blocks coupling of LFA-1 and ICAM-1.¹³ LFA-1 is found on the surface of the T-cell. By blocking the interaction between LFA-1 and ICAM-1, it is thought that one of the inflammatory cycle is prevented. In the OPUS-1 clinical study, there was a significant improvement in signs such as inferior corneal staining, but not in symptoms.¹⁴ The subsequent OPUS-2 study established significant improvement in the eye dryness score, and this was confirmed in OPUS-3.^{15,16} Symptomatic relief occurred as early as two weeks after initiating treatment for patients with moderate DED.

After determining the severity of the inflammation in a DED patient, whether by having a positive response to the InflammDry test, or by simply grading the clinical signs; the optometrist can then decide if a



The lissamine green staining here highlights the devitalized cells on the conjunctiva, which indicate ocular surface disease.

topical steroid is needed to quickly decrease the overall inflammation along with either Restasis or Xiidra. If the inflammation is particularly severe, you might consider using a soft steroid with both Restasis and Xiidra together, as their mechanisms of action are different. However, if the inflammation isn't so severe it requires a topical steroid, lifitegrast (for faster symptom relief) and CsA (if the patient has autoimmune disease associated DED) without the steroid is acceptable.

Complementary Treatments

Controlling inflammation is a vital step in reducing DED symptoms, but optometrists can also treat mechanical issues that can be (but aren't always) the root cause of dry eye. For instance, patients with meibomian gland dysfunction have obstructed glands and may be able to find relief once they are unclogged. A conservative approach involves using heat therapy in the form of a warm compress that is directly applied to the lids to try to reduce the viscosity of the meibum within. A more aggressive approach involves in-office treatments, such

as Lipiflow (TearScience), a thermal pulsation device that simultaneously heats the meibum and pulsates to liberate the melted meibum out of the glands.

Diet is another aspect in which we can directly affect the level of inflammation in the eye. Oral supplementation with omega-3 polyunsaturated fatty acids, eicosapentaenoic acid or docosahexaenoic acid found in fish oil all decrease the production of pro-inflammatory mediators, such as prostaglandin E2, and cytokines.¹⁸ Gamma-linolenic acid (GLA) is also an omega-6 with anti-inflammatory properties.¹⁹ HydroEye (Science Based Health) provides the necessary GLA formulation through black currant seed oil.

Another contributor to inflammation is blepharitis from the lids.²⁰ The etiology of the condition is not fully understood, but low-grade bacterial infection (primarily *Staphylococcus*), *Demodex* mites, environmental factors and certain systemic disease have all been implicated as potential contributors.²⁰

The Combo Approach

Topical antibiotic-corticosteroid

combination products are useful for decreasing the bacterial load as well as managing the inflammation.²⁰ Concerns of antibiotic resistance and long-term exposure to the corticosteroids comes to mind when using these type of medications. After a short course of a topical antibiotic-corticosteroid combo medication, you may want to switch the patient to a type of hypochlorous acid (HOCl) cleanser such as Avenova (NovaBay) or Acucyn (Sonoma Pharmaceuticals) to keep the bacterial levels at bay.²¹ HOCl is a natural product made by neutrophils to kill microorganisms.²² Oral doxycycline is another tool that can be used to control inflammation via MMP suppression.²³ A maintenance dose of 50mg BID can be prescribed for up to three months to try to control the inflammation systemically.

Topical steroids should not be used long-term without frequent monitoring because of the potential side effects. They can be used initially to control the acute stage of inflammation and then tapered off. CsA in the form of Restasis is safe to use long term but requires contin-

25TH ANNUAL **OPHTHALMIC** *Product Guide*

ued use to achieve its anti-inflammatory properties and also can take up to two months before noticing any improvement in DED symptoms.²⁴ Xiidra is also safe to use long term and can work on the current inflammatory response for faster resolution.^{15,16} ■

Dr. Dang is an optometrist practicing in a multi-speciality eye clinic in Bakersfield, California. His clinical practice covers a broad spectrum of ocular care with a unique clinical focus on ocular surface disease and dry eye.

1. Baudouin C, Irkeç M, Messmer E, et al. Clinical impact of inflammation in dry eye disease: proceedings of the ODISSEY group meeting. *Acta Ophthalmol.* 2018 Mar;96(2):111-119.
2. TFOS International Dry Eye WorkShop (DEWS II). *Ocular Surf.* 2017;15(6):269-650.
3. McMonnies CW & Ho A (1991): Conjunctival hyperaemia in non-contact lens wearers. *Acta Ophthalmol (Copenh)* 69: 799-801.
4. Sullivan B, Whitmer D, Nichols KK et al. (2010): An objective approach to dry eye disease severity. *Invest Ophthalmol Vis Sci.* 2010 Dec;51(12):6125-30.
5. Luo L, Li DQ, Doshi A, et al. Experimental dry eye stimulates production of inflammatory cytokines and MMP-9 and activates MAPK signaling pathways on the ocular surface. *Invest Ophthalmol Vis Sci.* 2004 Dec;45(12):4293-301.
6. Pflugfelder S. Antiinflammatory therapy for dry eye. *Am J Ophthalmol.* 2004;137(2):337-42.
7. De Paiva C, Corrales R, Villarreal A, et al. Corticosteroid and doxycycline suppress MMP-9 and inflammatory cytokine expression, MAPK activation in the corneal epithelium in experimental dry eye. *Exp Eye Res.* 2004;83:526-35.
8. Yagci A, Gurdal C. The role and treatment of inflammation in dry eye disease. *Int Ophthalmol.* 2014;34:1291-301.
9. Marsh P, Pflugfelder SC. Topical nonpreserved methylprednisolone therapy for keratoconjunctivitis sicca in Sjogren syndrome. *Ophthalmology.* 1999;106:811-6.
10. Brignole F, Pisella P, De Saint Jean M, et al. Flow cytometric analysis of inflammatory markers in KCS: 6-month treatment with topical cyclosporin A. *Invest Ophthalmol Vis Sci.* 2001;42: 90-5.
11. Galatoire O, Baudouin C, Pisella P. Flow cytometry in impression cytology during keratoconjunctivitis sicca: effects of topical cyclosporin A on HLA DR expression. *J Fr Ophthalmol.* 2003;26:337-43.
12. Pflugfelder S, De Paiva C, Villarreal A, Stern M. Effects of sequential artificial tear and cyclosporine emulsion therapy on conjunctival goblet cell density and transforming growth factor-beta2 production. *Cornea.* 2008;27:64-9.
13. Perez VL, Pflugfelder SC, Zhang S, et al. Lifitegrast, a novel integrin antagonist for treatment of dry eye disease. *Ocul Surf.* 2016;14(2):207-15.
14. Sheppard J, Torkildsen J, Lonsdale J, et al. Lifitegrast ophthalmic solution 5.0% for treatment of dry eye disease: results of the OPUS-1 phase 3 study. *Ophthalmology.* 2014;121(2):475-83.
15. Tauber J, Karpecki P, Latkany R, et al. Lifitegrast ophthalmic solution 5.0% versus placebo for treatment of dry eye disease: results of the randomized phase III OPUS-2 study. *Ophthalmology.* 2015;122(12):2423-31.
16. Holland E, Luchs J, Karpecki P, et al. Lifitegrast for the treatment of dry eye disease: results of a phase III, randomized, double-masked, placebo-controlled trial (OPUS-3). *Ophthalmology.* 2017;124(1):53-60.
17. Nichols K, Foulks G, Bron A, et al. The international workshop on meibomian gland dysfunction: executive summary. *Invest Ophthalmol Vis Sci.* 2011;52(4):1922-9.
18. Kelley D, Taylor P, Nelson G, et al. Docosahexaenoic acid ingestion inhibits natural killer cell activity and production of inflammatory mediators in young healthy men. *Lipids.* 1999;34:317-324.
19. Sheppard JD, Singh R, McClellan AJ, et al. Long-term Supplementation With n-6 and n-3 PUFAs Improves Moderate-to-Severe Keratoconjunctivitis Sicca: A Randomized Double-Blind Clinical Trial. *Cornea.* 2013;32(10):1297-304.
20. American Academy of Ophthalmology. Preferred Practice Pattern: Blepharitis. September 2013 revision. www.aaopt.org/preferred-practice-pattern/blepharitis-ppp-2013. Accessed March 25, 2018.
21. Romanowski E, Stella N, Yates K, et al. *In Vitro* Evaluation of a Hypochlorous Acid Hygiene Solution on Established Biofilms. *Eye Contact Lens.* www.ncbi.nlm.nih.gov/pubmed/29369234. Accessed March 25, 2018.
22. Wang G, Nauseef W. Salt, chloride, bleach, and innate host defense. *J. Leukoc Biol.* 2015;98:163-72.
23. Geerling G, Tauber J, Baudouin C. The international workshop on meibomian gland dysfunction: report of the subcommittee on management and treatment of meibomian gland dysfunction. *Invest Ophthalmol Vis Sci.* 2011;52(4):2050-64.
24. Kymionis GD, Bouzoukis DI, Diakonis VF, et al. Treatment of chronic dry eye: focus on cyclosporine. *Clin Ophthalmol.* 2008 Dec;2(4):829-36.

Innovative products to
enhance your practice



The future
is in your
hands. One
tap, many
possibilities.

Experience the digital edition on
your handheld device. Use your
smart device to scan the code
below or visit:

www.reviewoptometry.com/publications/archive

Download a QR scanner app. Launch app and hold your
mobile device over the code to view
<https://www.reviewoptometry.com/publications/archive>



REVIEW[®]
OF OPTOMETRY



PROTOCOLS AND PITFALLS IN TOPICAL STEROID USE

It's always a balancing act between benefit and side effects. Here's how to keep patients safe while treating with steroids. **By Aaron Bronner, OD, and Walter O. Whitley, OD, MBA**

Topical corticosteroids are the most frequently prescribed class of ophthalmic agents by optometrists across the United States. In 2013, topical corticosteroids (including steroid/antibiotic combination agents) accounted for a little more than 50% of ophthalmic prescriptions written by ODs.¹ Steroids were prescribed three times more frequently than topical antibiotics, topical antivirals and topical nonsteroidal anti-inflammatory drugs (NSAIDs) combined.¹ And it's no wonder we like these drugs, given their mechanism of action. Because essentially all nucleated cells in the body express receptors for these molecules, corticosteroids have a sweeping effect across many tissues.^{2,3}

Regardless of dosing strategy (systemic or local), the therapeutic goal of corticosteroids is to limit the immune response via the phospholipid A2 pathway. Because of their wide range of target cells, corticosteroids have the broadest, but least specific, effect on inflammation of any immune modulatory agent.⁴

When dosed orally for systemic therapy, these agents reduce differentiation and maturation of immune cells within primary immune tissue, as well reduce the expression of pro-inflammatory cytokines and chemokines peripherally.⁴ When dosed topically, steroids don't influence immune-cell maturation, but the effect on cytokines, chemokines and other pro-inflammatory molecules—an extremely robust

mechanism of action—is preserved.⁴ By reducing the production of this legion of inflammatory mediators, locally dosed corticosteroids reduce several actions, including: vascular permeability to immune cells, the recruitment of other immune cells to that site, tissue breakdown, histamine release and subsequent edema, angiogenesis and fibroblast activation (which results in scar tissue), among other consequences.⁴

With these broad effects and their trickle-down clinical benefits, treating everything from ocular surface disease to uveitis, it's easy to see why corticosteroids are such a favorite of the profession. However, although steroids are quite effective at addressing inflammation, they can cause complications. Common side effects

Release Date: March 2, 2018

Expiration Date: March 2, 2021

Goal Statement: Topical corticosteroids can be a useful treatment strategy for everything from ocular surface disease to uveitis—but they can cause complications, and clinicians must account for their side effects. To better prepare clinicians to prescribe these agents safely, this article reviews the known side effects of ophthalmic corticosteroids, appropriate use and dosing-based differences among target tissues.

Faculty/Editorial Board: Aaron Bronner, OD, and Walter Whitley, OD, MBA

Credit Statement: This course is COPE approved for 2 hours of CE credit. Course ID is **57000-PH**. Check with your local state licensing board to see if this counts toward your CE requirement for relicensure.

Disclosure Statements:

Authors: Dr. Bronner has no relationships to disclose. Dr. Whitley has a relationship with Alcon, Allergan, Bausch + Lomb, BioTissue, Carl Zeiss Meditec, Glaukos, TearScience, TearLab, Johnson & Johnson, OcuSoft and Beaver Visitec.

Editorial staff: Jack Persico, Rebecca Hepp, William Kekevia, Francesca Crozier-Fitzgerald and Michael Iannucci all have no relationships to disclose.

of oral prednisone include increased intraocular pressure (IOP), cataract formation, mood changes and increased blood sugar levels. These are not associated directly with the desired mechanism of these agents and are truly unintended; with increased IOP possibly leading to irreparable vision loss via glaucoma, it's particularly worrisome.

Another negative effect of steroid use is not an unexpected adverse event, but a predictable effect based on the mechanism at play. Because the primary effect of corticosteroids is limiting the immune response, their use may result in worsening of any condition where the immune response is needed (i.e., an infectious process). Unfortunately, although this effect can potentially lead to catastrophic vision loss, it is often under-recognized by the profession.

To better prepare clinicians to prescribe these agents safely, this article reviews the known side effects of ophthalmic corticosteroids, particularly within the cornea, their appropriate use and dosing-based differences among target tissues.

Intraocular Pressure

Elevation in IOP is the most frequently observed side effect of ophthalmic steroid use, occurring in 18% to 36% of patients.⁵ Regardless of the specific steroid being used, this response is more likely to occur with prolonged dosing and has been observed in higher frequency in glaucoma suspects and patients.⁶ Research suggests the mechanism likely involves the alteration of the trabecular meshwork's (TM) outflow efficacy via increased deposition of extracellular matrix within the TM.⁷ This is usually transient, though recalcitrant steroid-induced ocular hypertension is possible.

Ophthalmic steroid preparations come in varying strengths with equally varying risks of IOP eleva-

tion. For example, loteprednol 0.5%, rimexolone 1% and fluorometholone 0.1% are associated with a lower risk of steroid response, a lower peak pressure when a response occurs and a slower time to peak compared with dexamethasone phosphate 0.1% or prednisolone acetate 1%.⁸⁻¹⁰

The mechanism by which these steroids achieve their increased safety differs slightly between medications. In fluorometholone 0.1% and rimexolone 1%, lipophilicity plays a large part in reducing IOP spikes, as the medications don't penetrate the cornea due to biphasic nature, thereby lowering the potential for spikes.^{11,12} Phosphate preparations, as hydrophilic solutions, penetrate the epithelium poorly, which may be ideal for ocular surface conditions.^{11,12}

Hydrophobic alcohol-based and acetate suspensions, however, should theoretically be more adept at penetrating all layers of the cornea. Loteprednol achieves its enhanced safety, in part, from its reduced half-life in the anterior chamber as an ester-steroid, which reduces adverse drug reactions. The newest topical steroid, difluprednate 0.05%, seems to have the highest anti-inflammatory potency.¹³ This comes at a cost, however, as research shows the medication can cause the most extreme and most rapid IOP responses.¹⁴

Cataract Development

The literature shows significant variability in cataract formation in patients on systemic steroids, as between 6.5% and 38.7% of patients on them develop cataracts.¹⁵ Further research reveals varying associations with cataract and inhaled steroid compared with perinatal dosing.¹⁵ Whether topical, oral or inhaled, steroids are commonly

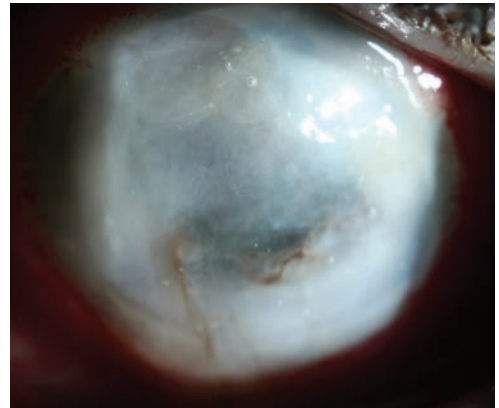


Photo: Jeff Urness, OD

This fulminant corneal ulcer was initially treated with Tobradex.

associated with posterior subcapsular cataracts.¹⁵ Surprisingly, however, there is little to no peer-reviewed information regarding rates of cataract development with ophthalmic corticosteroids overall, let alone among specific agents.

Because of loteprednol's soft drug design, research suggests it has a reduced potential to cause cataracts; however, this claim seems to be based on one retrospective review of 159 patients, none of whom developed cataracts while using loteprednol 0.2% for more than a year.¹⁶

Although the differences in the potential to cause cataracts among individual agents are still unknown, we do know that chronic topical steroid use, at least in cohorts with chronic intraocular inflammation, is associated with cataract formation—with greater dose frequency associated more frequently than lesser dosages.¹⁷ Practitioners can reasonably predict that long-term topical steroid use follows the same trends seen in IOP response among specific agents: those that don't penetrate into the anterior chamber well and those that have a short half-life (fluorometholone, rimexolone and loteprednol) can be expected to produce cataracts at a lower rate than more potent steroids (prednisolone, dexamethasone and difluprednate).

Selection and Dosing

When dosing corticosteroids for inflammation of the ocular surface, select a poorly penetrating agent (fluorometholone or rimexolone) or soft drug corticosteroid such as loteprednol to reduce risk of complications.

When inflammation is in the anterior chamber or deeper cornea, the selected agent should balance with the degree of anti-inflammatory effect necessary. For mild to moderate inflammation, loteprednol is a good option, and more severe cases may do well with prednisolone acetate 1%. In particularly severe cases of corneal or anterior chamber inflammation, the only topical medication we've had success with is difluprednate; otherwise, you're on to sub-Tenon's dosing or systemics.

Excess steroid use can be nearly as harmful as chronic inflammation and is of particular concern with long-term management of inflammation as seen in chronic keratitis (as seen occasionally with herpes zoster ophthalmicus), prevention of corneal graft rejection and cases of chronic uveitis. When deep penetration is unnecessary but chronic therapy is expected, a more superficially acting steroid is appropriate, and in all cases the lowest dose that fully controls inflammation should be used.

With more substantial steroids and the increased potential for steroid complications over an abbreviated time frame, the follow-up interval should be appropriately reduced.

Immune Response and Tissue Function

Beyond the capacity for creating IOP spikes and cataracts, steroid use comes with tissue-specific precautions. Optometrists typically prescribe corticosteroids for three primary anatomic zones: the ocular surface (including lids, conjunctiva, episclera and corneal epithelium), the non-superficial corneal layers and

the anterior chamber. Steroid use for each of these zones carries a risk for the development of cataracts and glaucoma, depending on the specific agent and duration of treatment. The risks also differ based on the consequences of potentiating infection.

Conjunctiva. True conjunctival infections, with the exception of hyper-acute conjunctivitis, can generally be treated with corticosteroids with near impunity and without fearing induction of vision-threatening escalation of the disease. The reason for this has to do with the tissue function, its role in vision and the normal immune response.

A mucous membrane, the conjunctiva is essentially a watershed between the external and internal environments. As with all mucous membranes, one of the conjunctiva's primary functions is to act as a barrier. The most effective barrier tissue of the body is the skin. Non-nucleated, keratinized tissue, which makes up the most external layer of the skin, creates a robust physical barrier to microbes and is able to repel most infections. In fact, it is nearly impossible for a virus to infect healthy, uncompromised skin.¹⁸

As a mucous membrane without the benefit of keratinized tissue, the conjunctiva is at a disadvantage relative to the skin at preventing infection; therefore, infectious conjunctivitis is more likely than infectious dermatitis. These conjunctival infections, however, are almost always self-contained and have minimal long-term consequences because what the conjunctiva lacks in keratinized tissue it makes up for with immediate access to the immune response. The conjunctiva is host to secondary lymphoid tissue (conjunctiva-associated lymphoid tissue), has a rich vascular supply and, further, is not directly responsible for visual function—allowing some tissue damage without impact on function.¹⁹

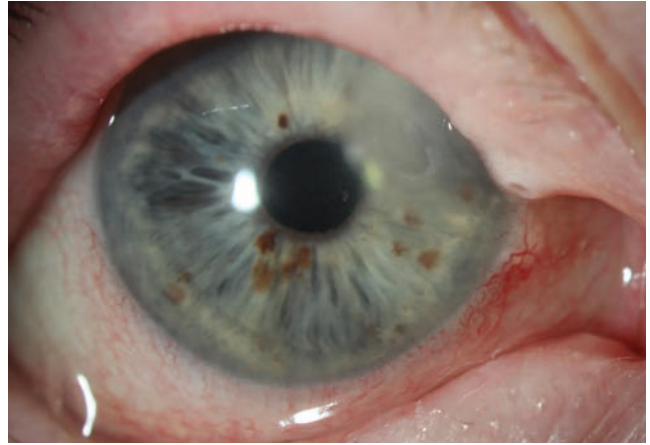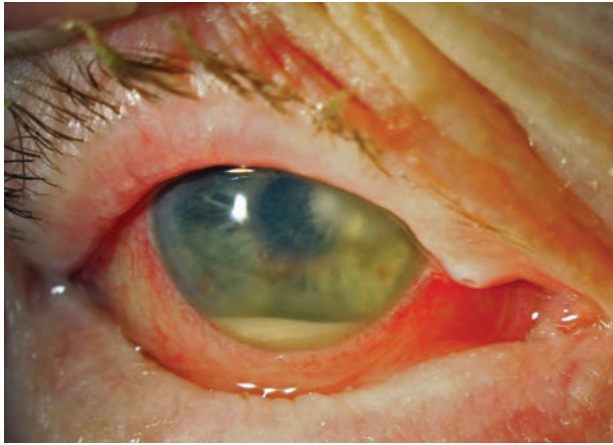
Due to the conjunctiva's immediate access to the immune response, topical steroid use may reduce the degree of the conjunctival immune response without eliminating it entirely. Steroids can be a useful adjunct in the therapeutic and palliative management of both inflammatory and infectious conjunctivitis by reducing unnecessary inflammation that can lead to pain, conjunctival fibrosis, destruction of goblet cells and symblepharon formation.

Clinicians must remember that infectious conjunctivitis should be preferentially treated with anti-infective medications. Still, it may be difficult to differentiate infectious from non-infectious, and given the access to local immune response, treatment of a localized infectious conjunctivitis with steroid will not lead to profound tissue destruction, unlike that which may occur within the cornea. Thus, combination drops (paired antibiotic/corticosteroid) are safe and effective in most cases.

Likewise, anterior uveitis stemming from disseminated systemic infections such as tuberculosis, syphilis, Lyme disease and leprosy may be treated with topical corticosteroids without risk of exacerbating the underlying disease process. Of course, these patients all need systemic anti-infectives to cure their disease, but topical steroids are safe, may enhance treatment by reducing inflammatory sequelae and may reveal an infectious etiology if you see an incomplete clinical response to anti-inflammatory treatment.

Although the uveitis generated by these etiologies often exhibits an incomplete response to topical corticosteroids, topical steroid use is always appropriate front-line therapy for cases of anterior uveitis.²⁰

The same cannot be said for systemic steroid use for cases of infectious uveitis, however. Though systemic corticosteroid agents may



When an ulcer requires steroids, they should be introduced cautiously. This *Moraxella catarrhalis* ulcer, at left, was treated for one week with medication that it was sensitive to (per culture results) and improved, but only slowly. It wasn't until a steroid was cautiously introduced that the eye totally quieted, at right. In this case, having a culture result in hand to ensure appropriate antimicrobial treatment made the subsequent addition of a steroid a reasonable step to take.

be indicated on a case-by-case basis for infectious disease management (shingles treatment is often supplemented with oral prednisone, and some severe leprosy-related immune reactions necessitate their use), they should not be used for all cases. They have been known to exacerbate the underlying disease and possibly even lead to death.²¹

When using topical agents to control a severe uveitis, clinicians should not shy away from strong initial dosing. Anecdotally, treating uncontrolled anterior uveitis with prednisolone acetate 1% QID often meets with predictably minimal success. In cases of moderate to severe acute anterior uveitis, clinicians should prescribe frequent, often hourly, dosing of a strong steroid such as difluprednate, which has been shown to be non-inferior to prednisolone acetate for anterior uveitis when dosed half as frequently, and only taper gradually once inflammation is totally controlled.²²

Cornea. Corticosteroids are often necessary to facilitate a good, prompt resolution of corneal pathology; however, when used incorrectly they may result in catastrophic vision loss. The specific implications and risks

associated with steroid use in the cornea revolve around the cornea's function and immune response.

The cornea has two primary functions: an optical interface that transmits and refracts light and a barrier to the external environment. However, maintenance of one sets up challenges for the other. The external cornea is part of the ocular surface mucous membrane; however, unlike most other mucous membrane-derived tissue, the cornea has no local lymphoid tissue, few native immune cells and no local vascular supply. Presence of any of these at high levels would enhance corneal barrier function through increasing access to the immune response, but would result in a loss of corneal clarity and reduced optical function. However, the absence of these features from the central cornea limits the cornea's ability to function as a barrier. If the cornea develops an infection, the immune system is initially unable to help, which allows for early unfettered proliferation of the microbe.

Once an immune response is mounted, corneal optical function is sacrificed to preserve the barrier function, as resultant inflammation

often contains the infection at the expense of a corneal scar. Because of the inherent antagonism of the cornea's barrier and optical functions, which are precariously balanced in a healthy eye and are thrown out of balance in an infected cornea, the use of corticosteroid in infected corneas has significant possible ramifications.

A now somewhat frequently encountered misconception is that the Steroid for Corneal Ulcers Trial (SCUT) shows no benefit or harm in the adjunctive use of corticosteroids for corneal ulcers; therefore, some think we can use steroids for corneal pathology with impunity.²³ This is a dangerous clinical mindset and a misinterpretation of the SCUT study and its findings. The study does not show there was no benefit or harm in the use of corticosteroids for corneal ulcers. It shows, instead, no benefit or harm with *light use* of corticosteroid (prednisolone phosphate 1% QID for one week, BID for one week, then QD for one week) in the management of bacterial keratitis when attempts were made to sterilize the cornea prior to institution of steroid.²³ All patients in this study were placed on moxifloxacin hourly for two days prior to being grouped

into steroid plus antibiotic group or antibiotic plus placebo groups.²³ Therefore, conservative steroid use as an adjunct therapy only follows SCUT protocol when attempts to sterilize the cornea are made prior to initiation of steroid use—a critical distinction.²³

Due to the lack of immune response held by the central cornea, further suppression of it with corticosteroids prior to ensuring an effective antimicrobial sterilization (as assessed with a positive response to therapy) may result in spread of the ulcer and treatment failure. In addition, while the SCUT study was inconclusive on conservative use of corticosteroid in bacterial keratitis following an attempt at sterilization, we know from other retrospective reviews that steroid use with corneal ulcers increases the likelihood of progression towards outcomes requiring surgical management. More than 50% of patients from one series on infectious keratitis that went on to require keratoplasty had been on previous steroid (compared with 18% of the ulcers that did not require surgery).²⁴ Likewise, nearly 25% of patients in another study on eyes requiring enucleation or evisceration for infectious keratitis

had been on topical corticosteroids.²⁵ These outcomes are critical to guard against; thus, the cavalier use of corticosteroids must be avoided when dealing with corneal pathology.

While most eye care providers know to avoid corticosteroid use with infectious keratitis except in an extremely conservative manner, the same is not always true with combination therapies, often prescribed for “mystery keratitides.” These have the most potential to do harm because of the flawed assumption that the antibiotic agent in the combo drop covers against infection while the anti-inflammatory covers for inflammation. In the central and paracentral cornea, the absent native immunity may not allow low-dose antibiotics to cover for the deleterious effects of the steroid when faced with an infectious challenge. Tissue concentrations of the antibiotic in these agents may be insufficient to slow colonization of the offending microbe, and the immune suppressing effect of the steroid may allow further spread by reducing immune cell migration and clearance of the infection. These possibilities are particularly concerning given that, in this setting, any worsening of infection may lead to a permanent worsening in vision.

It is crucial to know the corneal pathology you are dealing with prior to initiating combination or steroid therapy for any keratitis. Anecdotally, a good rule of thumb is to avoid using a steroid for any isolated ulcerative process of the central and paracentral cornea. If you have an infiltrate and an epithelial defect, it’s

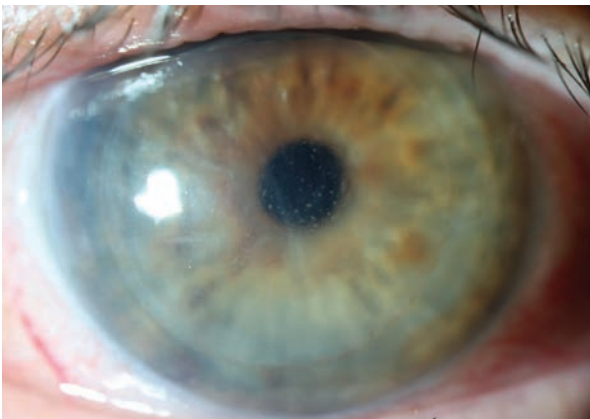likely you are dealing with an infectious process.

The possible exception to this rule is a lesion in the far corneal periphery, as these are typically hypersensitivity/immune-mediated reactions, which will respond well to combination drops. In the rare event a far peripheral ulcer is infectious—which is uncommon near the limbus—proximity to the immune response will generally prevent dramatic escalation until initiating more appropriate therapy. Additionally, scarring in the far periphery is much less likely to cause reduced vision.

Though we aren’t promoting cavalier use of steroid on peripheral corneal pathology, the immunology and function of the peripheral cornea allows for more forgiveness in outcomes, should your treatment be incorrect. As with all corneal pathology, follow-up should be short when introducing a steroid to identify any worsening. For non-peripheral keratitis, stromal inflammation that is small, non-ulcerated and multifocal (i.e., contact lens-associated red eye, Thygeson’s and adenoviral infection) generally responds robustly and safely to corticosteroid.

Though inappropriate use of steroid on bacterial, protozoan or fungal keratitis may lead to poor visual outcomes, exacerbation of viral keratitis is probably the most frequently described negative corneal sequela of corticosteroid use in optometry. It is certainly true that treating herpes simplex virus (HSV) infections (clinically, this refers to the dendritic spectrum of disease, as well as the rare HSV-derived necrotizing stromal keratitis) with a steroid will worsen the infectious episode and increase superficial scarring.

The pathognomonic finding of a dendrite is a telltale sign that a steroid is inappropriate; however, it can be more challenging to differentiate dendritic lesions near the limbus



A rejection of a DSAEK graft manifesting as corneal edema and scattered keratic precipitates. This appearance also approximates that seen with viral endotheliitis; in both cases, topical steroids are indicated.

from hypersensitivity reactions, often leading to the somewhat tongue-in-cheek “steroid provocative test.”

For other forms of herpetic keratitis, such as stromal keratitis and endotheliitis, topical steroids are an important part of the therapy, though their use should generally be paired with an antiviral to reduce the risk of reactivation.

For any significant unilateral vascularization, especially with a nonulcerated stromal keratitis, you are probably dealing with an immune-mediated process, likely HSV immune stromal keratitis, and may safely pair a corticosteroid with oral or topical antivirals. The same treatment holds in cases of unilateral acute corneal edema without stromal infiltration or dramatically elevated IOP, which is generally HSV endotheliitis. A sight-threatening infection of the cornea resulting in this clinical constellation is rare.

Laterality is also helpful in distinguishing what keratitides are “steroid safe.” Though it is possible that bilateral corneal inflammation may be infectious in origin, it’s unlikely—approximately 97% of HSV keratitis is unilateral and, barring exceptional risk factors such as bilateral corneal surgery, nearly all cases of microbial keratitis are unilateral.²⁶ Although the same rules of avoidance hold—infilitrated ulcerations of the mid-periphery, paracentral or central cornea should avoid steroid—most other bilateral keratitides are safely treated with a steroid. In our experience, the most common sources of bilateral corneal inflammation are *Staphylococcal* hypersensitivities, rosacea keratitis, Thygeson’s, contact lens reactions and postviral epidemic keratoconjunctivitis, all of which respond well to corticosteroid or combination drops.

Because inappropriate steroid use on the cornea can have a devastating impact, follow up should be reduced

Corneal Transplants

This management protocol occupies a special place in the hierarchy of corticosteroid use, as immunologic and rejection concerns necessitate long-term topical corticosteroid use despite the associated risks. While rejection is the first leading cause of vision loss in a penetrating keratoplasty (PK) setting, glaucoma is the second, illustrating the delicate balance between treatment benefits and negative consequences.¹

Though not all of the blame falls to steroid use (some mechanical strain on the TM occurs during the surgical procedure itself), steroid-induced glaucoma is responsible for a large percentage of cases.¹ Likewise, microbial keratitis is up to 55 times more likely in patients with a PK compared with normal extended wear soft contact lens users.^{2,3} These eyes are also much more likely to have poor outcomes with medical management. The rate of re-graft as a result of infection is as high as 57%, and only 14% achieve 20/200 or better vision with medical management.^{2,4} Though infection in a PK population cannot solely be pinned on the use of corticosteroid, given the wide variety of compromises that occur to the ocular surface with PK, steroid use is certainly among the factors leading to a greater rate of infection and a worse prognosis.

Fortunately, with lamellar grafting, these risks diminish, either due to reduced necessity of steroid, as with deep anterior lamellar keratoplasty (DALK), or reduced disruption on immune privilege as with DSAEK and DMEK.

However, a certain patient population continues to need PK, and though risk may be reduced with lamellar surgeries relative to PK, these eyes still need steroid use for between one and two years depending on the transplant type. They also need observation to catch any complications of the graft or the treatment.

For average risk of transplants in steroid-responding PK patients, research shows loteprednol is less likely to result in IOP spiking and does not increase risk of rejection.⁵ Likewise, in lamellar surgery, loteprednol seems to effectively prevent rejection while reducing IOP issues.⁶ Fluorometholone 0.1%, while also effective at controlling IOP issues compared with prednisolone, was associated (somewhat predictably given its poor penetrance into the deep cornea) with a higher rate of possible rejection episodes.^{6,7}

1. Ayyala RS. Penetrating keratoplasty and glaucoma. *Surv Ophthalmol.* 2000;43(2):91-105.

2. Tseng SH, Ling KC. Late microbial keratitis after corneal transplantation. *Cornea.* 1995;14(6):591-6.

3. Stapelton F, Keay L, Edwards K, Holden B. The epidemiology of microbial keratitis with silicone hydrogel contact lenses. *Eye Contact Lens.* 2013;39(1):79-85.

4. Driebe WT, Stern GA. Microbial keratitis following corneal transplantation. *Cornea.* 1983;2:41-5.

5. Holland EJ, Djallilian AR, Sanderson JP. Attenuation of ocular hypertension with the use of topical loteprednol etabonate 0.5% in steroid responders after corneal transplantation. *Cornea.* 2009;28(10):1139-43.

6. Price MO, Feng MT, Scanameo A, Price FW Jr. Loteprednol etabonate 0.5% gel vs. prednisolone acetate 1% solution after Descemet membrane endothelial keratoplasty: prospective randomized trial. *Cornea.* 2015;34:853-8.

7. Price MO, Price FW Jr, Kruse FE, et al. Randomized comparison of topical prednisolone acetate 1% versus fluorometholone 0.1% in the first year after Descemet membrane endothelial keratoplasty. *Cornea.* 2014;33(9):880-6.

when adding a steroid to evaluate for a negative response. All patients also should be counseled to call the office if the condition worsens.

Without a doubt, corticosteroids have earned their place among the class of ophthalmic agents most frequently prescribed by optometrists. Their ability to aid in the management of almost all forms of ocular inflammation, even those inflammations derived from infectious processes, means their indications for use are without peer. This familiar-

ity, however, can breed complacency, which can lead to vision loss. For all ophthalmic steroid use, monitoring chronic use for adverse effects, particularly increased IOP, is critical. And when prescribing them, be sure to anticipate possible tissue-specific complications and adjust your follow-up schedule appropriately. ■

Dr. Bronner is an attending optometrist at Pacific Cataract and Laser Institute in Kennewick, WA.

Dr Whitley is the director of optometric services at Virginia Eye Consultants in Norfolk, VA

- Gonzalez A, Lakhani R, Bennett N, De Paz C. A twelve quarter quantitative analysis of ophthalmic drugs prescription writing by optometrists in the United States. *Clinical Optometry*. 2014;6:5-10.
- Jaanus SD, Cheetham JK, Leshner GA. Antiinflammatory drugs. In: Bartlett JD, Jaanus SD, eds. *Clinical Ocular Pharmacology*, 4th ed. Oxford: Butterworth-Heinemann; 2001:265-314.
- Greaves MW. Anti-inflammatory action of corticosteroids. *Post Graduate Medical Journal*. 1976;52:63.
- BenEzra D. Immunosuppression and immunomodulation. In: *Ocular Inflammation: Basic and Clinical Concepts*. BenEzra D, ed. London; Martin Dunitz; 1999:1-24.
- Tripathi RC, Parapuram SK, Tripathi BJ, et al. Corticosteroids and glaucoma risk. *Drugs Aging*. 1999;15(6):439-50.
- Jones R, Rhee DJ. Corticosteroid-induced ocular hypertension and glaucoma: a brief review and update of the literature. *Curr Opin Ophthalmol*. 2006;17(2):163-7.
- Kersey JP, Broadway DC. Corticosteroid-induced glaucoma: a review of the literature. *Eye*. 2005;20(4):407-16.
- Leibowitz HM, Bartlett JD, Rich R, et al. Intraocular pressure raising potential of 1.0% rimexolone in patients responding to corticosteroids. *Arch Ophthalmol*. 1996;114(8):933-7.
- Bartlett JD, Horwitz B, Laibowitz R, Howes JF. Intraocular pressure response to loteprednol etabonate in known steroid responders. *J Ocular Pharmacol*. 1993;9(2):157-65.
- Akingbehin AO. Comparative study of the intraocular pressure effects

- of fluorometholone 0.1% versus dexamethasone 0.1%. *Br J Ophthalmol*. 1988;67(10):661-3.
- Foster CS, Alter G, DeBarge LR, et al. Efficacy and safety of rimexolone 1% ophthalmic suspension vs 1% prednisolone acetate in the treatment of uveitis. *Am J Ophthalmol*. 1996;122(2):171-82.
- Morrison E, Archer DB. Effects of fluorometholone (FML) on the intraocular pressure of corticosteroid responders. *Br J Ophthalmol*. 1984;68(8):581-4.
- Sedrowski DP, et al. Anti-inflammatory drugs. In: Bartlett JD, Jaanus SO, eds. *Clinical Ocular Pharmacology*, 5th ed. St Louis: Butterworth-Heinemann; 2008.
- Cable MM. Intraocular pressure spikes using difluprednate 0.05% for post-operative cataract inflammation. *ARVO Annual Meeting Abstract*. 2010; 51(13):1981.
- Carnahan MC, Goldstein DA. Ocular complications of topical, periocular, and systemic corticosteroids. *Curr Op Ophthalmol*. 2000;11(6):478-83.
- Ilyas H, Slonim CB, Braswell GR, et al. Long-term safety of loteprednol etabonate 0.2% in the treatment of seasonal and perennial allergic conjunctivitis. *Eye Contact Lens*. 2004;30(1):10-13.
- Thorne JE, Woreta FA, Dunn JP, et al. Risk of cataract development among children with juvenile idiopathic arthritis-related uveitis treated with topical corticosteroids. *Ophthalmology*. 2010;117(7):1436-41.
- Sompayrac L. *How Pathogenic Viruses Think: making sense of virology*. Burlington: Jones and Bartlett Learning; 2002.

- Soukiasian SH, Baum J. Bacterial conjunctivitis. In: Krachmer JH, Mannis MJ, Holland EJ, eds. *Cornea*. 4th ed. St. Louis: Elsevier; 2017:479-92.
- Emmons W, Preston Church LW. Syphilitic uveitis. *West J Medicine*. 1994;161(2):168-71.
- Khambati FA, Shetty VP, Ghate GD, et al. The effect of corticosteroid usage on the bacterial killing, clearance and nerve damage in leprosy: Part 3—Study of two comparable groups of 100 multibacillary patients each, treated with MDT + steroids vs MDT alone, assessed at 6 months post-release from 12 months MDT. *Lepr Rev*. 2010;81(1):41-58.
- Foster C, Davanzo R, Flynn T, et al. Durezol (Difluprednate ophthalmic emulsion 0.05%) compared with Pred Forte 1% ophthalmic suspension in the treatment of endogenous anterior uveitis. *J Ocul Pharmacol Ther*. 2010;26(5):475-83.
- Srivivasin M, Mascarenhas J, Rajaraman R, et al. Corticosteroids for bacterial keratitis: the Steroids for Corneal Ulcers Trial (SCUT). *Arch Ophthalmol*. 2012;130(2):143-50.
- Miedziak A, Miller MR, Rapuano CJ, et al. Risk factors in microbial keratitis leading to penetrating keratoplasty. *Ophthalmology*. 1999;106(6):1166-70.
- Contantinou M, Jhanji V, Tao LW, Vajpayee RB. Clinical review of corneal ulcers resulting in eversion and enucleation in elderly population. *Graefes Arch Clin Exp Ophthalmol*. 2009;247(10):1389-93.
- Wilhelmus KR, Falcon MG, Jones BR. Bilateral herpetic keratitis. *Br J Ophthalmol*. 1981;65:385-7.

OSC QUIZ

You can obtain transcript-quality continuing education credit through the Optometric Study Center. Complete the test form and return it with the \$35 fee to: Jobson Medical Information, Dept.: Optometric CE, 440 9th Avenue, 14th Floor, New York, NY 10001. To be eligible, please return the card within a year of publication.

You can also access the test form and submit your answers and payment via credit card at *Review of Optometry* online, www.reviewofoptometry.com/ce.

You must achieve a score of 70 or higher to receive credit. Allow four weeks for processing. For each Optometric Study Center course you pass, you earn 2 hours of transcript-quality credit from Pennsylvania College of Optometry and double credit toward the AOA Optometric Recognition Award—Category 1.

Please check with your state licensing board to see if this approval counts toward your CE requirement for relicensure.

1. What class of topical medications are the most frequently prescribed by optometrists?
a. Antibiotics.
b. Antivirals.
c. Antiallergy.
d. Corticosteroids.

2. Steroids work by inhibiting which pathway?
a. Phospholipase A2.
b. Cyclooxygenase.
c. Lipoxigenase.
d. Histamine.

3. Side effects of oral prednisone include all of the following, except:
a. Increased IOP.
b. Cataract.
c. Mood changes.

d. Reduction of blood sugar levels.

4. Steroids have the broadest and _____ specific effect on inflammation of any immune modulatory agent.

- Most.
- Least.
- No.
- Somewhat.

5. Steroids reduce inflammation by:

- Increasing vascular permeability.
- Reducing the recruitment of immune cells.
- Increasing tissue breakdown.
- Activating fibroblast.

6. With increased IOP, up to what percentage of patients are steroid responders?

- 6%.
- 16%.
- 36%.
- 46%.

7. Which patient type/condition is most likely to have a steroid response?

- Cataract.
- Glaucoma.
- Diabetes.
- Allergy.

8. "Soft steroids" achieve increased safety due to the following mechanisms, except:

- Decreased penetration.
- Reduced half-life.
- Decreased concentration.
- Increased half-life.

9. The most common cataracts caused by steroid usage typically are:

- Posterior subcapsular.
- Anterior polar.
- Nuclear cataract.

d. Cortical cataract.

10. According to one study, which steroid exhibits the highest corneal penetration?

- Fluorometholone alcohol suspension.
- Rimexolone suspension.
- Prednisolone acetate suspension.
- Prednisolone phosphate solution.

11. All of these anatomic zones are commonly targeted by optometrists when prescribing topical steroids, except:

- Lids.
- Cornea.
- Anterior chamber.
- Retina.

12. Viruses are more likely to invade the conjunctiva than the lid due to:

- Lack of keratinized tissue.
- Increase in keratinized tissue.
- Increased surface area.
- Lack of living cells.

13. Topical steroids are beneficial in the treatment of viral conjunctivitis due to:

- Increasing inflammation.
- Reducing inflammation.
- Increasing tissue formation after damage.
- Decreasing goblet cell destruction.

14. Steroid drops should be used how often in initial treatment of uveitis?

- QD.
- BID to TID.
- Q1H to QID.
- They are not indicated for uveitis treatment.

15. The SCUT study conclusions show:

- There is no difference in visual acuity outcomes when adding corticosteroids for corneal ulcer treatment when their use

OSC QUIZ

follows a period of antibiotic only.
 b. There is no benefit but substantial harm to adding corticosteroids for corneal ulcer treatment following a period of antibiotic only.
 c. There is no benefit or harm to adding corticosteroids for corneal ulcer treatment prior to initiating antibiotic therapy.
 d. Steroids are contraindicated for use in corneal ulcers.

16. Peripheral corneal infiltrates are most likely due to _____ reactions.

- a. Hypersensitivity.
- b. Allergic.
- c. Infectious.
- d. Viral.

17. Clinical findings for herpes simplex immune stromal keratitis include all of the following except:

- a. Dendrite.
- b. Stromal edema.
- c. Keratic precipitates.
- d. High IOP.

18. What is the most common cause of vision loss after penetrating keratoplasty?

- a. Graft rejection.
- b. Graft failure.
- c. Glaucoma.
- d. Uveitis.

19. Microbial keratitis may be more likely by up to ___ times in patients with a PK compared with normal extended wear soft contact lens users.

- a. 25.
- b. 35.
- c. 45.
- d. 55.

20. All of the following are forms of lamellar grafting except:

- a. Deep anterior lamellar keratoplasty.
- b. Descemet's membrane endothelial keratoplasty.
- c. Descemet's stripping endothelial keratoplasty.
- d. Penetrating keratoplasty.



TAKE THE TEST ONLINE TODAY!
www.reviewofoptometry.com/continuing_education/

Examination Answer Sheet

Protocols and Pitfalls in Topical Steroid Use

Valid for credit through March 2, 2021

Online: This exam can be taken online at www.reviewofoptometry.com/ce. Upon passing the exam, you can view your results immediately and download a real-time CE certificate. You can also view your test history at any time from the website.

Directions: Select one answer for each question in the exam and completely darken the appropriate circle. A minimum score of 70% is required to earn credit.

Mail to: Jobson Medical Information, Dept.: Optometric CE, 440 9th Avenue, 14th Floor, New York, NY 10001.

Payment: Remit \$35 with this exam. Make check payable to Jobson Medical Information LLC.

Credit: This course is COPE approved for 2 hours of CE credit. Course ID is **57000-PH**.

Sponsorship: This course is joint-sponsored by the Pennsylvania College of Optometry.

Processing: There is a four-week processing time for this exam.

Answers to CE exam:

1. (A) (B) (C) (D)
2. (A) (B) (C) (D)
3. (A) (B) (C) (D)
4. (A) (B) (C) (D)
5. (A) (B) (C) (D)
6. (A) (B) (C) (D)
7. (A) (B) (C) (D)
8. (A) (B) (C) (D)
9. (A) (B) (C) (D)
10. (A) (B) (C) (D)
11. (A) (B) (C) (D)
12. (A) (B) (C) (D)
13. (A) (B) (C) (D)
14. (A) (B) (C) (D)
15. (A) (B) (C) (D)
16. (A) (B) (C) (D)
17. (A) (B) (C) (D)
18. (A) (B) (C) (D)
19. (A) (B) (C) (D)
20. (A) (B) (C) (D)

Post-activity evaluation questions:

Rate how well the activity supported your achievement of these learning objectives:
 1=Poor, 2=Fair, 3=Neutral, 4=Good, 5=Excellent

21. Improve my understanding of the known side effects of topical steroids. (1) (2) (3) (4) (5)

22. Become familiar with the appropriate protocols for topical steroid use in optometric practice. (1) (2) (3) (4) (5)

23. Increase my understanding of the dosing-based differences among target tissues. (1) (2) (3) (4) (5)

24. Better understand the effects of topical steroids on the conjunctiva. (1) (2) (3) (4) (5)

25. Increase my knowledge of steroid use for corneal pathology. (1) (2) (3) (4) (5)

26. Improve my ability to properly prescribe topical steroids for ocular conditions. (1) (2) (3) (4) (5)

Rate the quality of the material provided:
 1=Strongly disagree, 2=Somewhat disagree, 3=Neutral, 4=Somewhat agree, 5=Strongly agree

27. The content was evidence-based. (1) (2) (3) (4) (5)

28. The content was balanced and free of bias. (1) (2) (3) (4) (5)

29. The presentation was clear and effective. (1) (2) (3) (4) (5)

30. Additional comments on this course:

Please retain a copy for your records. Please print clearly.

First Name

Last Name

E-Mail

The following is your: Home Address Business Address

Business Name

Address

City State

ZIP

Telephone # - -

Fax # - -

By submitting this answer sheet, I certify that I have read the lesson in its entirety and completed the self-assessment exam personally based on the material presented. I have not obtained the answers to this exam by any fraudulent or improper means.

Signature _____ Date _____

Lesson 116173

RO-OSC-0418

Proceed With Caution: Low Vision and Driving

Here's how you can navigate the complex interplay between DMV standards and the needs of your patients who are visually impaired.

By Mark E. Wilkinson, OD, and Khadija S. Shahid, OD, MPH

Driving with both visual acuity (VA) and visual field (VF) loss has been a hot topic in the field for decades.¹⁻¹⁰

Although the literature routinely acknowledges that driving is a privilege, not a right, loss of driving privileges can have devastating consequences such as increased social isolation, decreased quality of life and depression.¹¹⁻¹³ Such high stakes can make the subject of driving tough to bring up during the examination of individuals with visual impairments. However, ODs have a duty to properly assess and counsel patients with congenital or acquired visual impairments who would like to acquire driving privileges or who will become non-drivers because of their vision loss.

Here, we discuss the complexities of the current vision and licensure standards, how they affect patients with vision loss and what ODs can do to properly evaluate

and counsel patients who are visually impaired and want to drive.

State Standards

One 1991 study found uniform standards did not exist in the United States for VA, VF or the use of bioptic telescopes—which is still true today.¹⁴ Currently, two vision standards exist for driving licensure.

Some states enforce a rejection standard: an individual will automatically be rejected for licensure if they do not meet the minimum vision standards for VF or VA. Most commonly, those standards are VA in one or both eyes of 20/40 or better and a binocular field of view of 140 degrees or more. However, significant variances occur; for example,

Wisconsin only requires a 40-degree field of view, and a number of states have no VF specification.

The alternative to the rejection standard is the vision screening standard. Rather than being automatically rejected if they do not meet the minimum standards, individuals may be granted driving privileges after further evaluation of all factors, including a behind-the-wheel test. Iowa, for example, allows for individual review, via a behind-the-wheel test, for individuals with VAs better than 20/200, a VF greater than 20 degrees or both.

The Aging Driver

Today, more than five million Americans age 65 and older are afflicted with a form of dementia, such as Alzheimer's disease. By 2050, this number is expected to grow to 13.8 million as the baby-boom population ages.¹ Data indicates that 50% of persons with Alzheimer's disease continue to drive up to three years after they have been diagnosed with the disease, and that these individuals also have worse driving performance and are more likely to cause traffic accidents.¹⁻⁴ Clinicians must be prepared to care for these patients and properly counsel them—and their loved ones—on safe driving.

1. National Center for Chronic Disease Prevention and Health Promotion. 2016 Alzheimer's disease facts and figures. *Alzheimers Dement*. 2016;12(4):459-509.
2. Brown LB, Ott BR. Driving and dementia: A review of the literature. *Journal of Geriatric Psychiatry and Neurology*. 2004;17(4):232-40.
3. Stout SH, Babulal GM, Ma C, et al. Driving cessation over a 24-year period: Dementia severity and cerebrospinal fluid biomarkers. *Alzheimers Dement*. 2018 Jan 9;5260(17):33854-2. [Epub ahead of print]
4. American Medical Association. Physician's guide to assessing and counseling older drivers, 2nd ed. www.nhtsa.gov/staticfiles/nti/older_drivers/pdf/811298.pdf. Assessed January 31, 2018.

S4OPTIK SLIT LAMPS

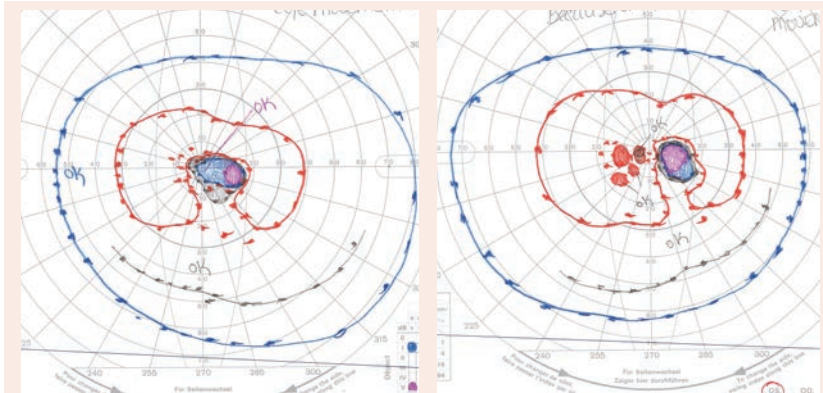
NEW LED Illumination

More than 50,000
hours of clear, cool
illumination.



Easier observation of
minute details.

Color temperature
maintained through the full
range of illumination
adjustment.



The relative central scotomas in this patient's eyes, caused by Stargardt disease, did not prevent her from driving safely.

Case 1

A 38-year-old female presented with a history of reduced vision for the past 20 years secondary to Stargardt disease. Her best-corrected visual acuity (BCVA) was 20/160-2 OD, 20/160-1 OS and 20/125-2 OU. She had small bilateral central scotomas consistent with her central acuity. A discretionary review request was made to the Iowa DOT, and she received unrestricted driving privileges following several behind-the-wheel tests that took place during the day and at night. She has maintained full driving privileges, without incident, for the past 17 years.

In addition to vision standards, two different licensure standards exist for driving, depending on the state. According to some states, as long as the individual's VA and VFs are adequate enough to allow them licensure, they can continue to drive until that license expires, regardless of how poor their acuity or VFs become during the licensing cycle. Drivers in those states may have a false sense of security, despite changes in their vision, when they have a license that does not expire for several years.

In other states, individuals whose VA or VFs drop below the state's licensure standards are no longer legal to drive from that time forward, regardless of the licensing cycle. This is the same standard used for commercial licensure, where the driver needs to know they meet the vision standard every time they get behind the wheel of a commercial vehicle. Currently, only a few states, such as Illinois and Pennsylvania,

use this standard for driving.⁵

Above and beyond these vision and licensure standards, states have different protocols for restricted driving privileges, including: daylight-only, no driving when headlights are required, reduced speed, local area driving or a restricted distance from home and no highway driving. States also vary on whether the use of a bioptic telescope is allowed for licensure, as well as what VA requirements must be met, both with the bioptic telescope and the carrier lens.

All of these variations mean an individual could be licensed in some states and not even considered for driving in others.

Clinicians should be familiar with their state's vision standards for driving to properly educate their patients who are visually impaired. Unfortunately, it can be difficult to know for sure what any given state's driving laws entail, and you must check each DMV/DOT website or call to clarify.

S4OPTIK

250 Cooper Ave., Suite 100 Tonawanda NY 14150


www.s4optik.com | 888-224-6012

Sensible equipment. Well made, well priced.

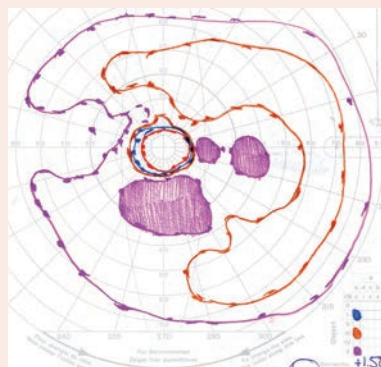
For today's modern office.

Case 2

A 55-year-old male presented for an evaluation stating that he was diagnosed with retinitis pigmentosa three months prior. He noted that he has been “losing things” when he puts them down for the past 15 to 20 years. He stated that based on recent threshold-related central VF testing, he was told to stop driving, get a cane or a guide dog and learn Braille. His BCVA was 20/25 OD/OS. He stated he has driven cautiously for many years without incident. Furthermore, he lives in a state that has no VF requirements. When non-threshold related, full-field testing was performed, we found he had relatively full fields to the larger isopters tested (III4e and V4e), with scattered paracentral scotomas. Based on his full-field testing and VA, he was advised that he did not need to stop driving, nor did he need a guide dog or Braille literacy.



Based on 24-2 threshold related testing, the examiner felt the patient's visual field was severely constricted.



Full-field testing shows a restricted field under lower light conditions and a significantly fuller field under full light conditions.

Roadblocks

Given today's driving environment, the vision screening standards used by state departments of motor vehicles/departments of transportation (DMV/DOT) may not be satisfactory in assessing drivers' functional vision (*Cases 1 and 2*).^{1-10,15}

Although VA has been widely used in driving regulations for decades, it is a poor predictor of performance for several reasons:^{8,9}

- The correlation of VA alone to accidents is less than 1%.¹⁰
- The minimum standard of 20/40 is based on an American Medical Association recommendation dating back to 1937.¹⁶ Research shows individuals with *normal sight* have a functional VA of less than 20/40 when driving at night at speeds greater than 55mph with high beams on and at speeds greater than

35mph with low beams on.^{17,18}

- The effective lateral field of view when driving with headlights is only 35 to 45 degrees.¹⁹
- A driver's license has no restrictions concerning driving during periods of dense fog, heavy rain or snow—times when even a driver with normal VA will have their vision reduced to this presumed unacceptable level.

Vision Testing for Driving

High-contrast VA testing under photopic conditions continues to be the standard for licensure. However, additional visual function tests not currently used in the United States for driving licensure may be helpful when evaluating functional abilities behind the wheel:⁸⁻¹⁰

Full-field, non-threshold visual field testing. Testing that includes at least the I4e and a V4e isopter is

valuable information, even in states that do not specify VF requirements. Alternately, the SSA Kinetic testing strategy on the Humphrey field analyzer (Zeiss) could be used with the standard testing protocol as well as a V4e equivalent isopter.

Contrast sensitivity. This is an important test for assessing an individual's fitness to drive because research shows it is predictive of driving outcomes for individuals older than 65 with normal vision.⁸

A common cause of contrast sensitivity loss is cataracts, and drivers with cataracts are 2.5 times more likely to have an at-fault accident than those without cataracts.^{8,20-24} Additionally, individuals with cataracts are four times more likely to report difficulties with driving compared with individuals without cataracts.^{8,20-23} Some individuals with binocular cataracts continue to experience driving difficulties, even after monocular cataract surgery.²³ Research shows improved contrast sensitivity after cataract surgery is more valuable than improved visual acuity when assessing driving difficulties due to vision.¹⁰ Finally, one study found that contrast sensitivity of less than 1.25 log units was the only independent predictor of crash involvement for individuals with cataracts in the previous five years.²³

Useful field of view (UFOV).

Unlike conventional visual field measures, UFOV assesses higher-order visual processing skills such as selective and divided attention and visual processing speed under increasingly complex visual displays. Thus, it more closely approximates the complexity of driving as a visual task.

As we age, our ability to process visual information slows. While not a linear progression, this slowing makes driving in complex environments more difficult. UFOV testing can be valuable in determining

which at-risk drivers with normal or near-normal visual acuity are no longer able to process visual information in a timely manner to allow for safe driving (Case 3).

However, research shows visual processing training over several hours using UFOV testing with preset criteria for success can improve not only UFOV test performance, but also the driving performance of persons older than 55. Preset criteria of 10 training sessions over five weeks resulted in an approximately 50% lower rate of at-fault motor vehicle crashes (MVCs) during the subsequent six years compared with control group.²⁵⁻²⁸

Clinical Steps

The American Medical Association's (AMA) Physician's Guide to Assessing and Counseling of Older Drivers recommends that clinicians assess all risk factors when evaluating drivers older than 65, including vision, cognition and motor skills.²⁴ For example, a clock drawing test is an easy test of cognition, and UFOV is an excellent tool to use to assess cognition as it relates to fitness to drive.²⁹ If concerns exist in any of these areas, it recommends a referral to the state DMV/DOT for a formal driving assessment.

When examining patients of driving age, clinicians should ask the following questions, regardless of the patient's current level of visual functioning. Your patient's answers may surprise you:

- Do you drive an automobile? If so, are you driving at night or only during the day? Do you drive only close to home, or are you driving both in town and on the highway? (For example, they may be driving at night,

Adapted and Semi-Autonomous Cars

In 2016, a total of 37,461 deaths and two million injuries were from automobile accidents, a 5.6% increase from 2015.¹ With these staggering numbers, it's no wonder so much attention has been focused on semi-autonomous safety systems and their potential to reduce accident rates. But this technology could also have a significant impact on our low vision patients. It may one day allow individuals with visual acuity and visual field loss the ability to continue driving, just as those with physical handicaps, including loss of limbs, currently have the ability to operate an adapted motor vehicle and be licensed to drive.

1. National Highway Traffic Safety Administration. USDOT releases 2016 fatal traffic crash data. October 6, 2017. www.nhtsa.gov/press-releases/usdot-releases-2016-fatal-traffic-crash-data. Accessed January 31, 2018.

when they are only visually qualified to drive during the day. If you don't ask, you won't know to tell the patient they are not visually qualified to drive at night according to state law.)

- Do vision problems cause you to be fearful when driving?
- During the past six months, have you made any driving errors? (e.g., an at-fault motor vehicle accident related to the patient not seeing someone or not judging distance correctly.)
- Is your mobility affected by your vision? (If your patient is struggling to find their way to the exam chair or has difficulty getting through the doorway, it is hard to imagine that they can safely operate a motor vehicle.)

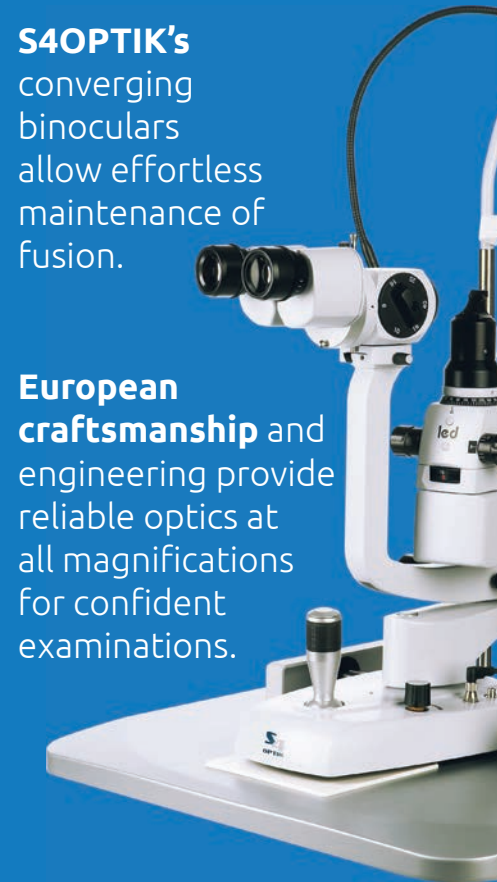Patients come to us because of the quality of care we provide, which includes giving honest information about their vision and ocular health. As optometry's scope of practice continues to expand, we share the burden of not just the accurate and timely diagnosis of ocular disease, but also the effect that disease may have on visual function. If your patient develops visual or cognitive changes that could affect their ability

S4OPTIK SLIT LAMPS

SEE MORE - Exceptional Optics

S4OPTIK's converging binoculars allow effortless maintenance of fusion.

European craftsmanship and engineering provide reliable optics at all magnifications for confident examinations.



Vertical and compact configurations available.

S4OPTIK

250 Cooper Ave., Suite 100 Tonawanda NY 14150

www.s4optik.com | 888-224-6012

Sensible equipment. Well made, well priced.

For today's modern office.

to safely operate a motor vehicle, it is your professional responsibility, and legal duty, to share that information with your patient.

Assistive Technology

Currently, in 43 states, the acquisition of a bioptic telescope—a hands-free, spectacle mounted device—is the only way an individual with visual acuity less than 20/70 can attempt to qualify for driving privileges.³⁰ However, research has yet to provide definitive data on the risks and benefits associated with this assistive technology, and the topic is surrounded by controversy. One report of 300 bioptic drivers found the biggest challenge with reduced vision (binocular acuity less than or equal to 20/200) was reading street signs—they had no problems seeing other traffic, people or animals when driving.³¹ In the past, practitioners felt that when a bioptic telescope is fit on one eye and appropriate training is performed, the user can maintain peripheral awareness with their

fellow eye when viewing through the telescope for wayfinding such as reading street signs.

While bioptic telescopes are only used for a small percentage of driving time (1% to 10%) for wayfinding tasks such as spotting street signs, they reduce the user's visual field and can contribute to inattention blindness. As with cell phone use while driving, when using a bioptic telescope, the driver must attend to two tasks at once, which is difficult because of the time lag associated with switching from one activity to another. One study found as drivers switch repeatedly between tasks such as using the radio or information system, the time cost adds up, increasing inattention blindness.³² Some believe the distraction created by a bioptic telescope outweighs the visual benefits, but more research is needed to clarify whether driving with a bioptic telescope makes individuals who are visually impaired safer drivers than those who do not use a device.³⁰

Today's audible GPS devices provide these patients a readily available and significantly cheaper option compared with a bioptic telescope. A GPS device can allow the driver to focus more attention on the road and the traffic around them and less time attempting to read street signs.

Based on our clinical experience evaluating hundreds of patients with vision loss in the 20/71 to 20/199 range, many continue to drive safely for decades in Iowa, where bioptic telescopes are not permitted to gain licensure. Today, all of our patients with impaired vision use a GPS system in lieu of their bioptic telescope.

Of course, if a person feels a bioptic helps them drive more safely, they should be allowed to use it. Clinicians should carefully discuss the pros and cons with patients who are visually impaired, and counsel them appropriately on their options when it comes to assistive technologies behind the wheel.

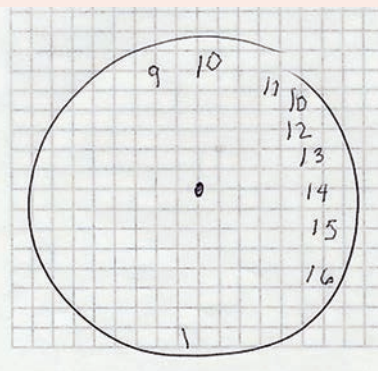
In general, a person's fitness to drive cannot be determined by their age, VA or VF alone. The functional manifestations of various ocular conditions and an individual's ability to compensate for any visual impairment varies widely. We must use our knowledge and tools to assess competency to drive or refer to a driver rehabilitation specialist for additional assessment.

We are responsible for helping our patients understand when their vision falls below the state's standards and how that will affect their driving privileges. At the same time, we need to serve as advocates for those with reduced VA or reduced VFs who have the compensatory skills to continue driving safely, despite those reductions. Finally, we need to advocate for standardized VA and VF requirements on a national level, so that individuals

Case 3

A 56-year-old male presented with a chief complaint of increasing difficulties over the past three months with both clarity and tracking when reading. He noted that he was losing his place frequently as he read from line to line and column to column. In addition, his wife said she refused to ride with him because his driving was "scary." His BCVA was 20/20 OD/OS, and his ocular health evaluation and VFs were unremarkable. He was referred to a neuro-ophthalmologist for a positron emission tomography scan, which revealed the left occipital and parietal occipital lobes had more atrophy than the right, out of proportion to the patient's age. He was diagnosed with the visual variant of Alzheimer's disease (VAD), and his wife questioned whether he was safe to continue driving. UFOV testing found he had nine times slower visual processing speed, five times slower divided visual attention skills and severely delayed selected visual attention skills—thus, he was at a high risk for an automobile accident.

Based on these findings, he was advised to retire from all driving immediately.



The clock drawing test, as seen here, has an 86% sensitivity and a 96% specificity for assessing dementia.²⁹

who are visually impaired have the same ability to demonstrate they can safely operate a motor vehicle, regardless of their home state. ■

Dr. Wilkinson is a clinical professor in the Department of Ophthalmology and Visual Sciences at the University of Iowa's Carver College of Medicine. He is the director of the institution's Vision Rehabilitation Service and a faculty member of the University of Iowa Institute for Vision Research and the National Advanced Driving Simulator.

Dr. Shahid is a clinical assistant professor in the Department of Ophthalmology and Visual Sciences at the University of Iowa's Carver College of Medicine, where she provides vision rehabilitation and primary eye care.

1. Wilkinson ME. Driving with a visual impairment. *INSIGHT*. 1998;23(2):48-52.
2. Chapter 8: Sustaining safe mobility in older drivers. In: Iowa Safety Management System, Iowa State University; Center for Transportation Research and Education. *Toolbox of Highway Safety Strategies: Drivers*.
3. Wilkinson. ME. Should your low vision patient be driving? *EyeNet*. 1998;2(9):21.
4. Wilkinson ME. When is it appropriate to stop driving due to vision impairment? *Aging and Vision*. 2003;15(2).
5. Brinig MF, Wilkinson ME, Daly J, et al. Standards for licensing and driving. *Optometry*. 2007;78:439-45.
6. Wilkinson ME. Driving with a visual impairment: new guidelines are needed. *Optometry*. 2003;74(1):7-10.
7. Johnson CA, Wilkinson ME. Vision and driving: The United States. *Neuro-ophthalmol*. 2010;30:170-6.
8. Owsley C, McGwin G Jr. Vision impairment and driving. *Surv Ophthalmol*. 1999;43(6):535-50.
9. Owsley C, McGwin G Jr. Vision and driving. *Vision Res*. 2010;50(23):2348-61.
10. Burg A. Vision and driving: A report on research. *Human Factors*. 1971;13(1):79-87.
11. Renaud J, Bédard E. Depression in the elderly with visual impairment and its association with quality of life. *Clinical Interventions in Aging*. 2013;8:931-943.
12. Ragland DR, Satariano WA, MacLeod KE. Driving cessation and increased depressive symptoms. *J Gerontol A Biol Sci Med Sci*. 2005;60(3):399-403.
13. Chihuri S, Milelitz TJ, DiMaggio CJ, et al. Driving cessation and health outcomes in older adults. *Am Geriatr Soc*. 2016;64(2):332-41.
14. Barron C. Biopic telescopic spectacles for motor vehicle driving. *JAQA*. 1991;61:37-41.
15. Shipp MD, Panchansky R. Vision testing and the elderly driver: is there a problem meriting policy change? *J Am Optom Assoc*. 1995;66(6):343-51.
16. Black NM, Gradle HS, Snell AC. Visual standards for licensure to operate motor vehicles, preliminary report of the special committee at Atlantic City Session JAMA. 1937;109(26):61B-4.
17. Owens DA, Sivak, M. The role of reduced visibility in nighttime road fatalities (Report #UMTRI-93-33), Ann Arbor: The University of Michigan Transportation Research Institute. 1993.
18. Sturr JF, Kline GE, Taub AJ. Performance of young and old drivers on a static acuity test under photopic and mesopic illumination conditions. *Human Factors*. 1990;32:1-8.
19. Owens DA, Francis EL, Leibowitz HW. Visibility distance with headlights: A functional approach, Society Automotive Engineering Technical Papers Series #890684. 1989.

Driving Legalities

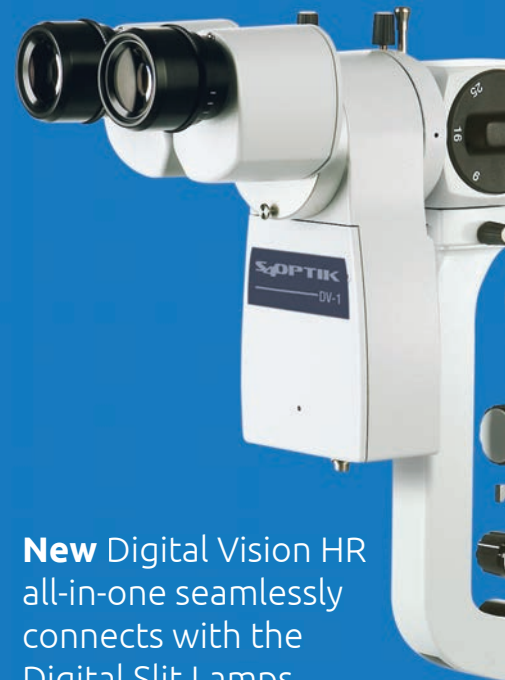As clinicians, we have the duty to warn, which is a legal rationale designed to provide a means of protecting the patient from an unreasonable risk of harm.¹ Duty to warn states that failure to warn a patient of conditions that create a risk of injury will be upheld as a cause of action against eye care providers when it can be shown that the failure to warn is the proximate cause of an injury. All of this jargon means that if an individual with a visual impairment has a motor vehicle accident related to their reduced vision, they can hold their eye care provider responsible for the accident. In this case, the patient can argue that they had insufficient warning of their impairment, and because of their impairment, their operation of a motor vehicle or other machinery resulted in an injury. Thus, you should warn patients whose vision no longer legally qualifies them to operate a motor vehicle to abstain from driving and note this in the patient's record.

1. Classe JG. Clinicolegal aspects of practice. *Southern Journal of Optometry*. January 1986;IV, I.

20. Owsley C, McGwin G Jr, Sloane M, et al. Impact of cataract surgery on motor vehicle crash involvement by older adults. *J Am Med Assoc*. 2002;288(7):841-9.
21. Owsley C, Stalvey BT, Wells J, et al. Visual risk factors for crash involvement in older drivers with cataract. *Arch Ophthalmol*. 2001;119(6):881-7.
22. Owsley C, Stalvey B, Wells J, Sloane ME. Older drivers and cataract: Driving habits and crash risk. *J Gerontol A Biol Sci Med Sci*. 1999;54(4):M203-11.
23. Fraser ML, Meuleners JB, Lee AH, et al. Which visual measures affect change in driving difficulty after first eye cataract surgery? *Accident Analysis & Prevention*. 2013 April;58:10-14.
24. American Medical Association. Physician's guide to assessing and counseling older drivers, 2nd ed. www.nhtsa.gov/staticfiles/nht/older_drivers/pdf/811298.pdf. Accessed January 31, 2018.
25. Edwards JD, Fauston BA, Tellow AM, et al. Systematic review and meta-analyses of useful field of view cognitive training. *Neuroscience and Biobehavioral Reviews*. 2018;84:72-91.
26. O'Connor ML, Hudak EM, Edwards JD. Cognitive speed of processing training can promote community mobility among older adults: A brief review. *J Aging Res*. 2011;2011:430802.
27. Roenker DL, Cissell GM, Ball KK, et al. Speed-of-processing and driving simulator training result in improved driving performance. *Hum Factors*. 2003;45(2):218-33.
28. Ball KK, Edwards JD, Ross LA, McGwin G, Jr. Cognitive training decreases motor vehicle collision involvement in older drivers. *J Am Geriatr Soc*. 2010;58(11):2107-13.
29. Brodaty H, Moore CM. The clock drawing test for dementia of the Alzheimer's type: A comparison of three scoring methods in a memory disorders clinic. *Int J Geriatr Psychiatry*. 1997 Jun;12(6):619-27.
30. Owsley C. Driving with biopic telescopes: Organizing a research agenda. *Opt and Vis Sciences*. 2012;89(9):1249-56.
31. Feinbloom W. Driving with biopic telescopic spectacles (BTS). *Am J Optom Physiol Opt*. 1977;Jan;54(1):35-42.
32. Strayer DL, Drews FA, Johnston WA. Cell phone-induced failures of visual attention during simulated driving. *J Exp Psychol: Applied*. 2003;9(1):23-32.

S4OPTIK SLIT LAMPS

EFFORTLESS Digital Imaging



New Digital Vision HR all-in-one seamlessly connects with the Digital Slit Lamps to provide brilliant imaging at the press of a button.

Still Images or Video Sequences



S4OPTIK

250 Cooper Ave., Suite 100 Tonawanda NY 14150

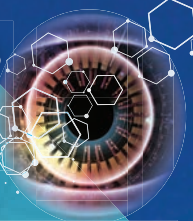www.s4optik.com | 888-224-6012

Sensible equipment. Well made, well priced.

For today's modern office.

Earn up to
18 CE
Credits*

NEW TECHNOLOGIES
& TREATMENTS IN
2018 EYE CARE



REVIEW OF OPTOMETRY®
EDUCATIONAL MEETINGS OF CLINICAL EXCELLENCE

Join us in

Orlando, Florida

May 17-20, 2018

Join Review of Optometry's New Technologies & Treatments in Eye Care May 17-20, 2018, in Orlando at Disney's Yacht & Beach Club. This meeting provides up to 18* COPE CE credits including interactive workshops!**

TQ/CEE is approved for optometrists licensed in Florida or other states requiring "Transcript Quality" courses for re-licensure. Please see agenda on event website for specific courses.

Registration cost: \$595



FACULTY



Paul Karpecki, OD, FAAO
Program Chair



Douglas Devries, OD



Mark Dunbar, OD, FAAO



Murray Fingeret, OD, FAAO

DISNEY'S YACHT & BEACH CLUB

1700 Epcot Resorts Boulevard
Orlando, Florida 32830
Phone: 407-934-7000

See website for updated hotel accommodations.



3 WAYS TO REGISTER

online: www.reviewofoptometry.com/OrlandoNTT2017

email: reviewmeetings@jobson.com | **phone:** 866-658-1772

**Separate registration required. Review of Optometry® partners with Salus University for those ODs who are licensed in states that require university credit. See event website for complete details.

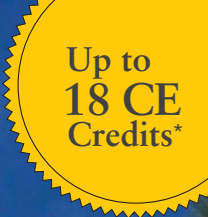
Photos Courtesy of Disney Group Marketing

Administered by
Review of Optometry®

cope
*Approval pending

SALUS
UNIVERSITY
Pennsylvania College of Optometry

Partially supported by
unrestricted educational grants from
Alcon



May 17-20, 2018

Disney's Yacht & Beach Club

1700 Epcot Resorts Boulevard, Orlando, Florida 32830

See event website for hotel accommodations.

Registration Information

Name	Title	NPI # (NPI numbers will only be used for HCP reporting purposes)	
Practice Affiliation	License #/State	OE Tracker Number	
Work Mailing Address	City	State	Zip Code
Work Telephone	Cell	E-mail	Fax

Name Badge Information (please print clearly)

My Name	My Guest	Additional Guests
---------	----------	-------------------

Payment Information

	Rate per person	No. in party	Subtotal
OD Registration: \$595 (includes up to 18 hours of CE, breakfast, reception) Call 866-685-1772 for daily and student rates.	\$595	x <u>1</u>	= \$ _____
Additional Guest(s): \$45 (12 years and older, reception only)	\$45	x _____	= \$ _____

Complimentary Workshops (Separate registration required)

- | | |
|---|---|
| <input type="checkbox"/> Blepharitis/MGD Workshop (1:00pm-3:00pm)
Speaker: Douglas Devries, OD | <input type="checkbox"/> Dry Eye Disease Workshop (3:00pm-5:00pm)
Speaker: Douglas Devries, OD |
| <input type="checkbox"/> Retinal Disease Workshop (1:00pm-3:00pm)
Speaker: Mark Dunbar, OD | <input type="checkbox"/> Glaucoma Workshop (3:00pm-5:00pm)
Speaker: Murray Fingeret, OD |

Check enclosed (make checks payable to *Review of Optometry*)

Charge my: American Express Mastercard Visa

Credit Card Number	Exp Date
Cardholder (print name)	
Signature	

CONFERENCE CANCELLATION POLICY

Full refund on registration fee until March 20, 2018

50% refund on registration fee until April 17, 2018

No refund past April 17, 2018

Mail Form: Review Group Meetings c/o Jobson
11 Campus Blvd, Ste. 100
Newtown Square, PA 19073

For more information or to register, contact Lois DiDomenico at 866-658-1772 or at ReviewMeetings@Jobson.com.

Fax Form: Review Meetings Group
610-492-1039

YOUR INDUSTRY

YOUR CAMPAIGN

OWN IT.



Think About Your Eyes (TAYE) not only promotes vision health among Americans, it also supports the health of the vision industry. In 2018, TAYE messaging will reach 95% of Americans aged 25-49 with its new campaign encouraging consumers to schedule an annual eye exam.

**An investment in TAYE is an investment in industry success.
Join the effort now.**

Contact Ron Sallerson at 703-740-1093 or rsallerson@thinkaboutyoureyes.com to join our 21 industry partners and 43 state optometric associations in supporting TAYE.

**thinkabout
youreyes.com**

Brought to you by the AOA
 AMERICAN OPTOMETRIC ASSOCIATION



Trouble with Thygeson's

Management for these cases can be quick if done right. However, an exact cause for the disease is still elusive. **Edited by Joseph P. Shovlin, OD**

Q I occasionally see patients with classic Thygeson's superficial punctate keratopathy. I find these cases to be difficult to treat. What are today's best management options for these cases? Also, is there anything new regarding the disease's etiology?

A "Thygeson's superficial punctate keratitis (TSPK) was first introduced by Phillips Thygeson in the mid-twentieth century," says James Aquavella, MD, professor of ophthalmology at the University of Rochester Flaum Eye Institute. "Characteristically, it produces symptoms of photophobia, tearing and foreign body sensation."

According to Dr. Aquavella, the disease's slit lamp appearance is almost pathognomonic, typically with five to 10 intraepithelial satellite lesions in the central cornea. "The lesions are discrete, not confluent, limited in number to the central cornea, and the vision is usually only minimally impaired," he says. "There is usually bilateral involvement, although the extent may vary from left to right."

TSPK usually doesn't cause staining, but "on occasion you will find an overlying epithelial disruption," says Dr. Aquavella. "There is also minimal discharge and minimal or absent conjunctival injection."

The disease is known for frequent bouts of recurrence. While this can make management frustrating, it also makes diagnosis easier when combined with the fact that TSPK is chronic and often

bilateral, Dr. Aquavella says, because it separates the disease from similar conditions such as epidemic keratoconjunctivitis (EKC). "Usually TSPK patients still experience vision ranging from good to normal, while the vision in EKC is usually compromised," Dr. Aquavella says. "Also, unlike TSPK, EKC is not quickly reversed."

Management

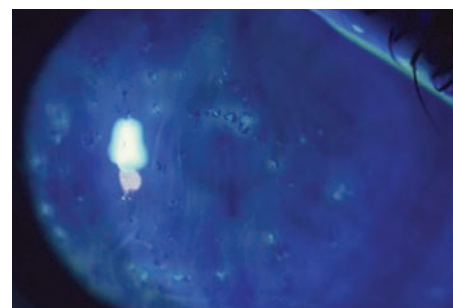
"In TSPK, pain relief is instantaneous with the application of a bandage contact lens," says Dr. Aquavella. Here, it is standard to add a prophylactic antibiotic, he adds, but antibiotics are not indicated with other treatments.

Another approach is the use of a mild steroid such as fluorometholone, loteprednol or, on occasion, 1% methylprednisolone. According to Dr. Aquavella, these will quickly heal any TSPK lesions. From there, the steroids should be slowly tapered over about a month or so. "Perhaps start with tapering the steroid to BID and then, ultimately, once or twice a week," says Dr. Aquavella. "If there is no pressure response, some patients will require an occasional extra drop to keep the condition in check."

Other options that have proven effective are cyclosporine in olive oil and tacrolimus, Dr. Aquavella says.

Etiology

The jury is still out on an exact cause for TSPK. Although viral



Standard TSPK presentation includes small, central epithelial opacities.

Photo: Ron Mellon, OD, and Randall Thomas, OD

mechanisms such as herpes simplex virus and varicella zoster virus have been suggested in early, limited studies, more recent research has not been able to show viruses as the culprit.¹⁻⁴ "When TSPK lesions clear there is no sign of viral involvement," says Dr. Aquavella. "Also, post-viral conditions often linger for longer periods."

According to Dr. Aquavella, autoimmune processes have been long suspected to play a role in TSPK, and research shows that autoimmune diseases such as Sjögren's syndrome have a positive association with the disease.⁵ Still, a definitive underlying cause for TSPK remains unknown. ■

1. Braley AEK, Alexander RC. Superficial punctate keratitis: isolation of a virus. *Arch Ophthalmol*. 1953;50:147.
2. Lemp MA, Chambers RW, Lurdy J. Viral isolation in superficial punctate keratitis. *Arch Ophthalmol*. 1974;91:8.
3. Reinhard T, Roggendorf M, Fengler I, Sundmacher R. PCR for varicella zoster virus genome negative in corneal epithelial cells of patients with Thygeson's superficial punctate keratitis. *Eye*. 2004;18(3):304-5.
4. Connell PP, O'Reilly J, Coughlan S, et al. The role of common viral ocular pathogens in Thygeson's superficial punctate keratitis. *Br J Ophthalmol*. 2007;91(8):1038-41.
5. Darrell RW. Thygeson's superficial punctate keratitis: natural history and association with HLA-DR3. *Trans Am Ophthalmol Soc*. 1981;79:486.



Something in the Way

What's behind our patient's transient episodes of dimming vision?

By Mark T. Dunbar, OD

A 53-year-old Hispanic female presented with intermittent ocular irritation and itchiness in both eyes for the past year. She does not use any drops. In addition, she reported transient episodes of dimming vision, and sometimes her vision even gets dark for several seconds. This started six months ago and happens about once a week. She felt this was occurring in both eyes.

Her medical history was significant for well-controlled hypertension. She was on amlodipine, atenolol, enalapril and lisinopril. She also reported having had brain surgery in the early 1990s in Nicaragua for removal of a frontal lobe tumor. She felt like she fully recovered from this operation and did not have any lasting effects.

On examination, her entering visual acuity with glasses measured 20/20 OU at distance and near. Confrontation visual fields were full-to-careful finger counting in both eyes. Her ocular motility testing was normal, and the pupils were equally round and reactive without an afferent pupillary defect. The anterior segment was unremarkable. Intraocular pressures measured 19mm Hg OU.

Her dilated fundus exam showed changes (*Figure 1*). An OCT and visual field was also obtained and is also available for review (*Figures 2*).

Take the Retina Quiz

1. How would you describe the patient's symptoms?

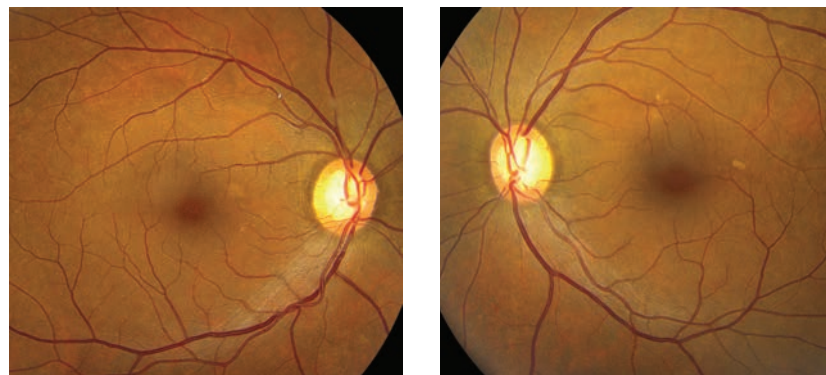


Fig. 1. These fundus photographs show our 53-year-old Hispanic patient. Although her initial complaint was a red eye, can you identify any other pathology here?

- a. Usual presbyopia changes.
 - b. Transient ischemic attacks.
 - c. Amaurosis fugax.
 - d. Visual aura.
2. What is the significant finding seen in this patient?
- a. Advanced optic nerve cupping.
 - b. Nerve fiber layer defects.
 - c. Thrombin in the retinal vein.
 - d. Cholesterol plaque in the retinal artery.
3. How would you classify these changes?
- a. Calcific.
 - b. Thrombin.
 - c. Cholesterol.
 - d. Fibrin.
4. What is the correct diagnosis for this patient?
- a. Whitman plaque.
 - b. Hollenhorst plaque.
 - c. Branch retinal artery occlusion.
 - d. Advanced glaucoma with nerve fiber layer defect.

5. How should this patient be managed?
- a. Observation.
 - b. Immediate referral for carotid evaluation.
 - c. Begin treatment with prostaglandin eye drops for IOP control.
 - d. Visual field and OCT testing.

For answers, see page 98.

Diagnosis

Our patient is describing symptoms consistent with amaurosis fugax, which is a transient loss of vision in one eye. It is usually fleeting, lasting seconds to minutes and results from transient retinal ischemia. It is most commonly due to an embolism or plaque from the ipsilateral carotid artery, but can occur from a number of other causes associated with transient ischemic attacks.¹

If the plaque is small enough, it will continue to pass through the retinal circulation with zero to minimal noticeable effects on vision.

Larger plaques can cause a complete blockage of the artery, which in turn can lead to severe ischemia and permanent loss of vision. If this occurs at the level of the optic nerve or more posterior, a complete central retinal artery occlusion can occur. If the blockage occurs along one of the branches of the central retinal artery (CRAO), a branch retinal artery occlusion can occur. Though vision loss may occur with a branch retinal artery occlusion (BRAO), it is much less devastating than a central retinal artery occlusion.

So, what is going on with our patient? On the fundus exam of the right eye, an obvious plaque can be seen along the superior temporal artery. The presence of a plaque is a clear “marker” for possible carotid artery disease or heart disease. Is this what is causing our patient to have amaurosis fugax?

Discussion

Three main types of retinal arterial emboli exist; Hollenhorst plaques, calcific emboli and platelet-fibrin plaques.

Hollenhorst plaques, perhaps the most common, are highly refractile and often glisten when the light from the indirect lens shines on the plaque. Hollenhorst plaques represent cholesterol emboli that originate from atheromatous lesions in the ipsilateral carotid artery or from the aorta. They usually become lodged in the bifurcation of one of the branches of the central retinal artery. In most instances, patients are asymptomatic and are discovered as part of a routine exam.

Calcific plaques are not refractile and have a dull white appearance. They tend to be larger and can be associated with heart valve or aorta calcification.

Platelet-fibrin emboli also dull-white in appearance but are more

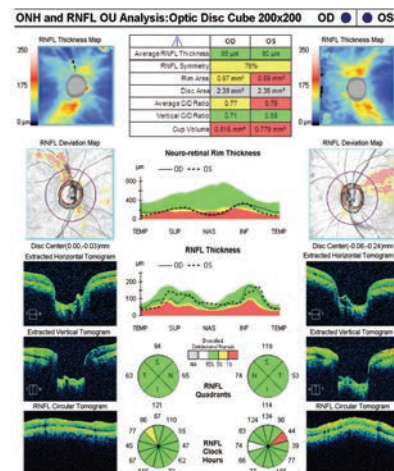
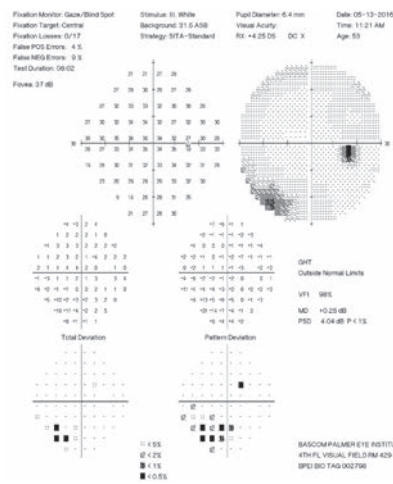


Fig. 2. How do you explain the visual changes, at right, in the patient’s right eye? Based on the RNFL, could this patient have glaucoma?

elongated. They are also associated with carotid artery disease.

The plaque seen in our patient did have a refractile, glistening appearance, so it is likely a Hollenhorst plaque; however, it is difficult to determine if our patient’s symptoms are a result of the Hollenhorst plaques passing through her retinal circulation. What’s more, even though we only see a single plaque, she had others. Most patients with Hollenhorst plaques are asymptomatic; clearly our patient has symptoms and this deserves serious attention.

Carotid artery disease is one of the major causes of stroke. Stroke itself is one of the most common causes of mortality and severe disability in adults. Patients who have had a stroke will often have preceding ischemic events such as transient ischemic attacks, amaurosis fugax, or both.^{1,2} For that reason, patients with these symptoms need a full cardiac work up, as well as carotid artery studies such as carotid duplex Doppler ultrasound. Hypercoagulable testing (antiphospholipid antibodies and homocysteine levels) and angiography may be helpful in certain cases.³

Our patient was made aware of our findings and was referred to her primary care physician that same day. We sent her there with a letter explaining our findings and was told that if she was not able to see her primary care physician that day, she should go within the week and that, if she experienced any further symptoms, she should go to the local emergency room.

She was seen one month later for follow up of her symptoms as well as for a glaucoma work-up (IOP, visual fields and OCT). She had not experienced any more amaurosis. She had seen her primary care physician and carotid Doppler studies were performed and were normal. She scheduled an echocardiogram in a few weeks’ time. Her OCT was normal but she did have a corresponding visual field defect in the same area of the Hollenhorst plaque.

She returned two years later, still doing fine and had not had any further symptoms. ■

1. Hayreh SS, Zimmerman MB. Amaurosis fugax in ocular vascular occlusive disorders: prevalence and pathogenesis. *Retina*. 2014;34(1):115-22.
2. Hayreh SS. Acute retinal arterial occlusive disorders. *Prog in Retin Eye Res*. 2011;(5): 359-94.
3. Subramanian PS. How urgent is the treatment of transient vision loss? *Br J Ophthalmol*. 2014;98(6):719-20.



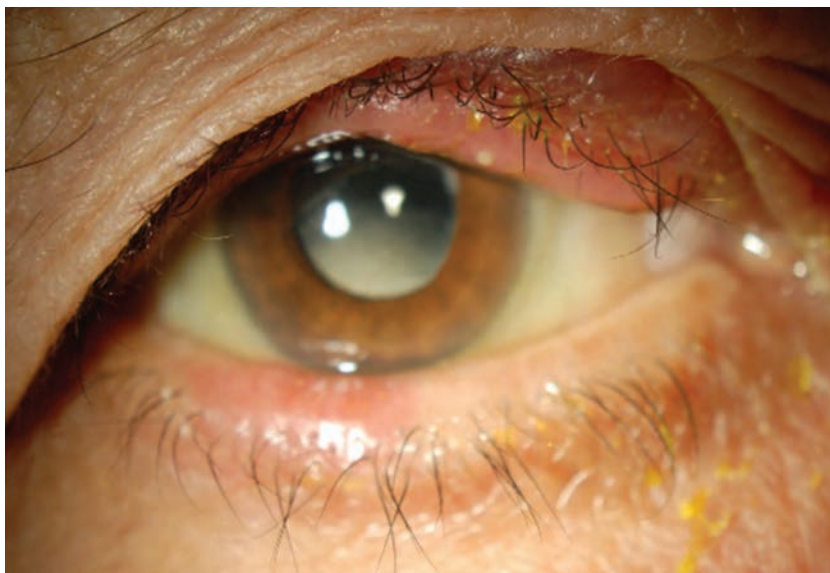Take Your Lumps

The searching for a solution that works for hordeolum, every time, continues.

By Joseph W. Sowka, OD, and Alan G. Kabat, OD

It all began with an optometry resident treating a 34-year-old woman for a painful swelling of her eyelid of four days' duration. The pain had been increasing, forcing her to seek treatment. She had a small, internal focal swelling of her right upper eyelid, which was painful to palpation. The patient reported no trauma, use of new cosmetics or other products and didn't recall being bitten by any insect. She was not ill and had no fever. After a comprehensive analysis, a resident correctly diagnosed a hordeolum and after educating the patient, had recommended hot, moist compresses and digital massage along with over the counter analgesics. After dismissing the happy patient, the resident shared the case and asked the opinions of several colleagues. Much to her surprise, each person had a different approach to treating patients with hordeola and each assured her that their approach "worked every time," leaving the young doctor more confused.

Hordeola are commonly encountered in clinical practice, and many clinicians have their own personal approach to managing this rather benign condition. A patient with a hordeolum will present with an acutely swollen and edematous upper or lower eyelid. Visual function will be normal, unless the swelling is so profound that it induces a mechanical ptosis or astigmatism. There may be an associated inflammation of the



This patient's swollen eyelid conceals a hordeolum, a common condition caused by a bacterial infection of the sebaceous glands.

conjunctiva with possible mucopurulent discharge from the glands at the margin of the eyelid. The eyelid will be painful to palpation, sometimes extremely so. There may be an associated pustular pimple-like lesion at the epidermis or, more commonly, at the lid margin. Often, patients will present with a significant blepharitis concurrently. Hordeolum is one of the most common acquired lid lesions in children.¹

Development

The sebaceous glands of the lids, the meibomian glands and glands of Zeis are the sites of origin of hordeola. Twenty to 30 meibomian glands are located in the upper lid and 10 to 20 in the lower lid and in the tarsal plate. Unlike the meibo-

mian glands, the glands of Zeis are associated with the eyelash follicles. These glands produce the superficial lipid layer of tears.¹

A hordeolum represents a bacterial infection of these glands of the eyelid with subsequent abscess formation. This will be associated with a tender, inflamed swelling at the lid margin, often pointing anteriorly through the skin. If the deeper glands are involved, the hordeolum is considered internal and is less well circumscribed in appearance. In these cases, you will see more diffuse swelling of the tarsus. The lesion may enlarge and discharge either through the tarsal conjunctiva or through the skin. The literature shows cases of multiple recurrent hordeola associ-

ated with selective IgM deficiency.² Studies also show abnormal triglyceride fatty acid composition with chronic blepharitis associated with hordeola.³

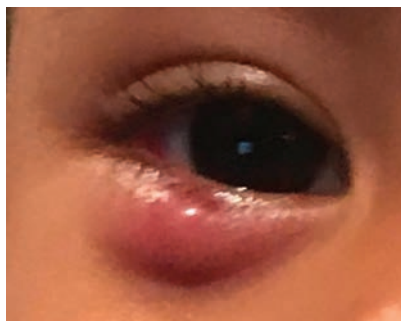Progression

The most commonly encountered organisms in hordeola are *Staphylococcus aureus* and *Staphylococcus epidermis*.⁴ Acute and chronic inflammation associated with hordeola may result in a hard retention cyst known as a chalazion, especially if it is improperly treated. Spread of infection to neighboring glands or other lid tissue anterior to the tarsal plate may lead to the formation of a preseptal cellulitis. While uncommon, hordeola can produce ocular surface disruption as a thickened lid rubs against the cornea and conjunctiva during blinking.⁴

Treatment

So, what are the options for treating an acute, painful hordeolum? First, remember that the infection is generally self-limiting and will often resolve within a week or two with spontaneous drainage of the abscess.¹ Traditionally, the most common treatment involves the use of hot compresses with digital massage along with topical antibiotic solutions and ointments. Some advocate for oral antibiotics instead of topical treatment due to better absorption with subsequently higher therapeutic concentrations. Incision and curettage may also be helpful.

In a survey study involving 501 ophthalmologists, warm compress usage was employed by 92% of respondents.⁶ Additionally, combined topical and oral antibiotics were typically used.⁶ Only 2.4% of respondents used oral antibiotics alone, and 4.2% used no oral antibiotics.⁶ Incision and curettage



Treating a hordeolum, such as the one seen in this patient's lower lid, includes using hot compresses, digital massage, topical antibiotics and ointments.

was performed only in cases with a flocculated mass, larger lesions or if requested by patients. First choice antibiotics were a combination of topical neomycin, polymyxin and gramicidin eye drop, chloramphenicol eye ointment and oral dicloxacillin.⁶

Clearly, doctors have numerous approaches to handling this common infection, likely with varying success. When there is debate about best treatment and practices, it is always best to look at evidence-based medicine. Randomized, controlled clinical comparative trials give the best evidence on how to manage patients when there are numerous options and speculations. Unfortunately, hordeolum, though common, is considered benign and self-limiting and, as such, has garnered little in the way of clinical research. Reviews of the best available literature did not find any evidence for or against the effectiveness of nonsurgical interventions for the treatment of an internal hordeolum.⁷ The few references specific to treating acute internal hordeola were reports of interventional case series, case studies or other types of observational study designs and were published more than 20 years ago.⁷

It is our feeling that topical anti-

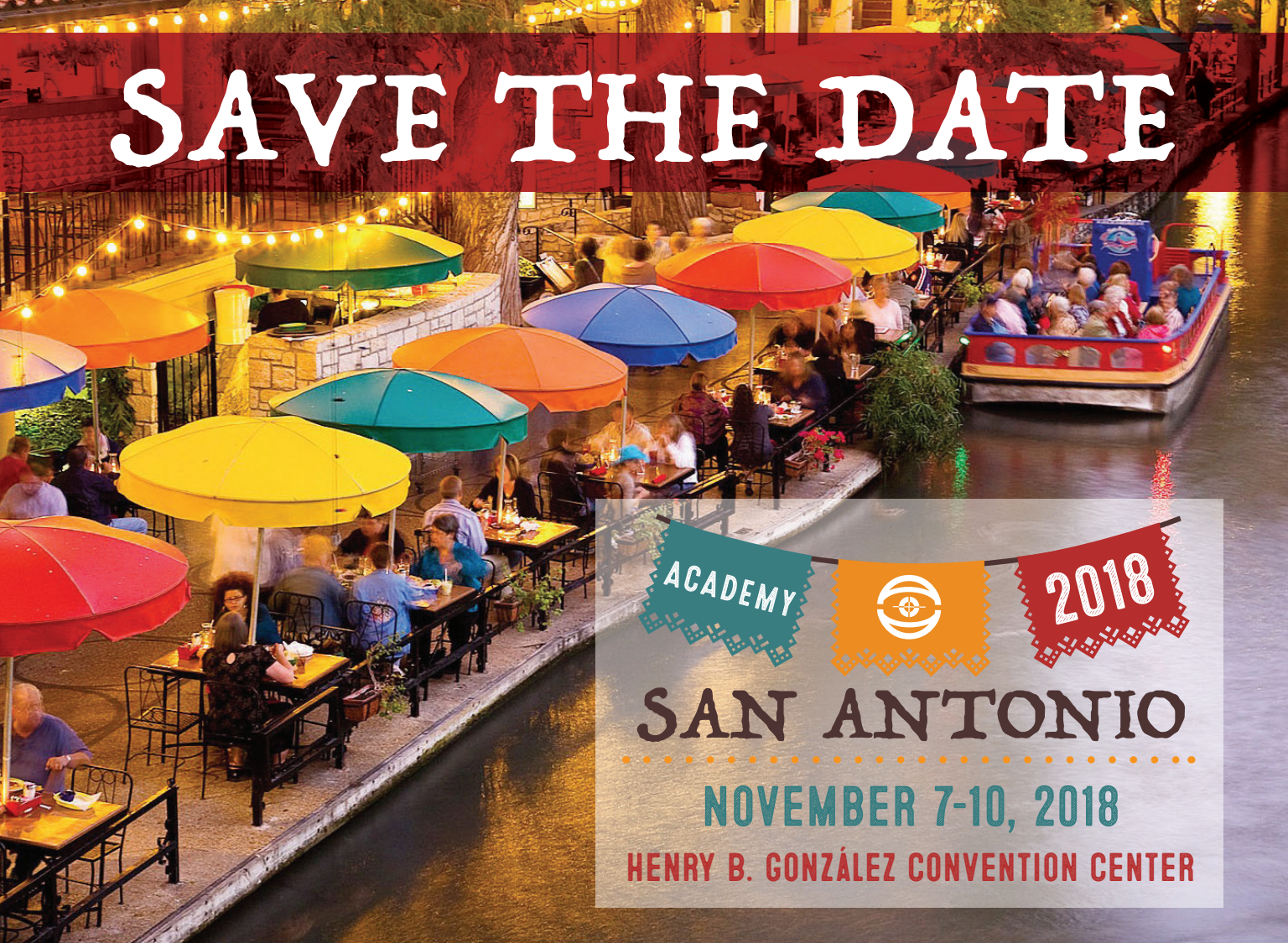biosis offers very little therapeutic benefit, since this mode likely does not offer sufficient intratissue concentrations of antibiotics to be therapeutic. However, topical antibiotics are prudent if there is significant concomitant blepharitis. We believe that oral antibiotic therapy is necessary to optimally treat hordeola. If the hordeolum is external and there is a pimple formed, then the lesion can be lanced and drained (anesthetic is usually unnecessary), or nearby lashes can be epilated to enhance drainage. Digital expression of purulent material in office will expedite healing, but is not absolutely necessary. Antibiotic therapy could include dicloxacillin 250mg PO Q6h; erythromycin 250mg PO QID; or amoxicillin 500mg PO TID for 10 days. Cephalexin 500mg BID for seven to 10 days is also an excellent, economical choice. Cold compresses will help to suppress inflammation and pain, while warm compresses will enhance pointing and drainage.

Clearly, optometrists have several acceptable methods to manage patients with hordeola. Each probably has varying degrees of success and therapies can be patient specific.

In our resident's case, she walked away still confused with yet another opinion. But we assured her that our approach "works every time." ■

1. Lederman C, Millier M. Hordeola and chalazia. *Pediatrics in review* 1999; 20(8):283-4.
2. Kiratli HK, Akar Y. Multiple recurrent hordeola associated with selective IgM deficiency. *J AAPOS*. 2001;5(1):60-1.
3. Shine WE, McCulley JP. Meibomian gland triglyceride fatty acid differences in chronic blepharitis patients. *Cornea*. 1996;15(4):340-6.
4. Maldonado MJ, Juberias JR, Moreno-Montanes J. Extensive corneal epithelial defect associated with internal hordeolum after uneventful laser in situ keratomileusis. *J Cataract Refract Surg*. 2002;28(9):1700-2.
5. Brun SC, Jakobiec FA. Kaposi's sarcoma of the ocular adnexa. *Int Ophthalmol Clin*. 1997;37(4):25-38.
6. Panicharoen C, Hirunwiwatkul P. Current pattern treatment of hordeolum by ophthalmologists in Thailand. *J Med Assoc Thai*. 2011 Jun;94(6):721-4.
7. Lindsley K, Nichols JJ, Dickersin K. Non-surgical interventions for acute internal hordeolum. *Cochrane Database Syst Rev*. 2017 Jan 9;1:CD007742.

SAVE THE DATE



ACADEMY



2018

SAN ANTONIO

NOVEMBER 7-10, 2018

HENRY B. GONZÁLEZ CONVENTION CENTER

Find your inspiration for excellence.

What will you miss if you're not there?

- Engaging with innovative speakers to make you better prepared for your day to day clinical practice.
- Connecting and reuniting with your peers.
- Learning the latest research discoveries that will help you solve clinical problems.
- Discovering the latest technology in the exhibit hall.
- Networking with the best and brightest in optometry.
- Enjoying a truly unforgettable trip to charming San Antonio.



AMERICAN ACADEMY
of OPTOMETRY

Registration opens May 21. Learn more at aaopt.org/2018.



The Devil is in the Details

When a glaucoma suspect progresses, it's time to transition from monitoring to treating. But what happens when devices differ? **By James L. Fanelli, OD**

In June 2012, a 57-year-old Caucasian female presented to the office with complaints related to headaches and periocular discomfort that progressed over several months. She was a low hyperope wearing a hyperopic presbyopic spectacle prescription that was about five years old at the time.

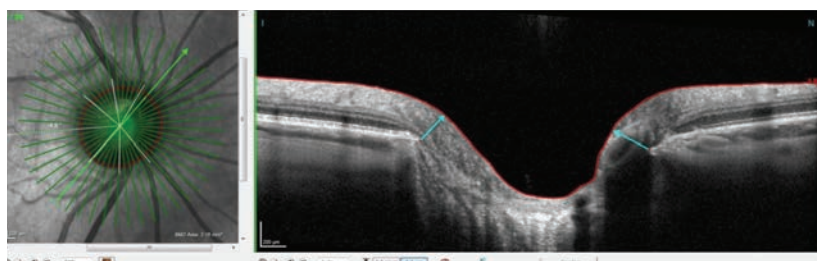
She was taking no medications and reported no allergies to medications.

Refractively, she had an expected change in her spectacle prescription of increased hyperopia and presbyopia, best corrected to 20/20 OD, OS, OU.

A slit lamp exam of her anterior segments was unremarkable. Applanation tensions at that visit were 15mm Hg OD and OS at 10:39am. Slit lamp estimation of her anterior chamber angles demonstrated wide-open angles in both eyes.

Through dilated pupils, her crystalline lenses were clear bilaterally. Her cup-to-disc ratios were 0.65 x 0.75 OD and 0.65 x 0.65 OS, with discs that were average size. There was slight thinning of the temporal rim in both eyes, with a common appearance of sloping temporal margins of the neuroretinal rim into the optic cup. Her macular, vascular and retinal evaluations were normal in both eyes.

I asked her if anyone had mentioned that she had some characteristics to her optic nerves that put her at risk for glaucoma, and she said no. She also denied a

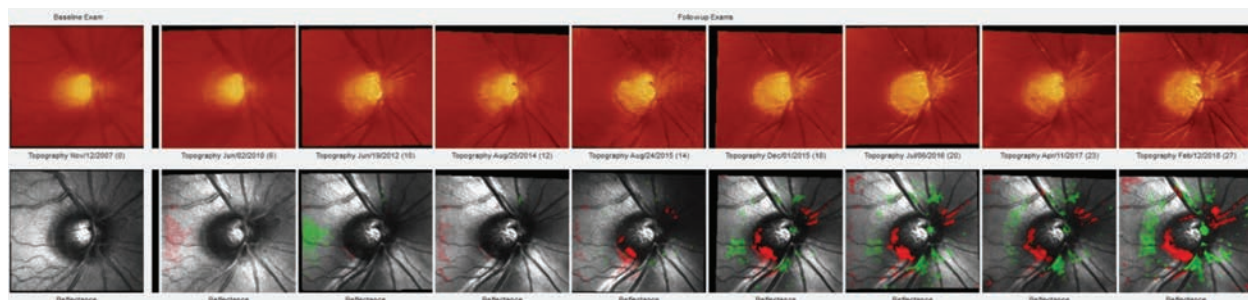


This radial OCT image of the right eye shows a commonly seen steep nasal margin and a more sloping inferotemporal margin.

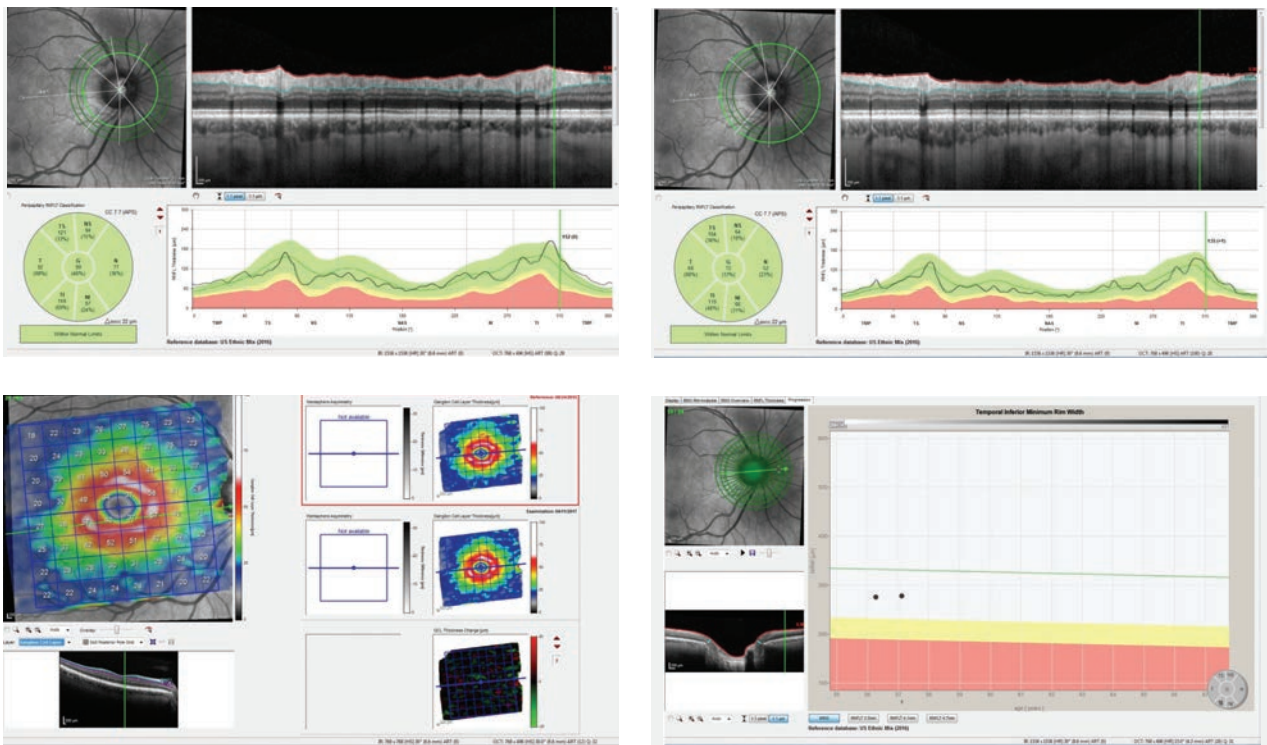
family history of glaucoma. I explained my findings of suspicious discs and, since she was dilated, I took the opportunity to obtain stereo optic nerve images. She was scheduled for a full glaucoma work-up in the next few weeks.

Evaluation

As scheduled, she presented for the glaucoma work-up, which included pachymetry, morning IOP readings, gonioscopy, threshold visual fields and Heidelberg retina tomograph (HRT 3) and optical coherence tomography (OCT) imaging of the optic nerves. At this visit, pachymetry readings were 478µm OD and 479µm OS. Applanation tensions at 9:15am were 16mm Hg OD and 17mm Hg OS. Gonioscopy demonstrated wide-open angles with minimal trabecular pigmentation, a flat iris-to-angle approach and no angle abnormalities. Threshold standard automated perimetry (SAP) field studies were clear and reliable in both eyes. HRT 3



HRT 3 imaging shows a distinct change in the IT neuroretinal rim of our patient's right eye, first noted in 2015.



Top row, temporal-superior-nasal-inferior-temporal RNFL circle scans of two different diameters, with the top right image showing the circle scan obtained at a 4.7mm diameter scan. Bottom row left, this macular ganglion cell layer thickness change map of the patient's right eye shows stability. Bottom right, this IT BMO OCT scan with minimum rim shows stability over time.

nerve imaging confirmed the clinical appearance of the optic nerves with a large cup, a thinned temporal neuroretinal rim and Moorfields Regression Classification as statistically borderline optic nerves in both eyes. The RNFL circle scan of both eyes was statistically normal.

Given the findings at that time, I diagnosed her as a glaucoma suspect only, as there was no frank evidence of glaucoma either structurally or functionally. I asked her to follow up in a year.

Over the subsequent years, she presented annually as directed, and essentially all findings remained stable, though we did substitute threshold flicker-defined form visual fields for SAP fields, looking specifically for early field loss. These too remained stable. However, in the summer of 2015, there appeared to be a change in the inferotemporal neuroretinal rim of the OD from baseline, while all other indices remained stable. Given that her imaging to this point was stable and consisted of high quality images, this change was worthy of further investigation. Accordingly, I asked her to return in four months for repeat nerve imaging. At that visit in December 2015, the structural defect had worsened in the right eye, indicating a conversion to early

glaucoma. Her imaging of the left eye remained stable insofar as the HRT 3 images were concerned. And her OCT RNFL circle scans also remained stable.

Accordingly, she was initially managed with 0.5% timolol QAM to the right eye, and observation of the left eye. Post treatment IOP readings in the right eye have averaged 11mm Hg to 12mm Hg, and those of the unmedicated left eye have remained in the mid-teen range.

Discussion

Once the patient converts from a glaucoma suspect to a patient needing intervention, I usually see them a bit more frequently, and as such, I followed the same protocol with this patient. At this point in our management, each visit is tasked with determining whether the patient remains stable or not, which, for glaucoma, requires an evaluation of both the structural and functional aspects of the eye.

One of the advantages of having adequate instrumentation to evaluate these patients is that one can see, rather readily, when it occurs, change over time. One of the disadvantages to having a variety of ways

to evaluate stability over time is that sometimes the quantity of information becomes overwhelming. With too much data in our hands, it's easy to see situations where busy clinicians might not evaluate all of the pieces to the diagnostic puzzle and miss significant changes.

So how much technology is too much? And how much is too little? Those answers are going to vary from practice to practice, and there are no concrete answers I can give to you. But this case highlights why having multiple technologies can help you to offer personalized care, if you take the time to sift through the data. The radial OCT image on page 89 shows one of the more common presentations of an optic nerve with temporal sloping margins, especially in the IT sector where the HRT 3 image was showing changes.

When we look at OCTs of change, we can look at several locations. Most optometrists probably first look at the periopic RNFL circle scan. Now that we are scanning several different diameter RNFL circle scans, we can detect changes that are occurring at various distances from the optic nerve, and not just the standard 3.5mm circle scan.

Finally, peeling back even more detail, we can take a look specifically at the IT sector of the OCT Bruch's membrane opening (BMO) map for change. Given the ability to now look at BMO in various sectors of the optic nerve, and the statistical capability of looking for change over time in these individual sectors, we can now look at not only the macular and periopic RNFL areas, but also at the neuroretinal rim. Remember, in this case, she showed signs of conversion in the IT sector of the neuroretinal rim as seen on the HRT 3. This same sector, as seen on the BMO OCT scan, over two visits, shows complete stability.

Changes

The key diagnostic piece to this puzzle is that the initial change occurred in the IT sector of the OD, as measured by one instrument. Subsequent measurements of the same sector of the neuroretinal rim with a different instrument (OCT) show no change. And it is in this area where she would most likely show continued progression if it occurred.

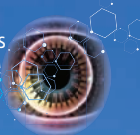
Instruments change. Technology changes. Optic nerves change, if they are worsening. Knowing where to look is half the battle. Looking through all the data, though challenging, is what makes for excellent clinical care. ■

Akorn Consumer Health	2
Phone	(800) 579-8327
.....	www.akornconsumerhealth.com
Akorn Pharmaceuticals	7
Phone	(800) 932-5676
.....	www.akorn.com
Alcon Laboratories	23, 31, 100
Phone	(800) 451-3937
Fax	(817) 551-4352
Bausch + Lomb	9, 10, 57, 99
Phone	(800) 323-0000
Fax	(813) 975-7762
Beaver-Visitec International, Inc.	5
Phone	(866) 906-8080
Fax	(866) 906-4304
.....	www.beaver-visitec.com
CooperVision	16-17
Phone	(800) 341-2020
Haag-Streit	25
Phone	(800) 627-6286
Fax	(603) 742-7217
Imprimis Pharmaceuticals, Inc.	19
Phone	(858) 704-4040
Fax	(858) 345-1745
.....	www.imprimispharma.com
Katena	53
Phone	(800) 225-1195
.....	www.katena.com
Keeler Instruments	21, 61
Phone	(800) 523-5620
Fax	(610) 353-7814
Lacrimedics, Inc	55
Phone	(800) 367-8327
Fax	(253) 964-2699
.....	info@lacrimedics.com
.....	www.lacrimedics.com
M&S Technologies	33
Phone	(877) 225-6101
Fax	(847) 763-9170
Menicon	35
Phone	(800) MENICON
.....	information@menicon.com
.....	www.meniconamerica.com
Reichert Technologies	45
.....	47, 49, 51
Phone	(888) 849-8955
Fax	(716) 686-4545
.....	www.reichert.com
S4OPTIK	75, 77, 79
Phone	(888) 224-6012
Shire Ophthalmics	36-43
.....	www.shire.com
X-Cel Speciality Contacts	29
Phone	(877) 336-2482
.....	www.xcelspecialitycontacts.com

This advertiser index is published as a convenience and not as part of the advertising contract. Every care will be taken to index correctly. No allowance will be made for errors due to spelling, incorrect page number, or failure to insert.

Earn up to
29 CE
Credits*

NEW TECHNOLOGIES
& TREATMENTS IN
2018 EYE CARE



REVIEW OF OPTOMETRY®
EDUCATIONAL MEETINGS OF CLINICAL EXCELLENCE

OCCRS

OPTOMETRIC CORNEA, CATARACT
AND REFRACTIVE SOCIETY

SAN DIEGO

APRIL 26-29, 2018

We invite you to attend a unique joint meeting held at the San Diego Marriott Del Mar.

Review's New Technologies & Treatments in Eye Care and Optometric Cornea, Cataract and Refractive Society's annual meetings are combined to provide you with up to 29* COPE CE credits in one weekend.

Program Chairs:



Paul M. Karpecki, OD, FAAO
Review Program Chair



David Friess, OD, FAAO
President, OCCRS



San Diego Marriott Del Mar

11966 El Camino Real
San Diego, California 92130
Phone: 858-523-1700

Three Ways to Register

Online: www.reviewofoptometry.com/sandiego2018

Call: 866-658-1772 • **E-mail:** reviewmeetings@jobson.com

Convenient opportunities to register for one or both meetings.**

A limited number of rooms have been reserved at **\$199 per night**. Please make reservations with the hotel directly at 858-523-1700. For group rate, mention "New Technologies and Treatments in Eye Care".

REGISTER ONLINE: WWW.REVIEWOFOPTOMETRY.COM/SANDIEGO2018

Administered by
Review of Optometry®



*Approval pending



**Additional CE fees if attending both meetings. Agenda subject to change.
See website for details: www.reviewofoptometry.com/SanDiego2018

Review of Optometry® partners with Salus University for those ODs who are licensed in states that require university credit



The MIGS Just Keep on Coming

Two new devices expand the treatment portfolio and target novel pathways.

By Christopher Kruthoff, OD

Minimally invasive glaucoma surgeries (MIGS) are quickly earning a place in the glaucoma treatment regimen. Their demonstrated efficacy, along with improved safety and faster recovery compared with traditional surgeries such as trabeculectomy, have made MIGS a good option for patients showing glaucomatous damage, progression or even those who want to reduce their dependence on topical therapy.¹ Many MIGS target the traditional outflow pathway, either by bypassing or removing the trabecular meshwork or by reconstructing Schlemm's canal. But two recently approved devices have different approaches.

Follow a New Path

The CyPass Micro-Stent (Alcon), a fenestrated stent that connects the anterior chamber to the supraciliary space, is used with cataract surgery to reduce intraocular pressure (IOP) in patients with mild to moderate primary open-angle glaucoma. Using the corneal incisions already created for cataract extraction, the surgeon places the stent posterior to the scleral spur. The curved design allows natural passage into the supraciliary space, while retention rings are designed to keep the stent in place. In the COMPASS trial, which compared cataract extraction plus CyPass insertion with cataract

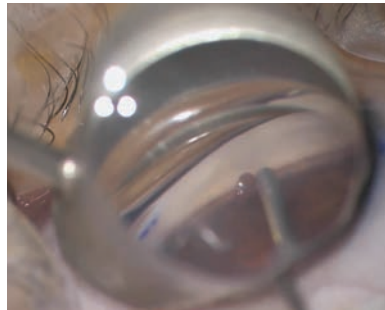

Photo: Constance Orlake, MD, MSCE

With the CyPass in place, only the most proximal retention ring and collar are visible.

extraction alone, the group receiving CyPass showed a 7.4mm Hg reduction in mean IOP, compared with 5.4mm Hg with only cataract extraction at two years.²

Unlike the CyPass, the Xen 45 gel stent (Allergan) mimics the outflow pattern of traditional glaucoma procedures by draining aqueous into the subconjunctival space, but with the less invasive *ab interno* approach. This stent is indicated as a stand-alone procedure or with cataract surgery for patients with open-angle, pseudoexfoliative or pigmentary glaucoma who failed maximum topical therapy or other filtering procedures. The Xen, preloaded in a single-use injector, is inserted through the trabecular meshwork, creating a scleral channel through which the stent connects the anterior chamber to the subconjunctival space. A clinical trial of 65 patients demonstrated a drop in IOP from a mean of 25.1mm Hg preoperatively to 15.1mm Hg postoperatively, with a reduction in medications from 3.5 before the procedure to 1.7 after.³

Postoperative Considerations

As with standard cataract surgery, patients will be prescribed a combination of antibiotics, steroids and nonsteroidal anti-inflammatory drugs after the procedure. Glaucoma drops may be adjusted or discontinued depending on the resulting postoperative IOP.

Gonioscopy is critical in the management of any MIGS procedure and is especially useful during pressure spikes to monitor for proper stent placement, potential iris obstruction or hemorrhage through the stent. Patients should also be watched closely in the postoperative period for hypotony, hyphema, iritis and corneal edema. Patients with the Xen stent should also be observed for any flattening of the subconjunctival bleb, as needling of the bleb was required in 32.3% of patients.³

MIGS are an exciting addition to the glaucoma management regimen. These two new procedures in particular provide many patients yet another avenue for preventing glaucomatous damage. ■

Dr. Kruthoff practices at Virginia Eye Consultants in Norfolk, Va., with a focus on perioperative glaucoma care.

1. Saheb H, Ahmed II. Micro-invasive glaucoma surgery: current perspectives and future directions. *Curr Opin Ophthalmol*. 2012;23(2):96-104.
2. Vold S, Ahmed II, Craven ER; CyPass Study Group. Two-year COMPASS trial results: supraciliary microstenting with phacoemulsification in patients with open-angle glaucoma and cataracts. *Ophthalmology*. 2016;123(10):2103-12.
3. Allergan. Directions for use for the XEN glaucoma treatment system. https://allergan-web-cdn-prod.azureedge.net/actavis/actavis/media/allergan-pdf-documents/labeling/xen/dtu_xen_glaucoma_treatment_system_us_feb2017.pdf. Accessed February 26, 2018.



To see a video of this procedure, visit www.reviewofoptometry.com, or scan the QR code.

Merchandise Offered

UNPARALLELED SERVICE | DISCOUNTED RATES | FREE FIRST CLASS SHIPPING*



Call for our current price list
or visit our website to register
866.923.5600
www.National-Lens.com
* in stock products, as available

Contact Lenses

Impressions

Color Contact Lens

Unleash your true color!

Amethyst	* Brown	* Grey	* Green	
Turquoise	* Hazel	* Honey	* Pure Hazel	* True Sapphire

Impressions colored contacts blend naturally with your patients eyes to create a beautiful look. Available in nine dazzling opaque colors of which Brown, Grey, Green, Hazel, Honey, Pure Hazel and True Sapphire are available in RX PL to -8.00. Impressions are fun, hip, fashionable and very competitively priced to help your bottom line. POP materials and posters are available upon request.

Available Exclusively at

NATIONAL LENS
America's Leading Discount Lens Distributor
1-866-923-5600 • 1-866-923-5601 FAX
www.national-lens.com

Continuing Education

OCULAR SYMPOSIUM

Lectures in Ocular Diagnosis and Treatment

Formal Lectures for Optometrists
by Noted Subspecialists in Ophthalmology

Friday, Saturday, Sunday, June 1-3, 2018
24 hours CE credits (8 hours each day)
COPE APPROVAL PENDING

SAN FRANCISCO, CALIFORNIA

Refractive Surgery	Glaucoma	Cataract Surgery
Oculoplastics	Eyelid Lesions	Corneal Disease
Neuro-ophthalmology	Retinal Disease	Ocular Pediatrics

For information call or write:
Ocular Symposium • P.O. Box 640327 • San Francisco • CA • 94164
(415) 278-9940 • FAX (415) 345-1165
e-mail: ocularsymp@aol.com

Products and Services



The key to making practice financing simple.
Put our expertise to work for you to accomplish your professional goals.
Under the guidance of Michael Hildebrandt, MHA CPA, Access Healthcare Capital offers loan services to open, purchase, or modernize Optometry Practices. Other loan services include, Equipment Financing, Restructuring, and Partnership Buy-In/Buy-Outs.

Easy App Up To \$250,000

- 100% Financing plus working capital
- Simplified Processing for loans up to \$350,000
- Partnership Buy-In Programs
- Tax & Accounting Services
- Terms up to 15 years
- Application Only for equipment and technology purchases
- Consulting

We also offer Consulting, Tax, and Accounting Services. Call to schedule a phone consultation today.
www.accesshealthcarecapital.com • michael@narxeye.com • 1.888.727.4470

#1 NUTRACEUTICAL PROGRAM

- Tested And Proven
- Pharmaceutical Grade
- Great Office Flow And Huge Income Potential
- Carotenoid Scanner Included
- Manage AMD
- Setup/Training Included

CALL OR EMAIL FOR FREE CONSULT
618-889-3825
JACOBSANDCRABTREE2@GMAIL.COM



**Do you have
CE Programs?**

CONTACT US TODAY
FOR CLASSIFIED ADVERTISING
Toll free: 888-498-1460
E-mail: sales@kerhgroup.com

Career Opportunities

Staff Optometrist Wanted

Bard Optical is a family owned full-service retail optometric practice with 22 offices (and growing) throughout Central Illinois. Bard Optical prides itself on having a progressive optometric staff whose foundation is based on one-on-one patient service. We are currently accepting CV/resumes for Optometrists to join our medical model optometric practice that includes extended testing. The practice includes but is not limited to general optometry, contact lenses and geriatric care. Salaried, full-time positions are available with excellent base compensation and incentive programs and benefits. Some part-time opportunities may also be available.

Current positions are available in Bloomington/Normal, Decatur/Forsyth, Peoria, Sterling and Canton as we continue to grow with new and established offices.

Please email your information to mhall@bardoptical.com or call Mick at 309-693-9540 ext 225. Mailing address if more convenient is:
Bard Optical
Attn: Mick Hall, Vice President
8309 N Knoxville Avenue
Peoria, IL 61615

Bard Optical is a proud Associate Member of the Illinois Optometric Association.



www.bardoptical.com

Practice For Sale

PRACTICE SALES & APPRAISAL

Expert Services for:

- Buying or Selling a Practice**
- Practice Appraisal**
- Practice Financing**
- Partner Buy-in or Buy-out**

Call for a Free Consultation
(800) 416-2055

www.TransitionConsultants.com



Practice Sales • Appraisals • Consulting
www.PracticeConsultants.com

**PRACTICES FOR SALE
NATIONWIDE**

Visit us on the Web or call us to learn more about our company and the practices we have available.

info@PracticeConsultants.com

800-576-6935

www.PracticeConsultants.com

Faculty



ASSISTANT PROFESSOR POSITIONS: CONTACT LENSES, PRIMARY CARE, LOW VISION, AND PEDIATRICS
 (Full-time non-tenure track faculty positions for the Chicago College of Optometry)

RESPONSIBILITIES: Candidates are expected to be highly knowledgeable in the field of Cornea and Contact Lenses, Primary Care, Low Vision, or Pediatrics and can develop and teach courses and/or laboratories in the subject area. The candidate must also be able to provide direct patient care and clinical instruction to professional students as well as residents, and be involved in interdisciplinary practice with other educational professionals.

Candidates must be willing to actively participate in curricular assessment, professional development, student counseling and service activities within the college, university and the scientific community. Successful candidates are also expected to be involved in research and scholarly activities, and have a sincere commitment to optometric education, community service and patient care. Primary duties include, but are not limited to:

- | | | |
|--|--|--|
| <p>a) Teaching</p> <ul style="list-style-type: none"> Developing and delivering lectures and/or laboratories for related areas, as assigned; Embracing and enhancing the didactic philosophies in the O.D. program; Maintaining and expanding the high quality clinical practice environment for optometry students on rotation; Precepting students on clinical rotation at the Midwestern University Eye Institute; | <p>b) Service</p> <ul style="list-style-type: none"> Helping to maintain and grow the state of the art optometry program with a strong interdisciplinary focus that meets the needs of patients in the surrounding community; is efficient, patient friendly, and cost-effective; Working closely together with all optometry and ophthalmology faculty to provide a complete range of eye and vision care services; Participating in leadership roles in state, regional, and national optometry organizations; | <ul style="list-style-type: none"> Participating on College and University committees, as assigned; Participating in College and University service activities. <p>c) Scholarly activity</p> <p>Engaging in research and scholarly activity, including presentations at scientific meetings, research, and publication in peer reviewed journals sufficient to qualify for academic advancement in a non-tenure track position.</p> |
|--|--|--|

QUALIFICATIONS: Candidates must possess a Doctor of Optometry degree from an ACOE-accredited institution, must have completed an ACOE-accredited residency, and must be eligible for an optometric state license in the state in which the college is located. Primary eye care clinical expertise is also required.

CONTACT INFORMATION: Contact information: Interested applicants should apply online at www.midwestern.edu and include curriculum vitae and letter of interest specifying the position and college that he/she wishes to be considered for. Inquiries may be directed to Dr. Melissa Suckow, Dean; Midwestern University: msucko@midwestern.edu.

Midwestern University is an Equal Opportunity/Affirmative Action employer that does not discriminate against an employee or applicant based upon race, color, religion, gender, national origin, disability, or veterans status, in accord with 41 C.F.R. 60-1.4(a), 250.5(a), 300.5(a) and 741.5(a).

Equipment for Sale

A certified pre-owned OCT system from Optovue delivers outstanding performance and value. And to make your decision even easier, Optovue protects your investment with a one-year warranty.

Act fast — a limited number of pre-owned systems are available!

Check System Availability
www.optovue.com/feature/certified-pre-owned

Equipment and Supplies



It's What the Best Pretest on!
(800) 522-2275
www.optinomics.com
sales@optinomics.com

Place Your Ad Here!
 Toll free: **888-498-1460**
 E-mail: sales@kerhgroup.com

May 2018

- **2-4.** *CE in Italy/Europe.* Hotel Torbräu, Munich, Germany. Hosted by: James Fanelli. Key faculty: Joseph Pizzimenti, Lorraine Lombardi, Leonard Messner, James Fanelli. CE hours: 12. For more information, email James Fanelli at jamesfanelli@ceinitaly.com, call (910) 452-7225 or go to www.ceinitaly.com.
- **5-7.** *CE in Italy/Europe.* Kongresshaus, Heidelberg, Germany. Hosted by: James Fanelli. Key faculty: Joseph Pizzimenti, Lorraine Lombardi, Leonard Messner, James Fanelli. CE hours: 12. For more information, email James Fanelli at jamesfanelli@ceinitaly.com, call (910) 452-7225 or go to www.ceinitaly.com.
- **6.** *2018 Coding Update.* University of Missouri St. Louis JC Penney Conference Center, St. Louis, MO. Hosted by: University of Missouri St. Louis College of Optometry. Key faculty: John McGreal. CE hours: 4. For more information, email Erin Schaeffer at schaeffere@umsl.edu, call (314) 516-5615 or go to optometry.umsl.edu/CE_Courses/index.html.
- **17-20.** *New Technologies and Treatments in Eye Care Orlando 2018.* Disney's Yacht Club, Orlando, FL. Hosted by: *Review of Optometry*. Key faculty: Paul Karpecki. CE hours: 18. For more information, email reviewmeetings@jobson.com, call (866) 658-1772 or go to www.reviewofoptometry.com/orlando2018.
- **17-20.** *Pennsylvania Optometric Association Spring Congress.* Seven Springs Mountain Resort, Seven Springs, PA. Hosted by: Pennsylvania Optometric Association. CE hours: 22 total, 20 per OD. For more information, email Ilene Sauertieg at ilene@poaeyes.org, call (717) 233-6455 or go to www.poaeyes.org.
- **30.** *The Eleventh Central Jersey Optometric Seminar.* CentraState Medical Center, Freehold, NJ. Hosted by: Optometry on West 44th. Key Faculty: Walter Whitley. CE hours: 4. For more information, go to www.optometryonwest44th.com.
- **31-June 3.** *Oregon's Meeting.* Mt. Bachelor Village Resort, Bend, OR. Hosted by: Oregon Optometric Physicians Association. Key faculty: Tracy Doll, April Jasper, Derek Cunningham, Fraser Horn. CE hours: 15. For more information, email Lynn Olson at lynne@oregonoptometry.org, call (800) 922-2045 or go to www.oregonoptometry.org.

June 2018

- **4-7.** *Indian Health Service Biennial Eye Care Meeting.* Marshall B. Ketchum University (MBKU), Fullerton Campus, Fullerton, CA. Hosted by: MBKU Southern California College of Optometry and Indian Health Service. CE hours: 25. For more information, email Antoinette Smith at asmith@ketchum.edu, call (714) 872-5684 or go to www.ketchum.edu/ce.
- **6-10.** *Art & Science of Optometric Care, A Behavioral Perspective.* Nova Southeastern University, Fort Lauderdale, FL. Hosted by: The Optometric Extension Program Foundation. Key faculty: John Abbondanza. CE hours: 35. For more information,

email Karen Ruder at karen.ruder@oep.org, call (410) 561-3791 or go to www.oep.org.

- **7-10.** *Utah Optometric Association (UOA) Annual Congress.* The Zermatt Resort, Midway, UT. Hosted by: UOA. Key faculty: Bruce Onofrey. CE hours: 20. For more information, email Alyssa White at alyssa@utaheyedoc.org, call (801) 364-9103 or go to www.utaheyedoc.org.
- **8-10.** *Everything Therapeutic: Houston.* University of Houston College of Optometry (UHCO), Houston. Hosted by: UHCO. Key faculty: Bruce Onofrey. CE hours: 24. For more information, email optce@central.uh.edu, call (713) 743-1900 or go to ce.opt.uh.edu.
- **8-10.** *Northern Educational Escape.* Delta Hotels, Quebec City, Canada. Hosted by: Optometric Education Consultants. Key faculty: Greg Caldwell, Joseph Pizzimenti, Barry Frauens, Rim Makhoulf. CE hours: 15. For more information, email Vanessa McDonald at optoec@gmail.com, call (954) 262-4224 or go to www.optometricedu.com.
- **20-24.** *AOA/Optometry's Meeting.* Colorado Convention Center, Denver, CO. Hosted by: American Optometric Association and American Optometric Student Association. CE hours: 215 total, 43 per OD. For more information, email cspampani@aoa.org, call (314) 983-4124 or go to optometrymeeting.org.

July 2018

- **1-8.** *Tropical CE Ocean Reef 2018.* Ocean Reef Club, Florida Keys. Hosted by: Tropical CE. Key faculty: Diana Shechtman. CE hours: 20. For more information, email Stuart Autry at jsautry@tropicalce.com, call (281) 808-5763 or go to www.tropicalce.com.
- **8-18.** *Therapeutic Pharmaceutical Agents Certification/ Board Review Course.* Nova Southeastern University College of Optometry (NSUCO), Fort Lauderdale, FL. Hosted by: NSUCO. Key faculty: Joseph Sowka, Julie Tyler, Chandra Mickles, Diana Shechtman, Sherrol Reynolds. CE hours: 100. For more information, email Vanessa McDonald at oceaa@nova.edu, call (954) 262-4224 or go to optometry.nova.edu/ce/index.html.
- **12-15.** *July Advanced Procedures.* Oklahoma College of Optometry (OCO) Academic Wing, Tahlequah, OK. Hosted by: OCO. Key faculty: Nate Lighthizer, Richard Castillo, Joseph Shetler, Doug Penisten. CE hours: 32. For more information, email Callie McAtee at mcateec@nsuok.edu, call (918) 316-3602 or go to optometry.nsuok.edu/continuingeducation.

To list your meeting, please send the details to:

Michael Iannucci
Associate Editor
Email: miannucci@jobson.com
Phone: (610) 492-1043



There Will Be Blood

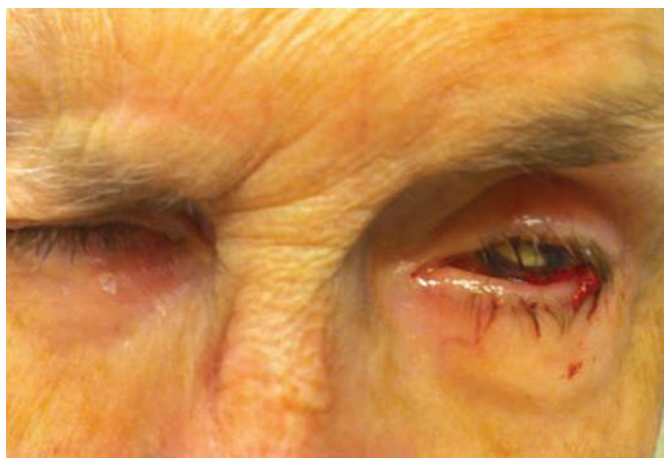
By Andrew S. Gurwood, OD

History

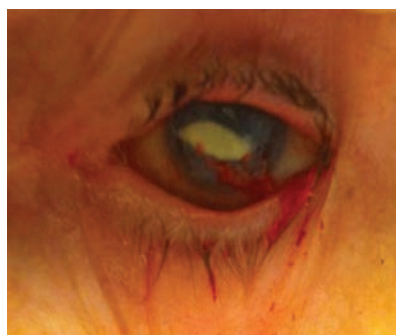
An 81-year-old Caucasian female reported to the office with a chief complaint of a red and painful left eye of two weeks duration. The patient had been to multiple eye doctors previously for herpes simplex virus (HSV) keratopathy and was treated for a non-healing epithelial defect with active HSV keratitis and subsequent elevated pressure in the left eye. Her ocular history was also remarkable for keratoconjunctivitis sicca in both eyes, for which she had been using artificial tears and erythromycin ointment in both eyes, and half-strength dose of fluorometholone drops in the right eye. The patient developed HSV keratitis about 30 years ago with multiple episodes of exacerbation and remission. Her systemic history was remarkable for herpes simplex virus treated with oral valacyclovir periodically during outbreaks. She denied any allergies.

Diagnostic Data

Her best-corrected visual acuities were 20/50 OD and 20/200 OS. Her external examination was grossly intact. The pertinent anterior segment findings in the left eye are demonstrated in the photo-



An 81-year-old with a history of herpes simplex keratopathy presented with a bleeding, painful left eye. What can these images and her history tell you about her likely diagnosis?



graphs. Biomicroscopy of the right eye showed evidence of anterior basement membrane dystrophy with old inactive corneal opacities. The anterior chamber of the right eye appeared to be deep and quiet with a well-placed posterior chamber intraocular lens. Goldmann intraocular pressures were

measured to be 18mm Hg OD and 20mm Hg OS. Dilated funduscopy was within normal limits, both eyes, revealing slightly high asymmetric cup-to-disc ratios measuring 0.5/0.5, 0.55/0.6, OD, OS respectively with normal peripheries.

Your Diagnosis

Does the case presented require any additional tests, history or information? What steps would you take to manage this patient? Based on the information provided, what would be your diagnosis? What is the patient's most likely prognosis? To find out, please visit us online at www.reviewofoptometry.com. ■

Retina Quiz Answers (from page 84): 1) c; 2) d; 3) c; 4) b; 5) b.

REVIEW OF OPTOMETRY (ISSN 0147-7633) IS PUBLISHED MONTHLY, 12 TIMES A YEAR BY JOBSON MEDICAL INFORMATION LLC, 440 9TH AVENUE, 14TH FLOOR, NEW YORK, NY 10013-1678. PERIODICALS POSTAGE PAID AT NEW YORK, NY AND ADDITIONAL MAILING OFFICES. POSTMASTER: SEND ADDRESS CHANGES TO REVIEW OF OPTOMETRY, PO BOX 81, CONGERS, NY 10920-0081. SUBSCRIPTION PRICES: US: ONE YEAR \$56; TWO YEARS \$97, CANADA: ONE YEAR \$88, TWO YEARS \$160, INT'L: ONE YEAR \$209, TWO YEARS \$299. FOR SUBSCRIPTION INFORMATION CALL TOLL-FREE (877) 529-1746 (USA); OUTSIDE USA, CALL (845) 267-3065. OREMAIL US AT REVOPPTOMETRY@CAMBEYWEST.COM. PUBLICATIONS MAIL AGREEMENT NO: 40612608. CANADA RETURNS TO BE SENT TO BLEUCHIP INTERNATIONAL, P.O. BOX 25542, LONDON, ON N6C 6B2.

Bausch + Lomb ULTRA® for Astigmatism PROVIDES ALL-DAY COMFORT, STABILITY, AND CONSISTENTLY CLEAR VISION¹

EXPANDED PARAMETERS
NOW AVAILABLE



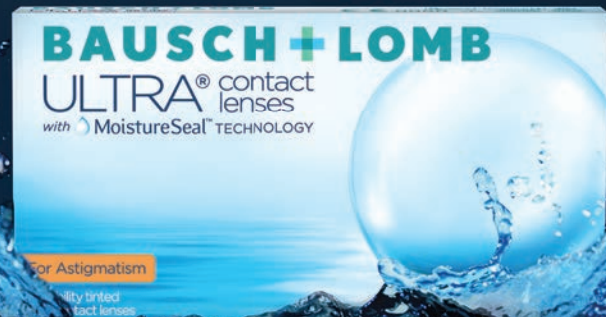
Helps maintain **95%**
of lens moisture for
a full 16 hours²

OPTICALIGN™ DESIGN

For stability to promote
a **successful first fit**¹



- ECPs reported **rotation** at dispensing of **5 degrees or less** for 94% of patients¹
- **Spherical aberration control** optimized in both axes helps **reduce halos and glare**^{1,2}



**PRESCRIBE BAUSCH + LOMB ULTRA®
FOR ASTIGMATISM**

REFERENCES: 1. Results from a 7-investigator, multi-site 2-week study of Bausch + Lomb ULTRA® for Astigmatism contact lenses on 157 current soft contact lens wearers. 2. Data on file. Bausch + Lomb Incorporated. Rochester, NY.

®/™ are trademarks of Bausch + Lomb Incorporated or its affiliates.
©2017 Bausch + Lomb Incorporated. UFA.0218.USA.17

BAUSCH + LOMB
See better. Live better.

GIVE YOUR PATIENTS OUTSTANDING COMFORT FROM DAY 1 TO DAY 30^{1-3*}



Excellent Deposit Protection^{4,5}



Lasting Lens Surface Moisture^{6,7}

AIR OPTIX[®]
plus
HydraGlyde[®]
contact lenses
Alcon A Novartis Division

FOR A LIMITED TIME, PATIENTS CAN
SAVE UP TO \$50

ON AN ANNUAL SUPPLY VIA MAIL-IN OR ONLINE REBATE**
WITH THE AIR OPTIX[®] CHOICE PROGRAM!

Visit AIROPTIXCHOICE.com to learn more

*Based on clinical studies with AIR OPTIX[®] AQUA contact lenses.

**Rebate in the form of an Alcon VISA[®] prepaid card. Must purchase an annual supply (four 6-ct boxes) of AIR OPTIX[®] brand contact lenses (excluding AIR OPTIX[®] AQUA [sphere] lenses). Rebate submission must be submitted electronically (or postmarked, if by mail) within sixty (60) days of purchase and no more than ninety (90) days after eye exam/lens fitting. Valid on purchases made through participating retailers through 4/30/2018. Additional restrictions apply. Visit AIROPTIXCHOICE.com for complete terms and conditions. Questions? Call 1-855-344-6871.

References: 1. Eiden SB, Davis R, Bergenske P. Prospective study of lotrafilcon B lenses comparing 2 versus 4 weeks of wear for objective and subjective measures of health, comfort, and vision. *Eye Contact Lens*. 2013;39(4):290-294. 2. Lemp J, Kern J. A comparison of real time and recall comfort assessments. *Optom Vis Sci*. 2016;93:E-abstract 165256. 3. Merchea M, Mathew J, Mack C. Assessing Satisfaction with Lotrafilcon B Packaged with an EOBO Wetting Agent Combined with EOBO-Based Lens Care Solutions. Poster presented at the Annual Meeting of the American Academy of Optometry, October 11-14, 2017, Chicago, IL. 4. Nash W, Gabriel M, Mowrey-McKee M. A comparison of various silicone hydrogel lenses; lipid and protein deposition as a result of daily wear. *Optom Vis Sci*. 2010;87:E-abstract 105110. 5. Nash WL, Gabriel MM. Ex vivo analysis of cholesterol deposition for commercially available silicone hydrogel contact lenses using a fluorometric enzymatic assay. *Eye Contact Lens*. 2014;40(5):277-282. 6. In vitro study over 16 hours to measure wetting substantivity. Alcon data on file, 2015. 7. Muya L, Lemp J, Kern JR, Sentell KB, Lane J, Perry SS. Impact of packaging saline wetting agents on wetting substantivity and lubricity. *Invest Ophthalmol Vis Sci* 2016;57:E-abstract 1463.

Important information for AIR OPTIX[®] plus HydraGlyde[®] (lotrafilcon B): For daily wear or extended wear up to 6 nights for near/farsightedness, presbyopia and/or astigmatism. Risk of serious eye problems (i.e. corneal ulcer) is greater for extended wear. In rare cases, loss of vision may result. Side effects like discomfort, mild burning or stinging may occur.



Recommend CLEAR CARE[®] PLUS
or OPTI-FREE[®] Puremoist[®]
as the perfect combination
with AIR OPTIX[®] lenses.

Alcon A Novartis Division

See product instructions for complete wear, care and safety information. © 2018 Novartis 03/18 US-AOH-18-E-0424