

RETINA[®] SPECIALIST

VOL. 9, NO. 4 • JULY/AUGUST 2023

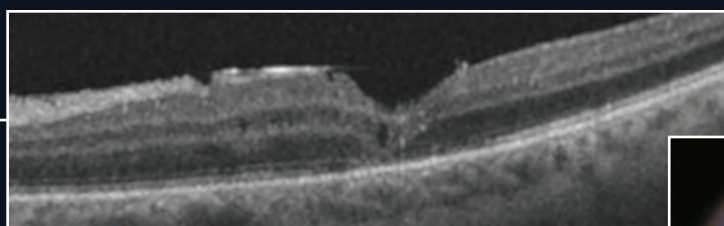
Retina Update: In the Lucentis biosimilars war, there are no winners **Page 9**

Page 11 **North of the Border: Window to neurodegenerative disease**

Innovations in Retinal Surgery

PRACTICAL APPLICATIONS OF INTRAOPERATIVE OCT

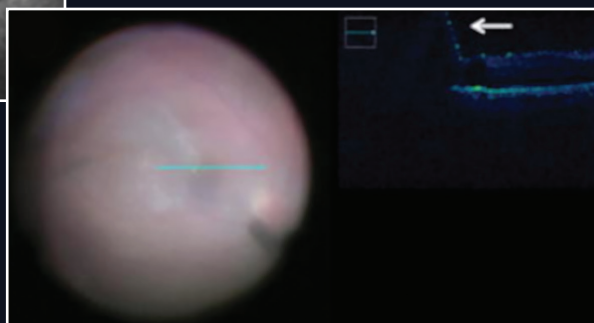
How it's used for multiple procedures as tech advances. **PAGE 18**



3D HEADS-UP VISUALIZATION:

Less pain, more gain. **PAGE 25**

WITH ONLINE VIDEO



Online Video

• Pearls for fovea-sparing ILM peeling – **Page 16**

Also Inside

- Reframing the discussion around GA – **Page 30**
- Conference Review: Surgical pearls from the Vit Buckle Society – **Page 34**

0.18 mg

YUTIQ®

(fluocinolone acetonide
intraocular implant) 0.18 mg

Discover continuous calm in uveitis¹

YUTIQ is designed to deliver a sustained release of fluocinolone for up to 36 months for patients with chronic non-infectious uveitis affecting the posterior segment of the eye¹


- **Proven to reduce uveitis recurrence at 6 and 12 months^{1,*}**
At 6 months—18% for YUTIQ and 79% for sham for Study 1 and 22% for YUTIQ and 54% for sham for Study 2 ($P < .01$). At 12 months—28% for YUTIQ and 86% for sham for Study 1 and 33% for YUTIQ and 60% for sham for Study 2.
- **Extended median time to first recurrence of uveitis^{1,2}**
At 12 months—NE[†] for YUTIQ/92 days for sham in Study 1;
NE for YUTIQ/187 days for sham in Study 2.
- **Mean intraocular pressure (IOP) increase was comparable to sham^{1,2}**
Study was not sized to detect statistically significant differences in mean IOP.

*Study design: The efficacy of YUTIQ was assessed in 2 randomized, multicenter, sham-controlled, double-masked, Phase 3 studies in adult patients (N=282) with non-infectious uveitis affecting the posterior segment of the eye. The primary endpoint in both studies was the proportion of patients who experienced recurrence of uveitis in the study eye within 6 months of follow-up; recurrence was also assessed at 12 months. Recurrence was defined as either deterioration in visual acuity, vitreous haze attributable to non-infectious uveitis, or the need for rescue medications.

[†]NE=non-evaluable due to the low number of recurrences in the YUTIQ group.

For more
information, visit

[YUTIQ.com](https://www.yutiq.com)



INDICATIONS AND USAGE

YUTIQ® (fluocinolone acetonide intraocular implant) 0.18 mg is indicated for the treatment of chronic non-infectious uveitis affecting the posterior segment of the eye.

IMPORTANT SAFETY INFORMATION

CONTRAINDICATIONS

Ocular or Periocular Infections: YUTIQ is contraindicated in patients with active or suspected ocular or periocular infections including most viral disease of the cornea and conjunctiva including active epithelial herpes simplex keratitis (dendritic keratitis), vaccinia, varicella, mycobacterial infections and fungal diseases.

Hypersensitivity: YUTIQ is contraindicated in patients with known hypersensitivity to any components of this product.

WARNINGS AND PRECAUTIONS

Intraocular Injection-related Effects: Intraocular injections, including those with YUTIQ, have been associated with endophthalmitis, eye inflammation, increased or decreased intraocular pressure, and choroidal or retinal detachments. Hypotony has been observed within 24 hours of injection and has resolved within 2 weeks. Patients should be monitored following the intraocular injection.

Steroid-related Effects: Use of corticosteroids including YUTIQ may produce posterior subcapsular cataracts, increased intraocular pressure and glaucoma. Use of corticosteroids may enhance the establishment of secondary ocular infections due to bacteria, fungi, or viruses. Corticosteroids are not recommended to be used in patients with a history of ocular herpes simplex because of the potential for reactivation of the viral infection.

Risk of Implant Migration: Patients in whom the posterior capsule of the lens is absent or has a tear are at risk of implant migration into the anterior chamber.

ADVERSE REACTIONS

In controlled studies, the most common adverse reactions reported were cataract development and increases in intraocular pressure.

Please see brief summary of full Prescribing Information on adjacent page.

References: 1. YUTIQ® (fluocinolone acetonide intraocular implant) 0.18 mg full US Prescribing Information. EyePoint Pharmaceuticals, Inc. February 2022. 2. Data on file.



YUTIQ, the YUTIQ logo, and the EyePoint logo are registered trademarks of EyePoint Pharmaceuticals, Inc.
©2023 EyePoint Pharmaceuticals, Inc. All rights reserved.
480 Pleasant Street, Suite B300, Watertown, MA 02472

02/2023
US-YUT-2300016

YUTIQ® (fluocinolone acetonide intravitreal implant) 0.18 mg, for intravitreal injection
Initial U.S. Approval: 1963

BRIEF SUMMARY: Please see package insert for full prescribing information.

1. INDICATIONS AND USAGE. YUTIQ® (fluocinolone acetonide intravitreal implant) 0.18 mg is indicated for the treatment of chronic non-infectious uveitis affecting the posterior segment of the eye.

4. CONTRAINDICATIONS. 4.1. Ocular or Periocular Infections. YUTIQ is contraindicated in patients with active or suspected ocular or periocular infections including most viral disease of the cornea and conjunctiva including active epithelial herpes simplex keratitis (dendritic keratitis), vaccinia, varicella, mycobacterial infections and fungal diseases. **4.2. Hypersensitivity.** YUTIQ is contraindicated in patients with known hypersensitivity to any components of this product.

5. WARNINGS AND PRECAUTIONS. 5.1. Intravitreal Injection-related Effects. Intravitreal injections, including those with YUTIQ, have been associated with endophthalmitis, eye inflammation, increased or decreased intraocular pressure, and choroidal or retinal detachments. Hypotony has been observed within 24 hours of injection and has resolved within 2 weeks. Patients should be monitored following the intravitreal injection [see Patient Counseling Information (17) in the full prescribing information]. **5.2. Steroid-related Effects.** Use of corticosteroids including YUTIQ may produce posterior subcapsular cataracts, increased intraocular pressure and glaucoma. Use of corticosteroids may enhance the establishment of secondary ocular infections due to bacteria, fungi, or viruses. Corticosteroids are not recommended to be used in patients with a history of ocular herpes simplex because of the potential for reactivation of the viral infection. **5.3. Risk of Implant Migration.** Patients in whom the posterior capsule of the lens is absent or has a tear are at risk of implant migration into the anterior chamber.

6. ADVERSE REACTIONS. 6.1. Clinical Studies Experience. Because clinical trials are conducted under widely varying conditions, adverse reaction rates observed in the clinical trials of a drug cannot be directly compared to rates in the clinical trials of another drug and may not reflect the rates observed in practice. Adverse reactions associated with ophthalmic steroids including YUTIQ include cataract formation and subsequent cataract surgery, elevated intraocular pressure, which may be associated with optic nerve damage, visual acuity and field defects, secondary ocular infection from pathogens including herpes simplex, and perforation of the globe where there is thinning of the cornea or sclera. Studies 1 and 2 were multicenter, randomized, sham injection-controlled, masked trials in which patients with non-infectious uveitis affecting the posterior segment of the eye were treated once with either YUTIQ or sham injection, and then received standard care for the duration of the study. Study 3 was a multicenter, randomized, masked trial in which patients with non-infectious uveitis affecting the posterior segment of the eye were all treated once with YUTIQ, administered by one of two different applicators, and then received standard care for the duration of the study. Table 1 summarizes data available from studies 1, 2 and 3 through 12 months for study eyes treated with YUTIQ (n=226) or sham injection (n=94). The most common ocular (study eye) and non-ocular adverse reactions are shown in Table 1 and Table 2.

Table 1: Ocular Adverse Reactions Reported in ≥ 1% of Subject Eyes and Non-Ocular Adverse Reactions Reported in ≥ 2% of Patients

Ocular		
ADVERSE REACTIONS	YUTIQ (N=226 Eyes) n (%)	Sham Injection (N=94 Eyes) n (%)
Cataract ¹	63/113 (56%)	13/56 (23%)
Visual Acuity Reduced	33 (15%)	11 (12%)
Macular Edema	25 (11%)	33 (35%)
Uveitis	22 (10%)	33 (35%)
Conjunctival Hemorrhage	17 (8%)	5 (5%)
Eye Pain	17 (8%)	12 (13%)
Hypotony Of Eye	16 (7%)	1 (1%)
Anterior Chamber Inflammation	12 (5%)	6 (6%)
Dry Eye	10 (4%)	3 (3%)
Vitreous Opacities	9 (4%)	8 (9%)
Conjunctivitis	9 (4%)	5 (5%)
Posterior Capsule Opacification	8 (4%)	3 (3%)
Ocular Hyperemia	8 (4%)	7 (7%)
Vitreous Haze	7 (3%)	4 (4%)
Foreign Body Sensation In Eyes	7 (3%)	2 (2%)
Vitritis	6 (3%)	8 (9%)
Vitreous Floaters	6 (3%)	5 (5%)
Eye Pruritus	6 (3%)	5 (5%)
Conjunctival Hyperemia	5 (2%)	2 (2%)
Ocular Discomfort	5 (2%)	1 (1%)
Macular Fibrosis	5 (2%)	2 (2%)
Glaucoma	4 (2%)	1 (1%)
Photopsia	4 (2%)	2 (2%)

(continued)

Table 1: Ocular Adverse Reactions Reported in ≥ 1% of Subject Eyes and Non-Ocular Adverse Reactions Reported in ≥ 2% of Patients

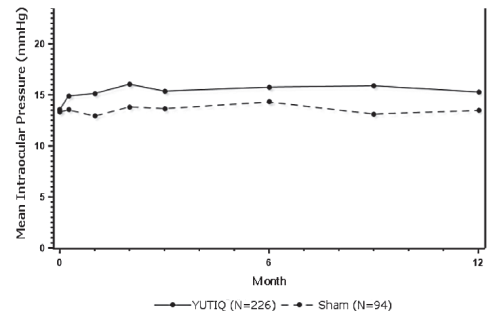
Ocular		
ADVERSE REACTIONS	YUTIQ (N=226 Eyes) n (%)	Sham Injection (N=94 Eyes) n (%)
Vitreous Hemorrhage	4 (2%)	0
Iridocyclitis	3 (1%)	7 (7%)
Eye Inflammation	3 (1%)	2 (2%)
Choroiditis	3 (1%)	1 (1%)
Eye Irritation	3 (1%)	1 (1%)
Visual Field Defect	3 (1%)	0
Lacrimation Increased	3 (1%)	0
Non-ocular		
ADVERSE REACTIONS	YUTIQ (N=214 Patients) n (%)	Sham Injection (N=94 Patients) n (%)
Nasopharyngitis	10 (5%)	5 (5%)
Hypertension	6 (3%)	1 (1%)
Arthralgia	5 (2%)	1 (1%)

1. Includes cataract, cataract subcapsular and lenticular opacities in study eyes that were phakic at baseline. 113 of the 226 YUTIQ study eyes were phakic at baseline; 56 of 94 sham-controlled study eyes were phakic at baseline.

Table 2: Summary of Elevated IOP Related Adverse Reactions

ADVERSE REACTIONS	YUTIQ (N=226 Eyes) n (%)	Sham (N=94 Eyes) n (%)
IOP elevation ≥ 10 mmHg from Baseline	50 (22%)	11 (12%)
IOP elevation > 30 mmHg	28 (12%)	3 (3%)
Any IOP-lowering medication	98 (43%)	39 (41%)
Any surgical intervention for elevated IOP	5 (2%)	2 (2%)

Figure 1: Mean IOP During the Studies



8. USE IN SPECIFIC POPULATIONS. 8.1 Pregnancy. Risk Summary. Adequate and well-controlled studies with YUTIQ have not been conducted in pregnant women to inform drug associated risk. Animal reproduction studies have not been conducted with YUTIQ. It is not known whether YUTIQ can cause fetal harm when administered to a pregnant woman or can affect reproduction capacity. Corticosteroids have been shown to be teratogenic in laboratory animals when administered systemically at relatively low dosage levels. YUTIQ should be given to a pregnant woman only if the potential benefit justifies the potential risk to the fetus. All pregnancies have a risk of birth defect, loss, or other adverse outcomes. In the United States general population, the estimated background risk of major birth defects and miscarriage in clinically recognized pregnancies is 2% to 4% and 15% to 20%, respectively. **8.2 Lactation. Risk Summary.** Systemically administered corticosteroids are present in human milk and can suppress growth, interfere with endogenous corticosteroid production. Clinical or nonclinical lactation studies have not been conducted with YUTIQ. It is not known whether intravitreal treatment with YUTIQ could result in sufficient systemic absorption to produce detectable quantities of fluocinolone acetonide in human milk, or affect breastfed infants or milk production. The developmental and health benefits of breastfeeding should be considered, along with the mother's clinical need for YUTIQ and any potential adverse effects on the breastfed child from YUTIQ. **8.4 Pediatric Use.** Safety and effectiveness of YUTIQ in pediatric patients have not been established. **8.5 Geriatric Use.** No overall differences in safety or effectiveness have been observed between elderly and younger patients.

Manufactured by:
EyePoint Pharmaceuticals US, Inc., 480 Pleasant Street, Watertown, MA 02472 USA
Patented. See <https://eyepointpharma.com/patent-notification/>

EDITORIAL STAFF

EDITOR-IN-CHIEF

Walter Bethke
wbethke@jobson.com

CHIEF MEDICAL EDITOR

Charles C. Wykoff, MD, PhD
ccwmd@houstonretina.com

EDITOR

Richard Mark Kirkner
rkirkner@jobson.com

SENIOR ART DIRECTOR

Jared Araujo
jaraujo@jhihealth.com

GRAPHIC DESIGNER

Lynne O'Connor
lyoconnor@jobson.com

AD PRODUCTION MANAGER

Karen Lallone
klallone@jhihealth.com

EDITORIAL BOARD

Ashkan M. Abbey, MD, Dallas
David R.P. Almeida, MD, PhD, MBA, Erie, Pa.
Caroline R. Bauman, MD, Boston
Lisa Olmos de Koo, MD, MBA, Seattle
Justis P. Ehlers, MD, Cleveland
Tina Felfeli, MD, Toronto
Avni P. Finn, MD, MBA, San Jose, Calif.
Mrinali Gupta, MD, Newport Beach, Calif.
Paul Hahn, MD, PhD, Teaneck, N.J.
Jason Hsu, MD, Philadelphia
Amir Kashani, MD, Baltimore
Efrem D. Mandelcorn, MD, FRCS, Toronto
Jonathan L. Prenner, MD, Edison, N.J.
Carl D. Regillo, MD, FACS, Philadelphia
Phillip J. Rosenfeld, MD, PhD, Miami
Jayanth Sridhar, MD, Miami
Akshay S. Thomas, MD, MS, Nashville, Tenn.

EDITORIAL CONTRIBUTORS

Amer F. Alsoufi, MD, Houston
Michael Balas, Toronto
Hong-Uyen Hua, MD, Cleveland
Rabia Karani, MD, MPH, Baltimore
Amir H. Kashani, MD, PhD, Baltimore
Eleanora Lad, MD, PhD, Durham, N.C.
Thomas Lazzarini, MD, Miami
K. Matthew McKay, MD, Seattle
Suzanne Michalak, MD, Palo Alto, Calif.
Ehsan Rahimy, MD, Palo Alto, Calif.
Margaret M. Runner, MD, Royal Oak, Mich.
Laura Selby, MD, Seattle
Abtin Shahlaee, MD, Philadelphia
Henry C. Skrehot, MD, Houston
Masaki Suzue, MD, Osaka, Japan
Lejla Vajzovic, MD, Durham, N.C.
Nita Valikodath, MD, MS, Durham, N.C.
Taku Wakabayashi, MD, Philadelphia



Jobson Medical Information



Breaking down silos

Surgical vs. medical retina. The separation used to be clear. Surgery dealt with anatomic pathologies including retinal detachments and epiretinal membranes. Medical approaches were applied for age-related macular degeneration, diabetic macular edema, etc.

Fortunately for the field and, most importantly, for our patients, promising development programs are blurring the line between our two historical silos.

Late last year, two global, randomized, sham-controlled Phase III trials enrolling 224 patients with macular telangiectasia type 2 found the NT-501 implant (Neurotech Pharmaceuticals) significantly reduced photoreceptor loss at month 24 by up to 66 percent. NT-501 uses encapsulated cell technology (ECT) to house human retinal pigment epithelial cells genetically modified to produce ciliary neurotrophic factor (CNTF), a diffusible neuroprotective cytokine normally produced by Muller glial cells.


The device is surgically implanted into the vitreous through a 3-mm incision, anchored to the sclera. It has been shown to produce medication for more than 10 years. Its tiny pores allow nutrients and oxygen in and CNTF out, but prevent cellular migration out and block immune cell migration in. Emily Chew, MD, will be presenting the Phase III data at the American Society of Retina Specialists' 41st annual scientific meeting in July. Regulatory engagement is also underway.


Another device, the Port Delivery System (Susvimo, Genentech/Roche), a surgically implanted reservoir that releases ranibizumab into the vitreous

cavity over many months, has demonstrated impressive efficacy and durability in trials for neovascular AMD, DME and diabetic retinopathy. While it has been voluntarily recalled from the market, there is hope that the system may return commercially with some modifications.


On the flip-side, medical adjuncts are being investigated that may be able to improve outcomes for traditionally surgical diseases. For example, in the Phase III GUARD trial, a series of 12 intravitreal injections of the antimetabolite methotrexate demonstrated encouraging results in the management of retinal detachments complicated by proliferative vitreoretinopathy.

And ONL1204 (ONL Therapeutics), a peptide inhibitor of fas apoptosis signaling, is the subject of an ongoing sham-controlled Phase II trial of patients with macula-off rhegmatogenous RD. Fas inhibition can prevent cell death and may minimize damaging inflammatory cascades within the neurosensory retina driven by oxygen and nutrient deprivation during detachment and reperfusion injury upon reattachment.

In this spirit, our current edition is dedicated to surgical innovation as well as the surgeons and companies leading these important developments. As addressed directly by the decorated Navy SEAL and leadership author Jocko Willink, we will continue to "break down silos," between medical and surgical retina, one pathology at a time. 



OCULUS HD Disposable LenZ – For single-use on the ZEISS RESIGHT®



- **Perfect view in every case**
Single-use means no scratches or opacities
- **Always sterile**
Minimizes risk of infection and cross-contamination
- **Always available on the spot**
Increase your O.R. capacity utilization

Please note: The availability of the products and features may differ in your country. Specifications and design are subject to change. Please contact your local distributor for details.

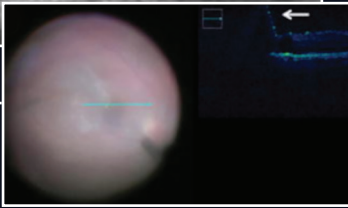
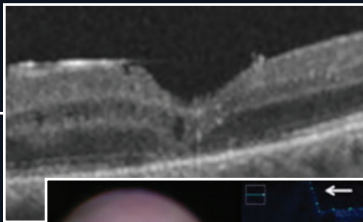


www.oculussurgical.com +49 641 2005-298 855-SDI-BIOM (Toll Free, US Only)

 OCULUS®
SURGICAL

A PUBLICATION BY **REVIEW**
OF OPHTHALMOLOGY**RETINA**
SPECIALIST

JULY/AUGUST 2023 • VOL. 9, NO. 4

FEATURES*Innovations in Retina Surgery***18**
**Practical applications
of intraoperative OCT**

A review of how it has been used for multiple retinal procedures, with more coming as technology advances.

By Rabia Karani, MD, MPH, and
Amir H. Kashani, MD, PhD

25
3D, heads-up visualization: Less pain, more gainONLINE
VIDEO

Three-dimensional heads-up display can enhance surgical visualization, training, ergonomics and potentially surgical outcomes.

By Nita Valikodath, MD, MS, and Lejla Vajzovic MD

30
Reframing the discussion around geographic atrophy

Understanding the natural disease progression of GA will help us talk to our patients about new and emerging treatments.

By Amer F. Alsoudi, MD, Henry C. Skrehot, MD, and Ehsan Rahimy, MD

34
Surgical pearls from the Vit Buckle Society

Tips for pediatric and diabetic surgery, and foreign body removal, along with novel approaches for chronic macular holes and visualization in endophthalmitis.

Edited by Yoshihiro Yonekawa, MD

DEPARTMENTS**4** **Editor's Page**

Breaking down silos

By Charles C. Wykoff, MD, PhD

9 **Retina Update**

In the Lucentis biosimilars war, there are no winners so far

11 **North of the Border**

The window to neurodegenerative diseases

Edited by Efreem Mandelcorn, MD, FRCSC

13 **Retina Rounds**

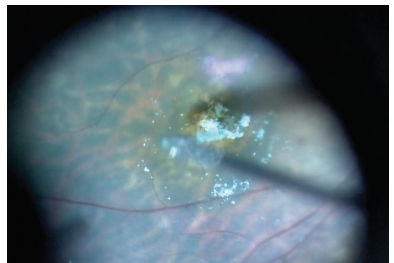
The patient with the puzzling plaques

Edited by Lisa C. Olmos deKoo, MD, MBA

16 **Surgical Pearl Video**

Pearls for fovea-sparing ILM peeling

Edited by Tina Felfeli, MD

ONLINE
VIDEO**39** **Clinical Trial Closeup**

Potential of low-light therapy for dry AMD

Edited by Richard Mark Kirkner

Unique J-Code J-2403 Helps Facilitate Reimbursement

IHEEZO™
(chloroprocaine HCl ophthalmic gel) 3%

IHEEZO Gives You Nothing



Visit [IHEEZO.com](https://www.iheezo.com) to learn more.

IHEEZO™ is the topical ocular anesthetic that compromises on nothing. Rapid onset and an established safety profile for your patients. No uncertainty with a sterile, single-use unit for you.

In a Phase III clinical study of IHEEZO,

NO supplemental treatment
needed to maintain
anesthesia*¹

NO serious adverse events
with an established
safety profile²

NO patients reported
experiencing pain²

*In the clinical trial, no patient undergoing routine cataract surgery receiving IHEEZO required supplemental treatment to maintain anesthesia; this was not the case for patients receiving tetracaine. Supplemental treatment was defined as general anesthesia, intraoperative systemic analgesia, or local anesthesia. Though supplemental administration was not required by any patient in the clinical trial, IHEEZO may be reapplied as needed to maintain anesthesia.^{1,2}

²Sufficient anesthesia with IHEEZO lasted an average of 21.5 minutes in the clinical trial, while mean total surgical time was 13.9 minutes.²

APPROVED USE

IHEEZO is indicated for ocular surface anesthesia.

IMPORTANT SAFETY INFORMATION

IHEEZO is contraindicated in patients with a history of hypersensitivity to any component of this preparation.

IHEEZO should not be injected or intraocularly administered.

Patients should not touch the eye for at least 10 to 20 minutes after using anesthetic as accidental injuries can occur due to insensitivity of the eye.

Prolonged use of a topical ocular anesthetic may produce permanent corneal opacification and ulceration with accompanying visual loss.

Do not touch the dropper tip to any surface as this may contaminate the gel.

IHEEZO is indicated for administration under the direct supervision of a healthcare provider. IHEEZO is not intended for patient self-administration.

The most common adverse reactions in studies following IHEEZO administration (incidence greater than or equal to 5%) were mydriasis, conjunctival hyperemia, and eye irritation.

You are encouraged to report suspected adverse reactions to the FDA. Visit www.fda.gov/medwatch, or call 1-800-FDA-1088.

Please see Brief Summary of Full Prescribing Information for IHEEZO on adjacent page.

References: 1. Iheezo. Prescribing information. Harrow IP, LLC; 2022. 2. Data on File. Harrow IP, LLC; 2023.



HARROW®

Your patients. Our purpose.

Harrow and IHEEZO are trademarks of Harrow IP, LLC.

©2023 Harrow. All rights reserved.

IZO-00095 06/23

IHEEZO™

(chloroprocaine HCl ophthalmic gel) 3%

BRIEF SUMMARY OF PRESCRIBING INFORMATION

1 INDICATIONS AND USAGE

IHEEZO™ (chloroprocaine hydrochloride ophthalmic gel) 3% is a preservative-free ester anesthetic indicated for ocular surface anesthesia.

4 CONTRAINDICATIONS

IHEEZO is contraindicated in patients with a history of hypersensitivity to any component of this preparation.

5 WARNINGS AND PRECAUTIONS

5.1 Not for Injection or Intraocular Administration

IHEEZO should not be injected or intraocularly administered.

5.2 Corneal Injury Due to Insensitivity

Patients should not touch the eye for at least 10 to 20 minutes after using anesthetic as accidental injuries can occur due to insensitivity of the eye.

5.3 Corneal Opacification

Prolonged use of a topical ocular anesthetic may produce permanent corneal opacification and ulceration with accompanying visual loss.

5.4 Risk of Contamination

Do not touch the dropper tip to any surface as this may contaminate the gel.

5.5 For Administration by Healthcare Provider

IHEEZO is indicated for administration under the direct supervision of a healthcare provider. IHEEZO is not intended for patient self-administration.

6 ADVERSE REACTIONS

6.1 Clinical Trials Experience

Because clinical trials are conducted under widely varying conditions, adverse reaction rates observed in the clinical trials of a drug cannot be directly compared to rates in the clinical trials of another drug and may not reflect the rates observed in practice.

The data described below reflect 201 patients undergoing various surgical ocular procedures in two placebo-controlled trials (Study 1 and Study 2). Patients in Study 1 were randomized to receive a single instillation of 3 drops of IHEEZO or placebo. Patients in Study 2 were randomized to receive a single or multiple instillations of 1, 3, or 3+3 drops of IHEEZO or placebo.

The most common adverse reactions in these studies (incidence greater than or equal to 5%) following IHEEZO administration were mydriasis, conjunctival hyperemia, and eye irritation.

8 USE IN SPECIFIC POPULATIONS

8.1 Pregnancy

Risk Summary

There are no adequate and well-controlled studies of IHEEZO use in pregnant women to inform a drug-associated risk. There are no animal reproduction studies for chloroprocaine.

8.2 Lactation

Risk Summary

There are no data on the presence of chloroprocaine in human milk, the effects on the breastfed infant, or the effects on milk production. The developmental and health benefits of breastfeeding should be considered along with the mother's clinical need for IHEEZO and any potential adverse effects on the breastfed infant from IHEEZO.

8.4 Pediatric Use

The safety and effectiveness of IHEEZO have not been established in pediatric patients.

8.5 Geriatric Use

No overall differences in safety or effectiveness of IHEEZO have been observed between elderly and younger patients.

12 CLINICAL PHARMACOLOGY

12.1 Mechanism of Action

Chloroprocaine, like other local anesthetics, blocks the generation and the conduction of nerve impulses, presumably by increasing the threshold for electrical excitation in the nerve, slowing the propagation of the nerve impulse, and reducing the rate of rise of the action potential. In general, the progression of anesthesia is related to the diameter, myelination, and conduction velocity of affected nerve fibers. Clinically, the order of loss of nerve function is as follows: (1) pain, (2) temperature, (3) touch, (4) proprioception, and (5) skeletal muscle tone.

12.3 Pharmacokinetics

The systemic exposure to chloroprocaine following topical ocular administration of IHEEZO has not been studied.

Elimination

Metabolism

Chloroprocaine is metabolized by plasma pseudocholinesterases and nonspecific esterases in ocular tissues. Chloroprocaine is rapidly metabolized in plasma by hydrolysis of the ester

linkage by pseudocholinesterase. The hydrolysis of chloroprocaine results in the production of β -diethylaminoethanol and 2-chloro-4-aminobenzoic acid, which inhibits the action of the sulfonamides.

Excretion

Chloroprocaine plasma half-life in vitro is approximately 25 seconds in adults and approximately 43 seconds in neonates. The kidney is the main excretory organ for most local anesthetics and their metabolites. Urinary excretion is affected by urinary perfusion and factors affecting urinary pH.

13 NONCLINICAL TOXICOLOGY

13.1 Carcinogenesis, Mutagenesis, Impairment of Fertility

Carcinogenesis

Long-term studies in animals to evaluate carcinogenic potential of chloroprocaine have not been conducted.

Mutagenesis

2-chloroprocaine and the main metabolite, ACBA, were negative in the in vitro bacterial reverse mutation test (Ames assay) and the in vitro chromosome aberrations assay.

Impairment of Fertility

Studies in animals to evaluate the impairment of fertility have not been conducted with chloroprocaine.

14 CLINICAL STUDIES

14.1 Study 1 and Study 2

Study 1 (NCT04779606) and Study 2 (NCT04753710) were randomized, double-blinded, placebo-controlled studies conducted to evaluate the efficacy, safety, and local tolerability of IHEEZO in 145 healthy volunteers.

In Study 1, 85 healthy males and females were randomized in a 4:1 ratio to receive a single ocular instillation of IHEEZO (n=68) or placebo (n=17). The double-blinded treatment included an IHEEZO or a placebo dose of 3 drops instilled at 1-minute (\pm 15 seconds) intervals in the right eye of each volunteer. The median age was 39 years (range 19 to 55 years); 59% female and 41% male.

In Study 2, 60 healthy males and females were randomized (40:20) to receive single or multiple ocular instillations of an IHEEZO dose of 3 drops in the right eye. The median age was 25 years (range 18 to 59 years); 54% female and 46% male.

The efficacy in Study 1 and Study 2 was determined by proportion of patients achieving full conjunctival anesthesia evaluated by conjunctival pinching 5 minutes after administration.

Efficacy results of Study 1

The proportion of subjects with successful anesthesia was 90% in the IHEEZO group and 12% in the placebo group ($P<0.01$). The median time for the IHEEZO group achieving anesthesia was 0.67 minutes. The median duration of anesthesia was 14.3 minutes.

Efficacy results of Study 2

The proportion of subjects with successful anesthesia was 95% in the IHEEZO group and 20% in the placebo group ($P<0.01$). The median time for the IHEEZO group achieving anesthesia was 0.67 minutes. The median duration of anesthesia was 19.3 minutes.

14.2 Study 3

Study 3 (NCT04685538) was a randomized, prospective, multicenter, active-controlled, observer-masked study conducted to evaluate the efficacy and safety of IHEEZO (n=166) versus tetracaine ophthalmic solution 0.5% (n=172) in patients undergoing cataract surgery.

The primary endpoint was defined as the proportion of patients in each treatment group gaining successful anesthesia without any supplementation. On average, patients needed 1 to 1.5 minutes to obtain sufficient anesthesia to successfully perform the surgical procedure, which lasted on average 22 minutes.

No patient treated with IHEEZO required supplemental treatment to complete the intended surgical procedure.

17 PATIENT COUNSELING INFORMATION

Eye Care Precaution

Do not touch the dropper tip to any surface as this may contaminate the gel. Advise patients that their eyes will be insensitive for up to 20 minutes due to the effect of the anesthetic, and that care should be taken to avoid accidental injuries.

For Full Prescribing Information, please visit www.iheezo.com/prescribinginformation.



Distributed by

Harrow Eye, LLC
102 Woodmont Blvd., Suite 610
Nashville, TN 37205
USA

In the Lucentis biosimilars wars, there are no winners so far

After almost a year since their launch, the two Food and Drug Administration-approved ranibizumab biosimilars are finding slow uptake by retina specialists and, according to an analyst who tracks retina drugs, market forces portend little boost going forward.

In the latest edition of its report on ophthalmology biosimilars, the life sciences consultancy Spherix Global Insights (SGI), found that retina specialists' and general ophthalmologists' attitudes toward biosimilars have actually soured over the past two years.

Biogen in July 2022 launched Byooviz, the first biosimilar referencing

Lucentis (ranibizumab, Genentech/Roche), after the FDA approved it the previous year, pricing it at \$1,130 for a single-use 0.5-mg vial (compared to \$1,850 for Lucentis), as *Retina Specialist* previously reported. A month later, the FDA approved Coherus BioSciences' Cimerli as the first interchangeable Lucentis biosimilar. Coherus launched Cimerli almost instantaneously. Drugs.com quotes Cimerli at \$869 a dose.

Interchangeability is a big deal with biosimilars. It means the biosimilar can be used for all indications for which the reference drug is approved. Cimerli is approved for both neovascular age-related macular degeneration and diabetic macular edema. Byooviz is approved only for nAMD.

Price doesn't matter

Price doesn't seem to be the mitigating factor in market sluggishness, Chrystal Ferguson, ophthalmology franchise head for SGI, tells *Retina Specialist*. Rather, it's more about the declining market position of Lucentis as aflibercept (Eylea, Regeneron Pharmaceuticals) maintains its dominant position and as faricimab (Vabysmo, Genentech/Roche) gains ground.

SGI bases its latest report on a survey of 79 physicians—62 retina specialists and 17 general ophthalmologists who regularly use anti-VEGF medications—done in late May. The company did previous surveys in December 2021 and 2022.

“Ophthalmologists are learning more about biosimilars, they're understanding the space a bit more, and as they do the concept of interchangeability is not something that they're wildly comfortable with,” Ms. Ferguson says. But interchangeability doesn't mean as much for an in-office-administered drug in ophthalmology as it does in, say, rheumatology where patients take their pills at home.

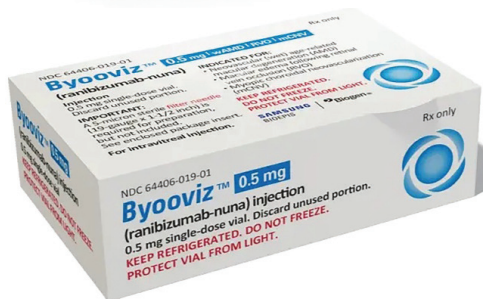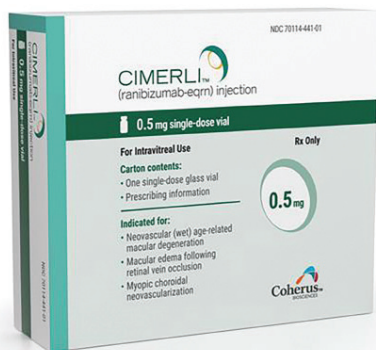According to SGI's data, Eylea holds a 43.4 percent market share, with Avastin (bevacizumab, Genentech/Roche) at 34 percent, Lucentis at 9.4 percent and Vabysmo at 7.6 percent filling out the market.

Four factors influencing market

Other factors are impacting biosimilar uptake in retina Ms. Ferguson says. They include:

- **Lucentis' declining market share.** “I think as ophthalmologists become more educated and aware and understand the space more, they are becoming a little bit more skeptical about what interchangeability means, but on top of that there's not a huge added benefit for them or their patients because they're not using ranibizumab all that readily to begin with,” she says.

- **Meager financial incentives for patients, doctors.** Payers typically are the primary driver behind biosimilars because they cost less than the reference product, Ms. Ferguson says. “However, when we ask [ophthalmologists] who benefits from those financial incentives, the reporting is commercial insurers, Medicare, the overall healthcare system, but savings to the patient and to the practice are



A year after launch of these ranibizumab biosimilars, ophthalmologists have been reluctant to embrace them.

RETINA SPECIALIST

BUSINESS OFFICES

19 CAMPUS BOULEVARD, SUITE 101
NEWTOWN SQUARE, PA 19073
SUBSCRIPTION INQUIRIES (877) 529-1746
(USA ONLY); OUTSIDE USA, CALL (847) 763-9630

BUSINESS STAFF

PUBLISHER

MICHAEL HOSTER

(610) 492-1028 MHOSTER@JOBSON.COM

SENIOR MANAGER, STRATEGIC ACCOUNTS

MICHELE BARRETT

(610) 492-1014 MBARRETT@JOBSON.COM

REGIONAL SALES MANAGER

JONATHAN DARDINE

(610) 492-1030 JDARDINE@JOBSON.COM

CLASSIFIED ADVERTISING

(888)-498-1460

PRODUCTION MANAGER

KAREN LALLONE

(610) 492-1010 KLALLONE@JOBSON.COM

SUBSCRIPTIONS

US ONE YEAR: \$63.00

CANADIAN ONE YEAR: \$99.00

FOREIGN ONE YEAR: \$158.00

SUBSCRIPTIONS E-MAIL:

SUBSCRIPTIONS@MDEDGE.COM

CIRCULATION

RETINA SPECIALIST

10255 W HIGGINS ROAD, SUITE 280

ROSEMONT, IL 60018.

DIRECTOR, CIRCULATION

JARED SONNERS

JSONNERS@MDEDGE.COM

CEO, INFORMATION GROUP SERVICES

BILL SCOTT

SENIOR VICE PRESIDENT, OPERATIONS

JEFF LEVITZ

VICE PRESIDENT, HUMAN RESOURCES

TAMMY GARCIA

VICE PRESIDENT, CREATIVE SERVICES & PRODUCTION

MONICA TETTAMANZI

SENIOR CORPORATE PRODUCTION DIRECTOR

JOHN ANTHONY CAGGIANO

DIRECTOR, CIRCULATION

JARED SONNERS



Jobson Medical Information LLC,

395 Hudson Street, 3rd Floor, New York, NY 10014

negligible or modest at best.”

• **The Avastin factor.** Avastin makes the biosimilar landscape in retina unique from other specialties. None have a reimbursable, off-label first-line therapy priced far below biosimilars. Retina specialists feel comfortable with Avastin and it has a proven safety profile, Ms. Ferguson says, although the efficacy doesn't meet that of ranibizumab or aflibercept. “They can start these patients on treatment right away rather than jump through hoops to get them on a ranibizumab biosimilar, and the price just can't be beat,” she says. A dose of Avastin costs \$67.86, according to the 2022 Medicare fee schedule.

• **The buy-and-bill factor.** Intravitreal biosimilars require the physician to purchase the drug, store it and then bill for reimbursement when they administer it, a process known as buy and bill. This applies to new products until they establish a reimbursement pathway, Ms. Ferguson says. That hasn't happened yet for Byooviz and Cimerli, she adds. “Physicians are reluctant to gamble their own money on the reimbursement,” she says. “That's what we're dealing with here in the ophthalmology space because they don't even know up front if they're going to get reimbursed for this.”

Meanwhile, Eylea biosimilars

Meanwhile, at least eight aflibercept biosimilars are in the pipeline, but they have a larger piece of the market to compete in.

However, Regeneron has developed a high-dose aflibercept 8 mg (Eylea is 2 mg), for which the FDA last month issued a complete response letter (CRL) raising issues with inspection findings at a third-party filler.

The FDA has set a target action date of July 27, 2023, and it isn't clear how the CRL will impact that. Regeneron also recently reported positive 24-month results of 12- and 16-week dosing regimens with the high-dose aflibercept.

Ms. Ferguson calls the high-dose aflibercept “the next-generation Eylea.” She adds, “I think the idea is to take their 2-mg patients and move them over to 8 mg before the biosimilars actually get there.” Those who stay on 2-mg therapy will have a biosimilar option.

Meanwhile, Vabysmo is picking up market share, Ms. Ferguson says, which is another factor that could further depress the market for Lucentis and its biosimilars.

The SIG report is available at www.spherixglobalinsights.com.

— Richard Mark Kirkner

IN BRIEF

Ocular Therapeutix reported topline 12-month data from its Phase I trial of OTX-TKI, a biore-sorbable hydrogel intravitreal implant delivering the tyrosine kinase inhibitor (TKI) axitinib for the treatment of age-related macular degeneration. The treatment group had an 89-percent reduction in treatment burden compared with the intravitreal aflibercept arm receiving treatments every eight weeks.

The company **iHealthScreen** has submitted a 510(k) medical device application to the Food

and Drug Administration for the **iPredict System**, what it calls the first artificial intelligence-based software for the early diagnosis of AMD.

The first patient has been dosed in a Phase I trial of **AIV007**, a broad-spectrum TKI, for the treatment of neovascular AMD and diabetic macular edema, the sponsoring company, **AiViva Biopharma**, reports. The trial will enroll up to 24 patients who will receive a single periocular injection, and evaluate outcomes over six months.

The window to neurodegenerative diseases

A look into the challenges and prospects of retinal imaging to identify biomarkers for Alzheimer's, Parkinson's and MS.

The eye, often referred to as a window to the soul, has become increasingly recognized as a window into the brain and its health. In this context, retinal imaging is emerging as a powerful tool to study the early signs of neurodegenerative diseases.

Probing into this frontier has the potential to reshape our understanding and potentially enhance the early detection and monitoring of disorders such as Alzheimer's disease, Parkinson's disease and multiple sclerosis.

The retina mirrors pathological processes in the central nervous system, presenting an opportunity for noninvasive imaging of neuronal and vascular structures. With advanced imaging techniques such as optical coherence tomography and OCT angiography, researchers have been able to detect early signs of neurodegenerative diseases.

A revolution for early intervention

Early detection of neurodegenerative diseases through retinal imaging could revolutionize the way we approach these conditions. Early intervention strategies can be designed based on retinal findings, potentially slowing the progression of these diseases and improving patients' quality of life.

Technological innovations and collaborations across different disciplines are propelling the research in retinal imaging. With the integration of advancements such as machine learning algorithms for image analysis and more sophisticated imaging techniques, retinal imaging holds promise for providing even deeper insights into neurodegenerative diseases.

Despite the promise of retinal imaging, challenges exist for its use to diagnose neurodegenerative diseases. They include developing standardized protocols, understanding the complexity of retinal changes and establishing specificity of retinal changes for each disease. Moreover, ethical considerations surround early diagnosis and its potential psychological impact on patients.

Alzheimer's disease

As the most common cause of dementia, Alzheimer's disease presents a formidable challenge to clinicians and researchers alike due to its insidious onset, progressive course and absence of definitive diagnostic tests in

By *Michael Balas, Tina Felfeli, MD, and Efrem Mandelcorn, MD, FRCSC*



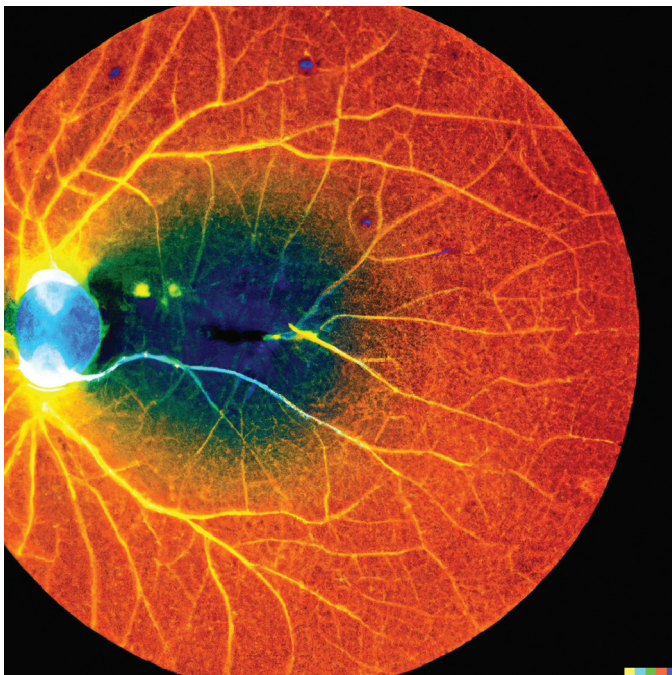
Michael Balas



Tina Felfeli, MD



Efrem D. Mandelcorn, MD, FRCSC



An OpenAI.DALL.E generated image based on the role of retinal imaging as a biomarker for neurodegenerative diseases.

BIOS

Mr. Balas is a medical student at the University of Toronto.

Dr. Felfeli is an ophthalmology resident at the University of Toronto.

Dr. Mandelcorn is an associate professor of ophthalmology at the University of Toronto.

DISCLOSURES: The authors have no relevant financial disclosures.

Retinal changes observed with OCT have been correlated with MRI measures of brain atrophy and clinical disability in MS patients, bolstering the case for retinal imaging as a noninvasive surrogate for neurodegeneration in MS.

the early stages. The disease is characterized pathologically by the accumulation of amyloid-beta plaques and neurofibrillary tangles in the brain. Intriguingly, these pathological hallmarks have been identified in the retinas of Alzheimer's patients, making retinal imaging a potential noninvasive avenue for early detection.^{1,2}

Retinal amyloid imaging can potentially detect Alzheimer's disease before the onset of significant cognitive symptoms, enabling earlier intervention and monitoring.³ OCTA has revealed significant vascular alterations in the retinas of Alzheimer's patients, further supporting the role of retinal imaging in early Alzheimer's detection.⁴

Parkinson's disease

Parkinson's disease, a progressive neurodegenerative disorder primarily affecting the motor system, presents unique challenges for early diagnosis and monitoring due to its heterogeneous presentation and the absence of definitive diagnostic tests. Here again, the retina may offer valuable insights.

Retinal changes in Parkinson's disease include reduction in retinal nerve fiber layer thickness, macular thinning and changes in foveal pit morphology, likely reflecting the broad neurodegenerative process of this disease.⁵⁻⁷

Imaging techniques focusing on retinal dopaminergic cells—particularly amacrine cells—could provide additional biomarkers for early detection and monitoring of disease progression.⁸⁻¹⁰

Multiple sclerosis

MS, a chronic inflammatory and neurodegenerative disease marked by autoimmune-mediated demyelination of CNS neurons, represents another neurodegenerative condition for which retinal imaging has shown potential as a diagnostic and monitoring tool. The link between MS and ocular pathology, notably optic neuritis, has long been recognized. Now, with the

Retinal imaging biomarkers of neurodegenerative disease

Alzheimer's disease: Retinal amyloid imaging can detect disease before significant cognitive symptoms appear and optical coherence tomography angiography reveals associated retinal vascular alterations.

Parkinson's disease: Retinal changes include retinal nerve fiber layer thinning and macular changes, offering potential early indicators.

Multiple sclerosis: OCT reveals RNFL thinning, which correlates with brain atrophy and clinical disability.

availability of high-resolution retinal imaging, the relationship between the retina and broader neurodegenerative processes in MS is becoming clearer.

OCT has revealed RNFL thinning in MS patients, independent of optic neuritis, pointing toward a broader neurodegenerative process at play.¹¹

Retinal changes observed with OCT have been correlated with MRI measures of brain atrophy and clinical disability in MS patients, bolstering the case for retinal imaging as a noninvasive surrogate for neurodegeneration in MS.¹²⁻¹⁴

Challenges and future prospects

The promise of retinal imaging as a biomarker for neurodegenerative diseases is indeed compelling, but as with any emerging field, it's not without challenges and potential controversies. One critical hurdle is establishing standardized protocols for retinal imaging and interpretation, necessary for ensuring consistent and valid findings. This step is essential given the diversity of OCT devices and imaging techniques, without which inconsistencies could undermine the tool's efficacy.¹⁵

A second challenge involves understanding the complex relationship between

(Continued on page 17)



The patient with the puzzling plaques

The case for considering tuberculosis as an etiology in patients with posterior uveitis who have been to an endemic region.

A 33-year-old male who recently returned from a trip to Pakistan was evaluated in the emergency department at our tertiary referral center for four weeks of left eye irritation, light sensitivity, floaters, photopsias and blurred vision.

An outside ophthalmologist diagnosed him with posterior uveitis and QuantiFERON-TB Gold test returned positive on a laboratory workup. He was referred to infectious disease and started on rifampin for latent tuberculosis therapy, along with prednisone 80 mg daily. His vision continued to deteriorate until he was referred to our emergency department.

Examination findings

Best-corrected visual acuity was 20/20 in the right eye and count fingers in the left eye. Intraocular pressure was normal in both eyes. There was no afferent pupillary defect.

Slit lamp examination of the right eye was normal. The left eye had rare cells in the anterior vitreous. A dilated fundus examination revealed multifocal, deep, creamy, whitish lesions contiguous with the optic nerve. Additional active-appearing

lesions surrounded an area of multifocal scarring in the inferior retina (*Figure 1A*).

Workup

Fundus autofluorescence showed multifocal hypoautofluorescent lesions with surrounding hyperautofluorescence (*Figure 1B*). Optical coherence tomography showed attenuation of the retinal pigment epithelium, patchy loss of the ellipsoid zone and photoreceptors, and thickened and disorganized retinal laminations (*Figure 2, page 14*). Fluorescein angiography showed early blocking in the areas of the active choroidal lesions and late staining (*Figure 3*).

Complete blood count and comprehensive metabolic panel were within normal limits. Syphilis screen and HIV were both negative, and a chest X-ray was unremarkable. QuantiFERON-TB Gold was positive.

Diagnosis and management

We suspected serpiginous-like choroiditis and started the patient on four-drug therapy for tuberculosis: rifampin, isoniazid, pyrazinamide and ethambutol. We continued the prednisone 80 mg daily, and later initiated tacrolimus and azathioprine for

By **Laura Selby, MD**, and
K. Matthew McKay, MD



Laura Selby, MD



K. Matthew
McKay, MD

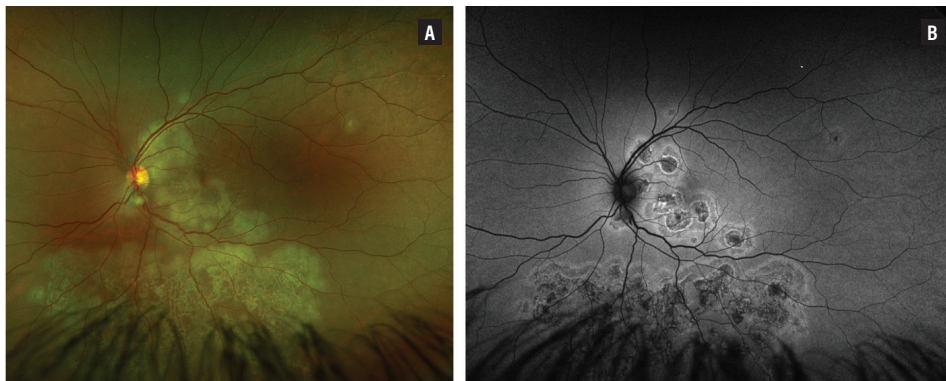


Figure 1. A) Color fundus photo of the left eye shows multifocal, deep yellowish choroidal lesions both in the posterior pole and inferior mid-periphery with central scarring and active-appearing edges. B) Fundus autofluorescence of the left eye demonstrates multifocal hypoautofluorescent lesions with surrounding hyperautofluorescence.

BIOS

Dr. Olmos de Koo is an associate professor of ophthalmology and director of the retina fellowship program at the University of Washington in Seattle, where Dr. Selby is an ophthalmology resident and Dr. McKay is a retina fellow.

DISCLOSURES:

The authors have no relevant relationships to disclose.

UW Medicine
EYE INSTITUTE

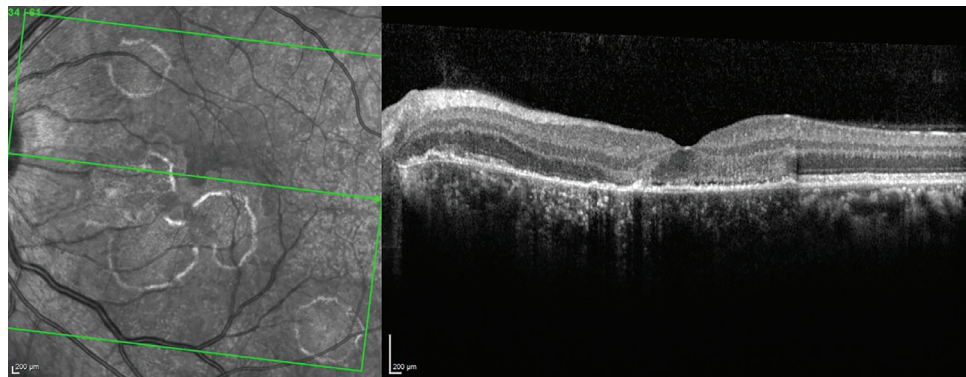


Figure 2. Optical coherence tomography of the left macula demonstrates ellipsoid zone loss, patchy photoreceptor layer loss, attenuation of the retinal pigment epithelium and thickened and disorganized retinal laminations.

progression of the inflammatory lesions.

Discussion

TB can affect multiple organs throughout the body, although ocular involvement is rare, occurring in approximately 0.2 to 2.7 percent of cases in nonendemic regions.^{1,2} Ocular TB presents in a variety of ways, which can make diagnosis difficult.


However, distinguishing tubercular uveitis from idiopathic uveitis is of utmost importance because lack of appropriate treatment in these cases threatens vision. Additionally, failure to consider tuberculosis as a potential cause of intraocular inflammation and treatment with immunosuppressive therapy can lead to death in patients with active TB.³

Tubercular choroiditis is the most common manifestation of posterior uveitis TB

causes. One phenotype of tubercular choroiditis is serpiginous-like choroiditis (SLC), which is characterized by multifocal yellowish lesions with a serpiginoid appearance that lead to progressive scarring. Patients with SLC are more likely to be from tuberculosis endemic regions, have unilateral involvement with multifocal lesions, and be younger at the time of presentation.⁴

Treatment of SLC involves antitubercular therapy (ATT) and corticosteroids starting with or shortly after initiating ATT.⁵ In our patient, antitubercular therapy and oral prednisone wasn't enough to control the aggressive and vision-threatening inflammation leading to initiation of additional immunosuppressive therapy.

Bottom line

Consider tuberculosis in patients from an endemic region who have posterior uveitis. Serpiginous-like choroiditis is one form of ocular tuberculosis that requires prompt initiation of antitubercular therapy. 

REFERENCES

1. Testi I, Agrawal R, Mehta S, Basu S, Nguyen Q, Pavesio C, Gupta V. Ocular tuberculosis: Where are we today? *Indian J Ophthalmol.* 2020;68:1808-1817.
2. Ang M, Chee SP. Controversies in ocular tuberculosis. *Br J Ophthalmol.* 2017;101:6-9.
3. Vianna RNG, Vanzan V, da Fonseca MLG, Cravo L. Unilateral macular serpiginous-like choroiditis as the initial manifestation of presumed ocular tuberculosis. *Int J Retina Vitreous.* 2021;7:1.
4. Dutta Majumder P, Biswas J, Gupta A. Enigma of serpiginous choroiditis. *Indian J Ophthalmol.* 2019;67:325-333.
5. Agrawal R, Testi I, Mahajan S, et al; Collaborative Ocular Tuberculosis Study Consensus Group. Collaborative Ocular Tuberculosis Study consensus guidelines on the management of tubercular uveitis-report 1: Guidelines for initiating antitubercular therapy in tubercular choroiditis. *Ophthalmology.* 2021;128:266-276.

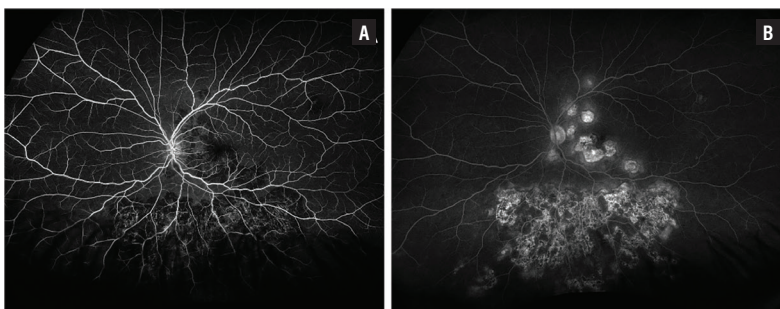

Figure 3. A) Fluorescein angiography of the left eye at 16 seconds shows patchy areas of early blocking in the macula and inferior mid-periphery. B) At 6:37 FA demonstrates late staining of those same areas corresponding with active lesions. Progressive staining of an inactive scar was also observed in the macula and inferior periphery.

A PUBLICATION BY REVIEW OF OPHTHALMOLOGY

RETINA SPECIALIST




KEEP UP WITH CUTTING-EDGE SCIENCE IN RETINA

Retina Specialist focuses on the latest advances in the diagnosis, medical management and surgical treatment of diseases of the retina, along with practical, real-world advice from leading clinicians and other experts on managing the successful retina practice.

Watch for issues in:

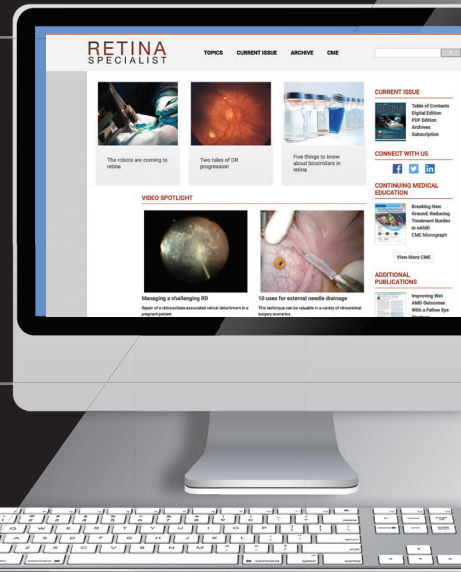- JANUARY/FEBRUARY
- MARCH/APRIL
- MAY/JUNE
- JULY/AUGUST
- SEPTEMBER/OCTOBER
- NOVEMBER/DECEMBER

WEBSITE
RETINA-SPECIALIST.COM



RETINA ONLINE

Each month, Medical Editor Philip Rosenfeld, MD, PhD, and our editors provide you with this timely and easily accessible report to keep you up to date on important information affecting the care of patients with vitreoretinal disease.



FOR INQUIRIES CONTACT
RETINASPECIALIST@JOBSON.COM

ADVERTISING OPPORTUNITIES

MICHAEL HOSTER • PUBLISHER • 610-492-1028 • MHOSTER@JOBSON.COM
MICHELE BARRETT • 215-519-1414 • MBARRETT@JOBSON.COM
JONATHAN DARDINE • 610-492-1030 • JDARDINE@JOBSON.COM

FOLLOW US

- @RetSpecMag
- RetinaSpecialistMag



Pearls for fovea-sparing ILM peeling

A potentially effective strategy for avoiding postoperative macular hole formation in myopic traction maculopathy.

By Masaki Suzue, MD,
and Taku Wakabayashi,
MD



Masaki Suzue, MD



Taku Wakabayashi,
MD

Fovea-sparing internal limiting membrane peeling is a surgical technique used to treat myopic traction maculopathy (MTM) in highly myopic eyes (Figure 1). This technique involves ILM peeling around the fovea while intentionally leaving a small area of intact ILM over the fovea.

Standard, or complete, ILM peeling for MTM carries a risk of postoperative macular hole formation in about 10 percent of patients. Therefore, fovea-sparing ILM peeling is an effective strategy for preventing MH and subsequent visual impairment (Figure 2). Here, we present pearls for performing successful fovea-sparing ILM peeling.

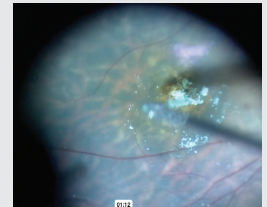Surgical techniques

- **Selecting the right forceps.** These eyes have a long axial length, so ILM peeling is challenging to perform using standard ILM forceps. Creating sclerotomies 4.5 to 5 mm from the limbus helps in reaching the macula. If you need additional reach to the macula, such as in patients with an axial length >30 mm, long-shaft ILM forceps are an option.

- **Residual vitreous cortex removal.** We routinely use triamcinolone to identify the status of the posterior vitreous detach-

View the Video

Watch as Dr. Suzue and Dr. Wakabayashi perform fovea-sparing internal limiting membrane peeling. Available at: bit.ly/VideoPearl-35.



ment and the presence of residual vitreous cortex. If no PVD exists, gentle induction of the PVD is in order because the posterior hyaloid often attaches to the macula.

Even if a PVD does exist, the vitreous cortex is typically present due to vitreoschisis, often leaving remnants adhering to the macula and blood vessels.

Repeated staining with triamcinolone and the use of forceps, a Tano scraper and a Finesse Flex loop can facilitate the efficient removal of the vitreous cortex.

- **Staining of the internal limiting membrane.** After removing the residual vitreous cortex, the ILM is well stained with indocyanine green or Brilliant Blue G. Gentle instillation and removal of these dyes are necessary because the fovea is very thin.

The infusion cannula should be oriented toward the mid-periphery or periphery to

BIOS

Dr. Suzue is a clinical instructor at Osaka University, Japan.

Dr. Wakabayashi is a research fellow at Wills Eye Hospital/Mid Atlantic Retina, Philadelphia, and an assistant professor of ophthalmology at Osaka University.

Dr. Felfeli is an ophthalmology resident at the University of Toronto.

DISCLOSURES: The authors and Dr. Felfeli have no relationships to disclose.

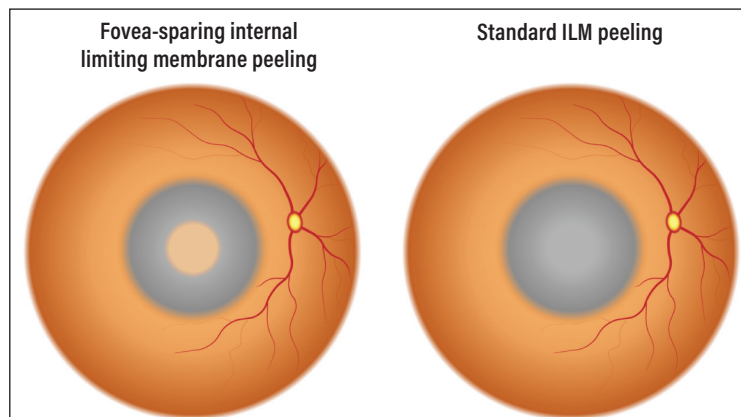


Figure 1. Schematic of fovea-sparing internal limiting membrane peeling and standard, or complete, ILM peeling.

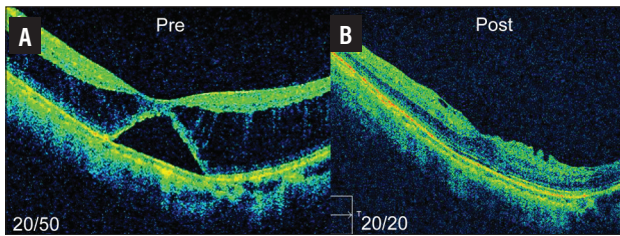


Figure 2. A) Myopic traction maculopathy with foveal retinal detachment. B) Postoperative optical coherence tomography after fovea-sparing internal limiting membrane peeling shows resolution of schisis.

keep the flow away from the fovea.

- **Sparing the fovea.** We use forceps to carefully peel off the ILM in a circular fashion around the fovea. Sometimes, the direction of peeling may unintentionally orient toward the fovea, so controlling the direction of peeling is crucial to ensure that it continues in a fovea-sparing manner.

The size of the remaining ILM at the fovea should be approximately 1 disc diameter to prevent postoperative epiretinal membrane. To achieve this, we gently elevate the edge of the remaining ILM, shaping it to be 1 disc diameter at the fovea. We then either leave the edge of the ILM or trim it, depending on the size of the ILM, using scissors or a cutter. When trimming with a cutter, it's important to ensure that its port is directed away from the fovea.

Applications

Postoperative MH may occur in any type of MTM, including retinoschisis, lamellar MH and foveal retinal detachment. Thus, fovea-sparing ILM peeling is recommended for any type of MTM to prevent postoperative MH.

However, eyes with chorioretinal atrophy are especially prone to MH after standard ILM peeling, likely due to their vulnerable thin retina. Therefore, myopic patients with chorioretinal atrophy may most likely benefit from fovea-sparing ILM peeling. ^{RS}

REFERENCES

1. Shimada N, Sugamoto Y, Ogawa M, Takase H, Ohno-Matsui K. Fovea-sparing internal limiting membrane peeling for myopic traction maculopathy. *Am J Ophthalmol.* 2012;154:693-701.
2. Ho TC, Chen MS, Huang JS, Shih YF, Ho H, Huang YH. Foveola nonpeeling technique in internal limiting membrane peeling of myopic foveoschisis surgery. *Retina.* 2012;32:631-4.
3. Shiraki N, Wakabayashi T, Ikuno Y, Matsumura N, Sato S, Sakaguchi H, Nishida K. Fovea-sparing versus standard internal limiting membrane peeling for myopic traction maculopathy: A study of 102 consecutive cases. *Ophthalmol Retina.* 2020;4:1170-1180.

Window to neurodegenerative disease

(Continued from page 12)

retinal changes and neurodegenerative diseases. The role these changes play, whether causative, epiphenomenal or reflective of common neurodegenerative processes, requires further research. Similarly, establishing the sensitivity and specificity of retinal changes for each disease is needed, given the overlapping clinical features and risk factors in neurodegenerative diseases.

Bottom line

Novel techniques, coupled with machine learning for image analysis, are providing more detailed retinal examinations and sophisticated data interpretation. This progress, however, should be tempered with ethical considerations related to early diagnosis, including potential psychological impacts on patients and treatment decision implications.

As we continue to navigate these challenges, the future of retinal imaging in neurodegenerative diseases looks promising. By viewing the retina not just as a window to the brain but as an integral part of the neurological landscape, we stand to gain invaluable insights into these complex diseases and develop innovative strategies to improve patient care. ^{RS}

REFERENCES

1. Lee S, Jiang K, McIlmoyle B, et al. Amyloid beta immunoreactivity in the retinal ganglion cell layer of the Alzheimer's eye. *Front Neurosci.* 2020;14:758.
2. Snyder PJ, Johnson LN, Lim YY, Santos CY, Alber J, Maruff P, Fernández B. Nonvascular retinal imaging markers of preclinical Alzheimer's disease. *Alzheimers Dement (Amst).* 2016;4:169-178.
3. Koronyo Y, Biggs D, Barron E, et al. Retinal amyloid pathology and proof-of-concept imaging trial in Alzheimer's disease. *JCI Insight.* 2017;2:e93621.
4. Hui J, Zhao Y, Yu S, Liu J, Chiu K, Wang Y. Detection of retinal changes with optical coherence tomography angiography in mild cognitive impairment and Alzheimer's disease patients: A meta-analysis. *PLoS One.* 2021;16:e0255362.
5. Huang L, Zhang D, Ji J, Wang Y, Zhang R. Central retina changes in Parkinson's disease: A systematic review and meta-analysis. *J Neurol.* 2021;268:4646-4654.
6. Pilat A, McLean RJ, Proudlock FA, et al. In vivo morphology of the optic nerve and retina in patients with Parkinson's disease. *Invest Ophthalmol Vis Sci.* 2016;57:4420-4427.
7. Satue M, Seral M, Otin S, et al. Retinal thinning and correlation with functional disability in patients with Parkinson's disease. *Br J Ophthalmol.* 2014;98:350-355.
8. Ortuño-Lizarán I, Sánchez-Sáez X, Lax P, et al. Dopaminergic retinal cell loss and visual dysfunction in Parkinson disease. *Ann Neurol.* 2020;88:893-906.
9. Lee JY, Martin-Bastida A, Murueta-Goyena A, et al. Multimodal brain and retinal imaging of dopaminergic degeneration in Parkinson disease. *Nat Rev Neurol.* 2022;18:203-220.
10. Moons L, De Groef L. Multimodal retinal imaging to detect and understand Alzheimer's and Parkinson's disease. *Curr Opin Neurobiol.* 2022;72:1-7.
11. Frohman EM, Fujimoto JG, Frohman TC, Calabresi PA, Cutter G, Balcer LJ. Optical coherence tomography: A window into the mechanisms of multiple sclerosis. *Nat Clin Pract Neurol.* 2008;4:664-675.
12. Burkholder BM, Osborne B, Loguidice MJ, et al. Macular volume determined by optical coherence tomography as a measure of neuronal loss in multiple sclerosis. *Arch Neurol.* 2009;66:1366-1372.
13. Saidha S, Al-Louzi O, Ratchford JN, et al. Optical coherence tomography reflects brain atrophy in multiple sclerosis: A four-year study. *Ann Neurol.* 2015;78:801-813.
14. Martínez-Lapiscina EH, Arnow S, Wilson JA, et al. Retinal thickness measured with optical coherence tomography and risk of disability worsening in multiple sclerosis: A cohort study. *Lancet Neurol.* 2016;15:574-584.
15. Yanagihara RT, Lee CS, Ting DS, Lee AY. Methodological challenges of deep learning in optical coherence tomography for retinal diseases: A review. *Transl Vis Sci Technol.* 2020;9:11.

Innovations in Retina Surgery


Practical applications of intraoperative OCT

A review of how it can be used for multiple retinal procedures, with more coming as technology advances.

By Rabia Karani, MD, MPH, and Amir H. Kashani, MD, PhD



Rabia Karani, MD, MPH



Amir H. Kashani, MD, PhD

Take-home points

- » Intraoperative optical coherence tomography is becoming a more commonly used tool for both anterior and posterior segment surgical cases.
- » Current approved, microscope-mounted iOCT devices provide real-time, high resolution images of the retina that may offer new insights into disease and surgical procedures.
- » iOCT is particularly useful for evaluating intraoperative changes during cases. Applications, such as membrane or internal-limiting membrane peeling subretinal procedures (gene therapy, stem cell delivery and Perfluoro-n-octane removal), are either already in use or on the horizon.

Optical coherence tomography is an essential tool in the modern-day retina practice. Since its conception three decades ago, OCT technology has evolved from having limited use in the clinical setting to being used in the diagnosis of almost every retinal disease.¹ OCT has been developed further to be used in the anterior segment of the eye, and even in fields such as gastroenterology and neurology.^{2,3}

One of the most recent applications of OCT technology is its use in guiding intraocular retinal surgery. This article discusses the practical application of microscope-integrated intraoperative OCT in the retina practice and the types of cases for which it is most useful.

Evolution of iOCT

An early attempt at using handheld OCT in the perioperative setting, separately from an exam under anesthesia, was to preoperatively and postoperatively scan the macula after epiretinal membrane and internal limiting membrane peeling.⁴ The surgeons

wrapped the handheld OCT scanner in a sterile covering. The surgeon controlled it while an assistant helped with the software.

Several other studies demonstrated the potential utility of using OCT intraoperatively in other areas, such as guiding membrane peel procedures and in analyzing subretinal fluid in retinal detachment repairs.⁵ However, handheld iOCT had a number of limitations, among them the need for precise patient positioning; user fatigue and motion, leading to artifacts during scanning; and the demand for a surgical pause when using the device.⁶

The introduction of microscope-mounted OCTs, the next iteration of iOCT, improved upon problems with scan quality and positioning by giving the surgeon precise OCT control with a foot pedal. This also improved image quality and reproducibility over handheld operation.

A prospective, case-controlled series using the Bioptigen SDOIS portable OCT on a custom-designed microscope-mounted system showed that iOCT imaging was feasible

BIOS

Dr. Karani is a vitreoretinal surgery fellow at the Wilmer Eye Institute of Johns Hopkins University in Baltimore.

Dr. Kashani is the Boone Pickens Professor of Ophthalmology and Biomedical Engineering at the Wilmer Eye Institute of Johns Hopkins University.

DISCLOSURES: Dr. Karani has no relevant disclosures.

Dr. Kashani is a consultant to Carl Zeiss Meditec and received honoraria and grant support from Carl Zeiss Meditec.

in 518 of 531 eyes (98 percent).⁷ A survey of the involved surgeons found that iOCT aided in surgical decision-making in 48 percent of anterior segment procedures and 43 percent of retina cases.

The most frequent procedures for which iOCT impacted decision-making were Descemet stripping automated endothelial keratoplasty (DSAEK) and deep anterior lamellar keratoplasty among anterior segment procedures, and pars plana vitrectomy with epiretinal membrane peeling and macular hole cases.⁷

Latest iteration of iOCT

The most recent and practical iteration of iOCT is the microscope-integrated iOCT. These OCT systems are integrated within the surgical microscope, allowing for surgeons to receive almost real-time feedback during a procedure without the need to stop the case or perform laborious manipulations of a handheld unit in a sterile setting.

A single-site, three-year, multisurgeon, prospective case series assessed the utility and feasibility of microscope-integrated iOCT for anterior and posterior segment procedures.⁸ Patients undergoing surgery were imaged using one of three iOCT systems—Leica EnFocus, Zeiss Rescan 700 or Haag-Streit iOCT (*Table*). An image was obtained in 820 of 837 study eyes (98 percent), demonstrating the feasibility of iOCT.

Participating surgeons indicated that iOCT impacted decision-making in 29 percent of posterior segment cases and 43 percent of anterior segment cases.^{8,9} Specif-

ically, decision making utility was found to be most impactful in DSAEK and Descemet membrane endothelial keratoplasty among anterior segment procedures, and membrane peeling, macular hole and proliferative vitreoretinopathy cases among posterior segment cases.⁸

iOCT indications: Vitreomacular interface disorders

Visually significant vitreomacular interface disorders often require surgical management with PPV, and ERM or ILM peel.¹⁰ Intraoperative OCT has potential in these cases because it allows the surgeon to find appropriate planes for peeling and areas of focal damage, as well as assess the vitreomacular interface intraoperatively after performing a peel procedure.

- **Macular hole closure.** This procedure often involves PPV with ILM peel and gas tamponade with posturing. The retinal architecture after membrane peeling is not well understood and discussion continues over the use of gas tamponades and how long patients should posture after surgery with gas.¹¹

A 2019 study of 37 patients showed that iOCT markers could be used to create a predictive model for macular hole closure, and help to prognosticate post-op vision and improve post-op posturing times.¹² A 2021 study of 10 eyes assessing macular hole closure during surgery using iOCT showed a decrease in minimal aperture macular hole diameter.¹³

As iOCT technology becomes more

Commercially available intraoperative optical coherence tomography systems

Manufacturer and model	Wavelength	Resolution	Scan rate (A scans per second)	Display	Special Features
Zeiss Opmi Lumera 700 with Rescan 700	840 nm	5.5 μm in tissue	27,000	22" LCD	Compatible with stereoscopic display
Leica Proveo 8 with EnFocus intraoperative OCT	860 nm	2.4 - 4 μm in tissue	36,000	27"HD monitors	Multiple configurations, external unit, ceiling mount or floor stand with Proveo 8
Haag Streit Hi-R NEO 900A NIR with OPMEDT OCT	840 nm	10 μm in air	10,000	6.5" touch-screen M.DIS	Video, snapshots, 3D images

Source: Manufacturers' websites

refined, we can continue to use it to more accurately visualize real-time effects of ILM peeling on macular hole closure.

- **Vitreomacular traction.** VMT release often requires PPV and ILM peeling, during which the underlying retinal tissues can become elevated or incur damage. A 2015 study of 163 patients showed that iOCT could demonstrate damage to the nerve fiber layer during ILM peeling. Most of these changes occurred from direct instrument contact and from indirect traction resulting from the membrane peel.¹⁴

- **Epiretinal membrane.** Treatment of ERM often involves both ERM and ILM peel. Classically, surgeons use ILM stains such as indocyanine green and Brilliant Blue G to help identify membranes. In a 2022 study of 56 eyes, half of the eyes underwent membrane peel without iOCT and half with it.

In the eyes that had membrane peel without iOCT, only 25 percent of surgeons reported they were able to peel without stain; the remaining 75 percent required stain. In the iOCT group, about 93 percent of membranes could be peeled without staining; only about 8 percent required staining.

These results showed that iOCT can help

assess epiretinal membrane removal, perhaps as efficaciously as dyes used for staining.¹⁵ iOCT illustrations (*Figure 1*) readily demonstrated change in the conformation of the retina and membrane before, during and after the membrane peel. This is particularly illustrative for trainees who may not be able to easily visualize these subtle changes. In addition, both experienced surgeons and trainees may use iOCT to confirm the boundaries of the peel and guide subsequent steps in the peeling procedure.

Tractional retinal detachments

TRDs and combined rhegmatogenous and tractional retinal detachments are a common complication in patients with proliferative diabetic retinopathy. Surgical techniques for these patients rely on creating tissue planes to dissect tractional membranes from the retina.

Current approaches to these detachments involve using the vitrector, retinal forceps and retinal scissors to dissect membranes. These techniques are effective, but accurately determining the tissue planes, adherence points and iatrogenic retinal breaks can be challenging.¹⁶

A 2018 study highlighted the utility of

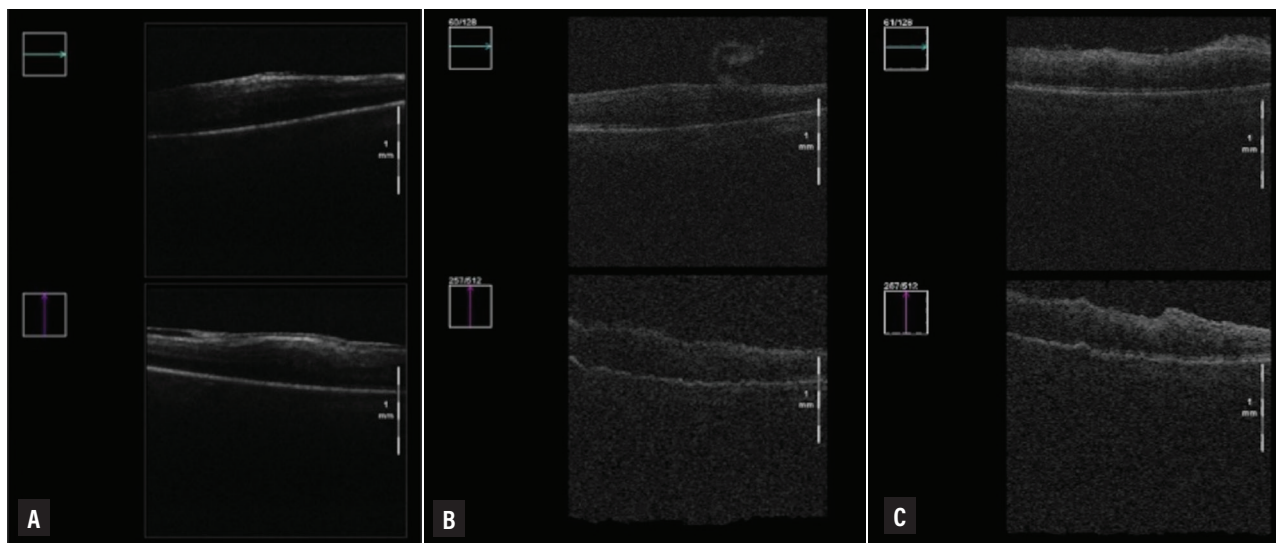


Figure 1. Illustration of intraoperative optical coherence tomography images before (A), during (B) and after (C) a case for membrane peeling highlight salient anatomic changes.

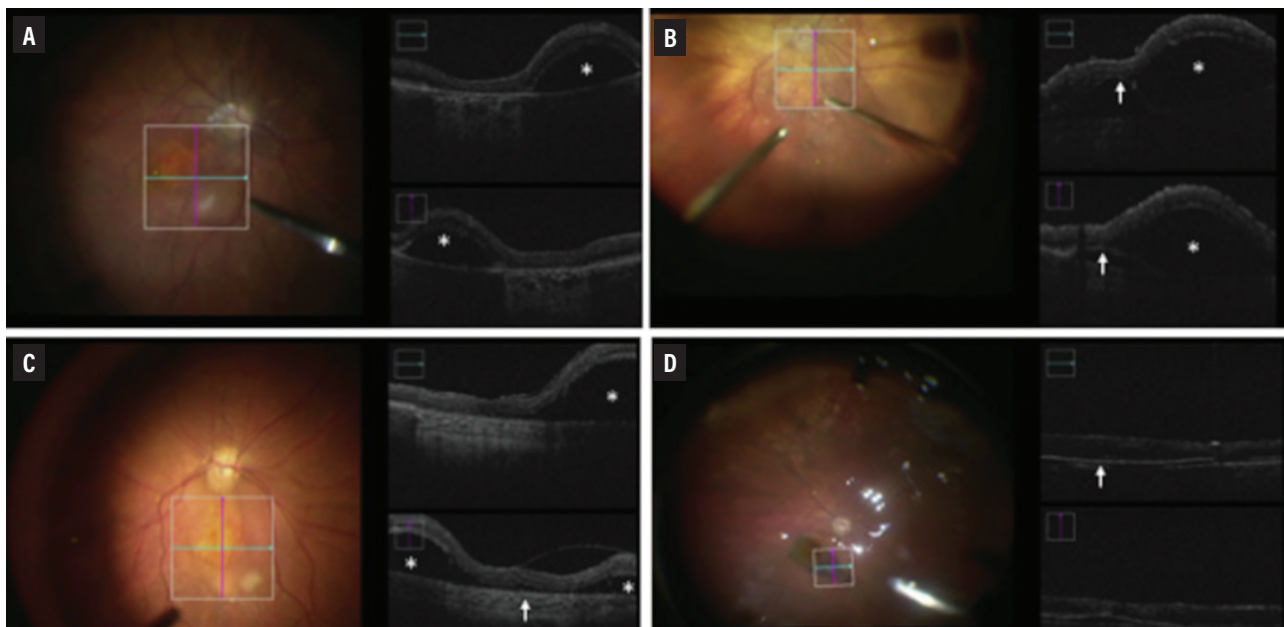


Figure 2. Intraoperative optical coherence tomography images from subretinal placement of CPCB-RPE1, a stem cell-derived retinal pigment epithelium monolayer seeded on a synthetic substrate. A) Bleb formation. B) Focal area of RPE detachment. C) Retinal adhesion to Bruch's membrane within the area of geographic atrophy. D) Flattening of the bleb after Perfluoro-n-octane injection and location of CPCB-RPE1 after administration. (Reproduced under Creative Commons License from Kashani AH, Uang J, Mert M, et al. Surgical method for implantation of a biosynthetic retinal pigment epithelium monolayer for geographic atrophy: Experience from a Phase 1/2a study. *Ophthalmol Retina*. 2020;4:264-273.)

iOCT for treatment of TRD in PDR.¹⁷ iOCT was successfully obtained in 80 of 81 study eyes (99 percent). Surgeons reported that in 51 percent of cases, iOCT provided valuable surgical information. In 26 percent of the cases, iOCT altered surgical decision-making, particularly in determining the presence of retinal breaks and the need for more membrane peeling.¹⁷

Two similar studies demonstrated that iOCT helped identify areas of fibrovascular adhesion and retinal holes, and helped decrease the amount of surgical instrumentation needed to create tissue planes.^{18,19} However, one limitation of iOCT in patients with PDR is preretinal hemorrhage.¹⁷

Many PDR patients have non-clearing vitreous hemorrhage before surgery, which makes preoperative OCT impractical. In these cases, iOCT allows for detailed assessment of the retina. As the technology becomes more widespread, surgical techniques are being developed around this modality to

help facilitate these types of procedures.

Rhegmatogenous retinal detachments

RRD repairs are among the most common procedures vitreoretinal surgeons do. In a 2013 series of nine eyes that had PPV for RRD repair, microscope-mounted iOCT showed foveal architecture changes in all patients.²⁰ The changes varied among patients, but included foveal thinning, foveal contour loss, inner retinal thinning and macular hole.

A separate study of nine patients in 2015 demonstrated persistent occult subretinal fluid after air-fluid exchange in all eyes, and further supported the rationale for face-down positioning in patients undergoing RRD repair and gas tamponade.²¹

A potential area of study for iOCT use could be to intraoperatively assess drainage success in patients having scleral buckle with drainage retinotomy for RRD repair. iOCT has the potential to further determine intraoperative microscopic changes that occur

during retinal detachment repair. Its uses in this procedure are still being elucidated.

Subretinal therapy

A particularly novel application of iOCT is in the space of subretinal surgery to treat inherited retinal diseases and nonexudative age-related macular degeneration. Current subretinal therapies involve injection of stem cell-derived tissues or transgenes in viral vectors underneath the retina.²² While most subretinal therapies are currently in clinical trial phase, the Food and Drug Administration in 2019 approved voretigene neparovec-rzyl (Luxturna, Spark Therapeutics)

as a subretinal gene therapy for biallelic RPE65 mutations.²³ This therapy is exclusively delivered with a subretinal bleb that can be monitored with iOCT.²⁴

Another group evaluated implantation of a stem cell-derived RPE monolayer seeded on a synthetic substrate (CPCB-RPE1). This showed the potential utility of iOCT in preparing for and confirming stem cell implant location.²² The study involved implanting an approximate 3-x-6-mm sheet of stem cell-derived RPE into an area of geographic atrophy in patients with advanced non-exudative AMD.

PPV was performed and a subretinal

pocket was created using a targeted hydrodissection technique encompassing the area of GA with a 1 disc diameter margin for 360 degrees. iOCT was used to assess the lateral dimensions and depth of the subretinal fluid pocket. Then, the implant was injected through a retinotomy into this subretinal pocket.

iOCT was used at several key points throughout the procedure, including before bleb formation to assess the area of GA, after bleb formation to assess bleb size, after implantation to determine implant orientation, and after flattening of the subretinal pocket with PFO (Figure 2, page 21). iOCT was used in nine of 16 enrolled subjects, and it proved useful in determining areas of incomplete subretinal hydrodissection to create a subretinal pocket, in identifying incorrect implant placement and in dissecting subretinal adhesions to Bruch's membrane.

Several studies have

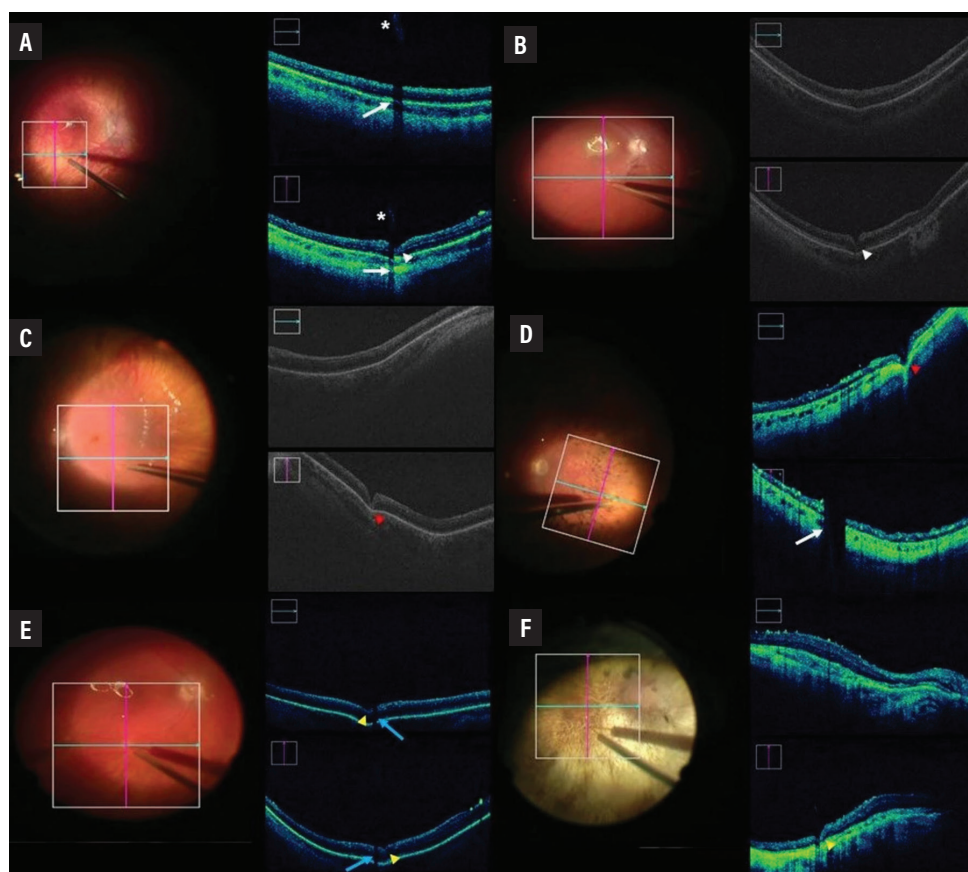


Figure 3. Intraoperative optical coherence tomography images obtained during gene therapy surgery. **A,B)** Unsuccessful initial step of subretinal injection with blunted needle with corresponding shadow of subretinal cannula. **C,D)** Successful subretinal injection with blunted needle with corresponding shadow of subretinal cannula. **E,F)** Successful subretinal injection with sharp needle with corresponding shadow of subretinal cannula are demonstrated. (Reproduced under Creative Commons Attribution License from Vasconcelos HM Jr, Lujan BJ, Pennesi ME, Yang P, Lauer AK. Intraoperative optical coherence tomographic findings in patients undergoing subretinal gene therapy surgery. *Int J Retina Vitreous.* 2020;6:13.)

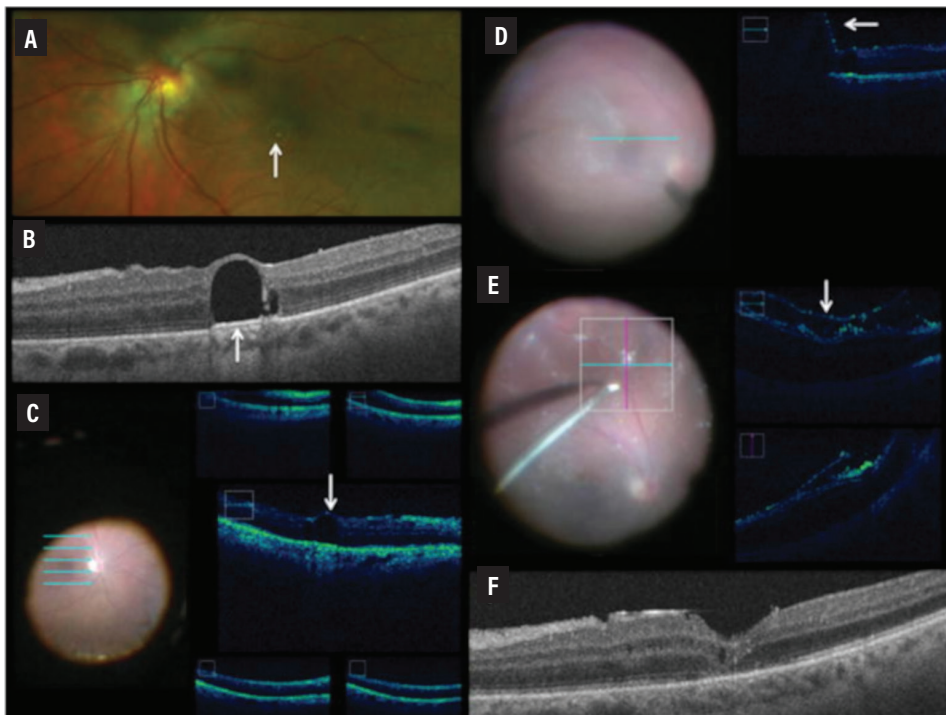


Figure 4. Intraoperative optical coherence tomography for subretinal Perfluoro-n-octane removal. A) Macular photo shows chronic retained subfoveal PFO. B) Preoperative OCT of subretinal PFO. C) Five-line raster scan depicting subretinal fluid at the beginning of a case. D) One-line raster scan depicting subretinal bleb induction with 41-gauge cannula. E) iOCT horizontal and vertical scan demonstrating detached retina, proliferative vitreoretinopathy and Triesence staining. F) OCT at three months postoperatively shows the absence of PFO, inner/outer segment junction abnormalities and trace macular edema.

explored the utility of iOCT in the subretinal delivery of transgenes on viral vectors.²⁵ The largest study in this area is a 2020 study involving patients enrolled in various subretinal gene therapy trials, including 19 eyes in which subretinal blebs were created.²³ The participating surgeons used sharp or blunt needle tips to create a subretinal bleb, based on their discretion, and iOCT to determine the difference between the two different needle techniques. iOCT visualized medication injection, medication reflux and retinotomy size (*Figure 3*).

While iOCT is useful in subretinal procedures, certain limitations have been highlighted in its use. These include a relatively small field of view, operative site shadowing with surgical instruments and the need for training to become skilled with the technology.²⁵ As subretinal surgery techniques are refined, the role of iOCT in this arena will continue to evolve.

Other subretinal procedures

Intraoperative OCT has also been used in subfoveal Perfluoro-n-octane (PFO) removal

and in subretinal tissue plasminogen activator (tPA) injection.

- **PFO removal.** PFO entrapment is a rare but potentially serious complication of using PFO in retinal detachment surgery. We commonly use it to flatten the retina and to displace subretinal fluid. Entrapment of PFO under the retina can manifest as a scotoma, which can cause visual impairment when present under the fovea.

Symptomatic PFO entrapment requires surgical removal, but there's no commonly accepted way of approaching this problem. Surgical approaches include using a 41-gauge needle to aspirate the PFO bubble or a 38-gauge macular hydrodissection cannula, both of which are transretinal.²⁶⁻²⁸ These approaches all involve precise preoperative planning using OCT and don't allow direct visualization of the PFO removal process.

With iOCT, the surgeon can directly visualize the needle as it approaches the bubble and avoid damage to nearby structures, as well as ensure the bubble has been removed intraoperatively. A 2015 case report showed

Retinal surgery is all about visualization, and iOCT allows us to visualize the retina in previously unseendetail and dimension. Capitalizing on this will allow us to make more informed decisions during surgery.


successful use of the iOCT to remove PFO using a 41-gauge needle (*Figure 4, page 23*).²⁹

• **tPA injection.** Significant submacular hemorrhage is a devastating complication of nAMD. Dense hemorrhage is often difficult to clear with standard anti-VEGF injections, and can cause photoreceptor loss and subretinal fibrosis. In such cases, tPA injection has been shown to liquify and help displace the hemorrhage when coupled with a gas bubble.

This procedure involves creating a retinotomy with a 41-gauge cannula, injection of the tPA in the subretinal space and fluid-air exchange. Similar to PFO removal, current techniques don't allow for direct visualization of the subretinal procedure and of confirmation of tPA injection.³⁰ A 2015 case used a microscope-mounted iOCT to confirm appropriate localization of tPA injection.³⁰ While this was the first report of this technique, advancements in technology and more widespread availability of iOCT will likely increase use of this procedure.

Bottom line

Retinal surgery is all about visualization, and iOCT allows us to visualize the retina during surgery in previously unseen detail and dimension. Capitalizing on this ability will allow us to make more informed decisions during surgery and ultimately lead to better outcomes for patients.

Intraoperative OCT technology will continue to advance and find different roles in vitreoretinal surgery and will ultimately allow surgeons to perform safer and more efficient retinal procedures, while simultaneously allowing us to glean more knowledge about the retina as it undergoes surgery. 

REFERENCES

- Gabriele M, Wollstein G, Ishikawa H, Kagemann L, et al. Optical coherence tomography: History, current status, and laboratory work. *Invest Ophthalmol Vis Sci.* 2011;52:2425-2436.
- Tsai TH, Leggett CL, Trindade AJ, Sethi A, et al. Optical coherence tomography in gastroenterology: A review and future outlook. *J Biomed Opt.* 2017;22:1-17.
- Maldonado RS, Mettu P, El-Dairi M, Bhatti MT. The application of optical coherence tomography in neurologic diseases. *Neuro Clin Pract.* 2015;5:460-469.
- Dayani PN, Maldonado R, Farsiu S, Toth CA. Intraoperative use of handheld spectral domain optical coherence tomography imaging in macular surgery [Published correction appears in *Retina.* 2011;31:1236]. *Retina.* 2009;29:1457-1468.

- Hahn P, Migacz J, O'Connell R, Maldonado RS, et al. The use of optical coherence tomography in intraoperative ophthalmic imaging. *Ophthalmic Surg Lasers Imaging.* 2011;42 Suppl:S85-S94.
- Jayadev C, Dabir S, Vinekar A, Shah U, Vaid T, Yadav NK. Microscope-integrated optical coherence tomography: A new surgical tool in vitreoretinal surgery. *Indian J Ophthalmol.* 2015;63:399-403.
- Ehlers JP, Dupps WJ, Kaiser PK, et al. The Prospective Intraoperative and Perioperative Ophthalmic Imaging with Optical Coherence Tomography (PIONEER) Study: 2-year results. *Am J Ophthalmol.* 2014;158:999-1007.
- Ehlers JP, Modi YS, Pecen PE, et al. The DISCOVER Study 3-Year Results: Feasibility and Usefulness of Microscope-Integrated Intraoperative OCT during Ophthalmic Surgery. *Ophthalmology.* 2018;125:1014-1027.
- Ehlers JP, Goshe J, Dupps WJ, et al. Determination of feasibility and utility of microscope-integrated optical coherence tomography during ophthalmic surgery: The DISCOVER Study RESCAN results. *JAMA Ophthalmol.* 2015;133:1124-1132.
- Levison, AL and Kaiser, PK. Vitreomacular interface diseases: diagnosis and management. *Taiwan J Ophthalmol.* 2014;4:63-68.
- Ehlers JP, Xu D, Kaiser PK, Singh RP, Srivastava SK. Intraoperative dynamics of macular hole surgery: An assessment of surgery-induced ultrastructural alterations with intraoperative optical coherence tomography. *Retina.* 2014;34:213-221.
- Ehlers JP, Uchida A, Srivastava SK, Hu M. Predictive model for macular hole closure speed: insights from intraoperative optical coherence tomography. *Trans Vis Sci Tech.* 2019;8:18.
- Nishitsuka K, Nishi K, Namba H, Kaneko Y, Yamashita H. Intraoperative observation of a macular hole using optical coherence tomography. *Clin Optom (Auckl).* 2021;13:113-118.
- Ehlers JP, Han J, Petkovsek D, Kaiser PK, et al. Membrane peeling-induced retinal alterations on intraoperative oct in vitreomacular interface disorders from the PIONEER study. *Invest Ophthalmol Vis Sci.* 2015;56:7324-7330.
- Lorusso M, Micelli Ferrari L, Gisotti EN, et al. Success of iOCT in surgical management of ERM peeling. *Eur J Ophthalmol.* 2022;32:3116-3120.
- Khan M, Ehlers JP. Clinical utility of intraoperative optical coherence tomography. *Curr Opin Ophthalmol.* 2016;27:201-209.
- Khan M, Srivastava SK, Reese JL, Shwani Z, Ehlers JP. Intraoperative OCT-assisted surgery for proliferative diabetic retinopathy in the DISCOVER study. *Ophthalmol Retina.* 2018;2:411-417.
- Agarwal A, Gupta V. Intraoperative optical coherence tomography and proportional reflux hydrodissection-guided pars plana vitrectomy for complex severe proliferative diabetic retinopathy. *Indian J Ophthalmol.* 2020;68:177-181.
- Gabr H, Chen X, Zevallos-Carrasco OM, et al. Visualization from intraoperative swept-source microscope-integrated optical coherence tomography in vitrectomy for complications of proliferative diabetic retinopathy. *Retina.* 2018;38 Suppl 1:S110-S120.
- Ehlers JP, Ohr MP, Kaiser PK, Srivastava SK. Novel microarchitectural dynamics in rhegmatogenous retinal detachments identified with intraoperative optical coherence tomography. *Retina.* 2013;33:1428-1434.
- Toygar O, Riemann CD. Intraoperative optical coherence tomography in macula involving rhegmatogenous retinal detachment repair with pars plana vitrectomy and perfluorocarbon. *Eye (Lond).* 2016;30:23-30. doi:10.1038/eye.2015.230.
- Kashani AH, Uang J, Mert M, et al. Surgical method for implantation of a biosynthetic retinal pigment epithelium monolayer for geographic atrophy: Experience from a Phase 1/2a study. *Ophthalmol Retina.* 2020;4:264-273.
- Vasconcelos HM Jr, Lujan BJ, Pennesi ME, Yang P, Lauer AK. Intraoperative optical coherence tomographic findings in patients undergoing subretinal gene therapy surgery. *Int J Retina Vitreous.* 2020;6:13.
- Ameri H. Prospect of retinal gene therapy following commercialization of voretigene neparvovec-rzyl for retinal dystrophy mediated by RPE65 mutation. *J Curr Ophthalmol.* 2018;30:1-2.
- Ladha R, Caspers LE, Willemain F, de Smet MD. Subretinal therapy: Technological solutions to surgical and immunological challenges. *Front Med (Lausanne).* 2022;9:846782.
- García-Arumí J, Castillo P, López M, et al. Removal of retained subretinal perfluorocarbon liquid. *Br J Ophthalmol.* 2008;92:1693-1694.
- Ghasemi Falavarjani K, Anvari P. Surgical removal of submacular perfluorocarbon liquid using a 41-gauge extendible subretinal injection needle. *J Ophthalmic Vis Res.* 2019;14:393-397.
- Hanout M, Muni RH. Novel surgical technique to remove retained subfoveal perfluorocarbon liquid. *Retin Cases Brief Rep.* 2021;15:741-744.
- Smith AG, Cost BM, Ehlers JP. Intraoperative OCT-assisted subretinal perfluorocarbon liquid removal in the DISCOVER study. *Ophthalmic Surg Lasers Imaging Retina.* 2015;46:964-966.
- Ehlers JP, Petkovsek DS, Yuan A, Singh RP, Srivastava SK. Intraoperative assessment of subretinal tPA injection for submacular hemorrhage in the PIONEER study utilizing intraoperative OCT. *Ophthalmic Surg Lasers Imaging Retina.* 2015;46:327-332.

Innovations in Retina Surgery

3D heads-up visualization: Less pain, more gain

Three-dimensional heads-up display can enhance surgical visualization, training, ergonomics and potentially surgical outcomes.

By Nita Valikodath, MD, MS, and Lejla Vajzovic, MD

Take-home points


- » Three-dimensional, heads-up display (HUD) provides a high-resolution view with improved stereopsis, magnification, depth of field and high contrast profiles with improved ergonomics.
- » Studies have shown that 3D HUD is safe in vitreoretinal surgery.
- » Outcomes are similar to the conventional operating microscope in macular surgery, although 3D HUD involves a learning curve.
- » The shared view of 3D HUD contributes to an improved surgical teaching environment for trainees.

Three-dimensional heads-up display is an exciting and innovative advancement in vitreoretinal surgery. The 3D system gives the surgeon a digital, stereoscopic, high-definition view of the surgical field on an external monitor without looking through the operating microscope.

Initially introduced by Claus Eckardt,

MD, the uses and indications for 3D heads-up display, or HUD, continue to expand.¹⁻³ Through the use of a high-dynamic range camera, an image is projected onto a 55-inch organic light-emitting diode, high-definition display.⁴

Today, two 3D HUD models are available commercially in the United States: the



Nita Valikodath,
MD, MS



Lejla Vajzovic, MD

BIOS

Dr. Valikodath is a second-year vitreoretinal surgery fellow at Duke University, Durham, N.C., with a clinical research interest in imaging advancements in pediatric and adult retina.

Dr. Vajzovic is an associate professor of ophthalmology specializing in adult and pediatric retinal diseases and surgery at Duke University. She has a clinical research emphasis in vitreoretinal surgical advancements, including heads-up display technology.

DISCLOSURES: Dr. Valikodath has no relevant relationships to disclose.

Dr. Vajzovic disclosed relationships with AGTC Corp., Alcon, Aldeyra, Alimera Sciences, Allergan/AbbVie, Apellis Pharmaceuticals, Bausch + Lomb, BVI, DORC, Gyroscope, Heidelberg Engineering, Iveric Bio, Janssen, Novartis, Ocugen, Ocular Therapeutix, Regenxbio and Roche/Genentech.

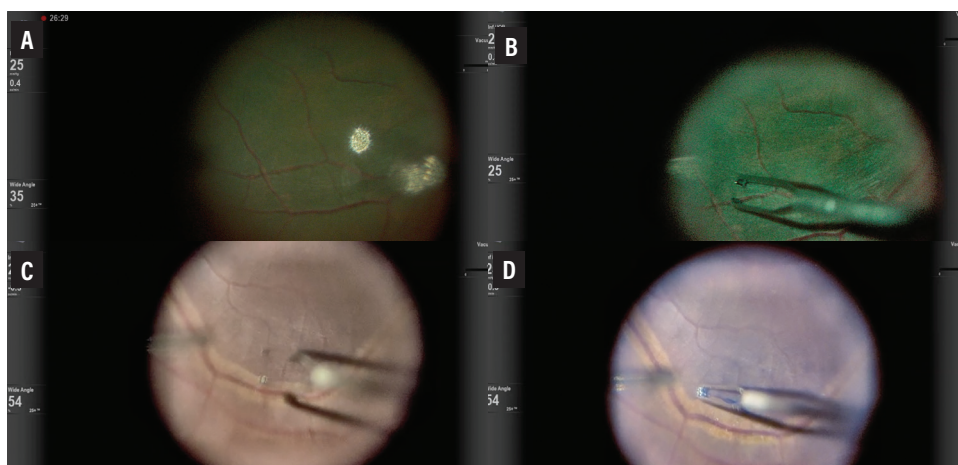


Figure 1. Comparison of standard (A and C), green boost (B) and blue boost (D) views during internal limiting membrane peeling for macular hole surgery.

Ngenuity 3D system (Alcon Laboratories) and the Artevo 800 system (Zeiss). Another form of heads-up display, the Beyeonics One system (Beyeonics Vision) uses a digital microscope that transmits a signal to a visor the surgeon wears. We will report on our experience with 3D HUD based on our use of the Ngenuity system.

Enhanced visualization

One of the main advantages of 3D HUD display includes enhanced high-resolution visualization and video chromatography. Various color profiles and camera gain adjustments can help digitally augment images to highlight pathology or areas of interest. This is especially useful to enhance visualization of vital dyes such as indocyanine green or Brilliant Blue G (*Figure 1, page 25*). The green boost and blue boost allow im-

proved visualization of the internal limiting membrane after staining with ICG and BBG, respectively. Various color, contrast and tissue detail modes enable better visualization of the vitreous (*Figure 2*). Operators can customize the colored channels.

Other advantages of 3D HUD include improved stereopsis and depth of field compared with the standard operating microscope. The surgeon and viewers must wear passive polarized glasses to obtain stereopsis. The system can preserve magnification even with a larger field of view.^{2,5} Endoillumination settings are also adjustable and overall the system requires lower endoillumination (3 to 10 percent vs. 30 to 40 percent in the operating microscope), which is advantageous for avoiding phototoxicity.^{6,7}

Shared surgical experience

The 3D glasses provide all OR surgical staff with a shared view of the surgery. This can be advantageous for OR flow as the surgical assistant, scrub technician and others anticipate progress and tools needed in surgery. This technology provides an important pedagogical value, especially in settings with trainees. The enhanced visualization allows for an improved learning experience and doesn't depend on accommodative ability, which can be limited with the standard operating microscope.^{8,9} Also, 3D HUD systems can record and save videos.

Ergonomics

Surgeon ergonomics are important and can affect surgical performance. The height of the 3D HUD can be adjusted and the display can be positioned in a place that's most comfortable for the surgeon. It eliminates the need to look through a microscope which can cause back and neck issues.

A high proportion of ophthalmologists with musculoskeletal disorders has been reported. Claus Eckardt, MD, and Eric Paulo, MD, reported that 91.7 percent of participants (n=20) preferred the ergonomics of the HUD over the traditional approach.³

A Saudi Arabia study (n=132) reported

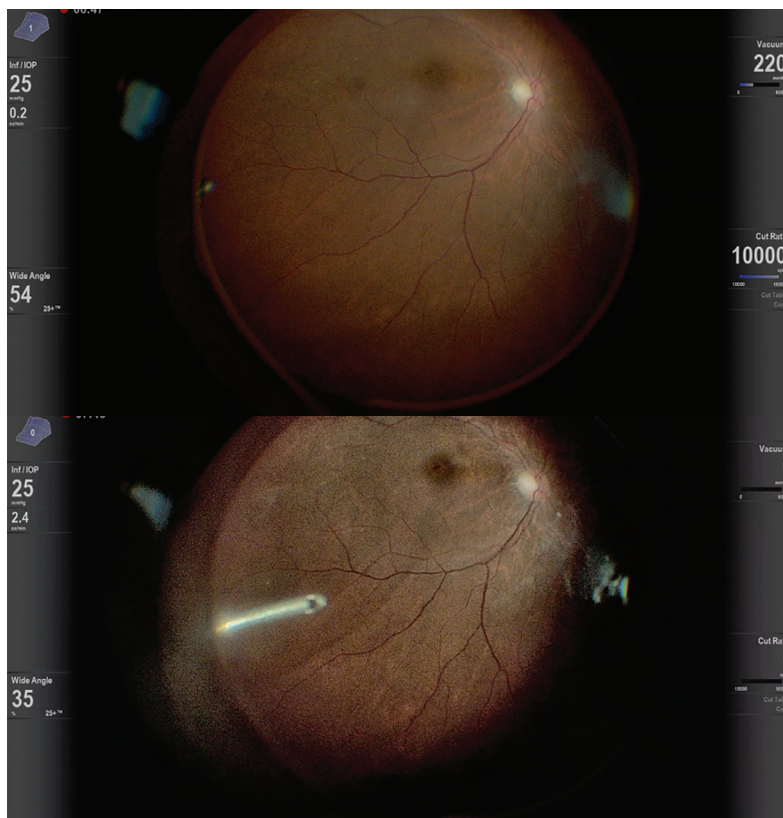

Figure 2. Three-dimensional heads-up display permits improved visualization of the vitreous through various color, contrast and tissue detail modes. The colored channels can be customized for each surgeon.

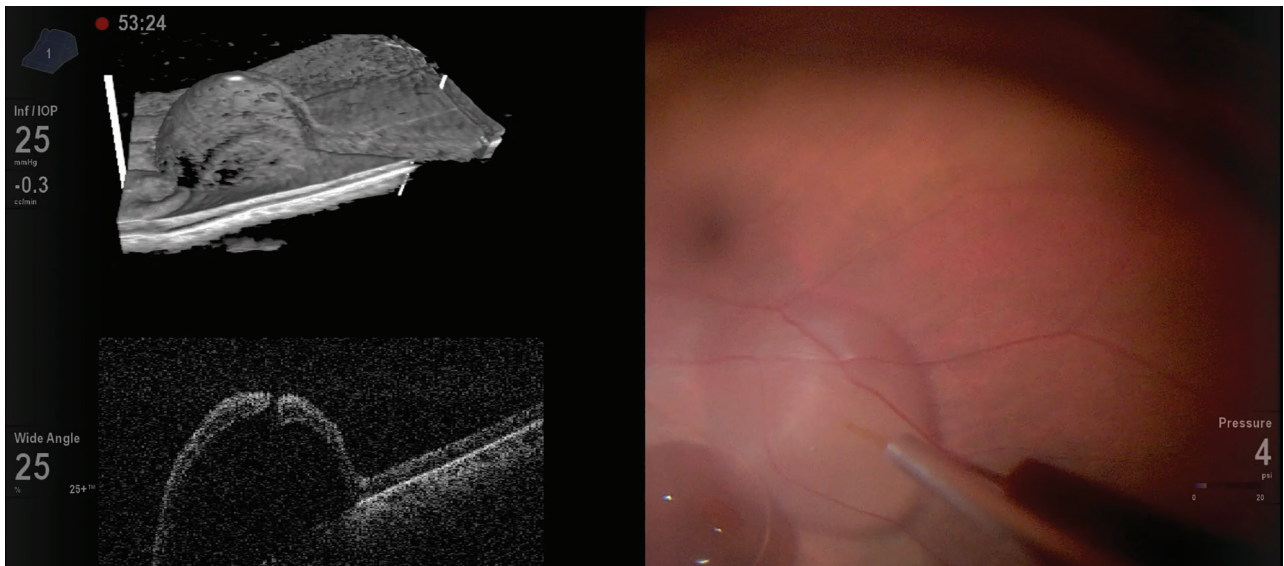


Figure 3. Heads-up display during gene therapy placement with intraocular optical coherence tomography.

higher pain intensity in surgeons who used a standard operating microscope vs. HUD users.¹⁰ The study noted that HUD could help improve career longevity and productivity, but the monitor must be positioned appropriately at the beginning of the case or the surgeon may find themselves looking around the operating scope to see the display.

Imaging

HUD can allow side-by-side or superimposed images of intraoperative optical coherence tomography images in real-time. The DISCOVER study, which evaluated microscope-integrated OCT with 3D visualization, reported its use in procedures such as macular surgery and retinal detachment repair with proliferative vitreoretinopathy.¹¹

The surgeon can view the OCT image without looking away from the monitor. 3D HUD integrated with iOCT has also been investigated for gene therapy and subretinal tPA injection, and has aided in visualization of the retinal architecture to ensure proper delivery of subretinal drugs (Figure 3).¹²⁻¹⁷

Potential drawbacks

Using HUD technology involves a learning curve. Some surgeons have reported a lag between instrument movement and the

display image. Other disadvantages include longer set-up and operating times for early users, physical space limitations and cost.

Ideally, the spatial layout should be coordinated with the OR team and anesthesia to position the monitor 1.5 meters from the surgeon, typically at the foot of the operating table (Figure 4, page 30). Lastly, one must view in 3D for the entire case. That may cause eye strain and asthenopia.

Some steps of vitreoretinal surgery may be more difficult with 3D HUD compared with the operating microscope. New users should start with straightforward cases, such as non-clearing vitreous hemorrhage or macular cases, instead of secondary intraocular lens or complex retinal detachments.

Endolaser can be more challenging with the 3D HUD because the laser beam and laser uptake can be more difficult to visualize. In one survey, fellows and residents reported worse experience with endolaser and closing compared with the standard operating microscope.⁹ However, these outcomes may also be affected by the initial learning curve and user experience.

Potential applications of 3D HUD

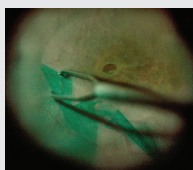
- **Macular surgery.** For epiretinal membrane peel and macular hole surgeries,

Artificial intelligence and computer vision can be incorporated into 3D HUD and enhance audiovisual feedback to the surgeon.

various stains, including BBG and ICG, can be used. The color filters of the HUD system can help to minimize or avoid the use of dyes. For example, the digital red-free filter can highlight ILM. Thomas Aaberg Jr., MD, of Retina Specialists of Michigan, has reported using half the concentration of the vital dye without affecting performance.

Video 1:

ILM peeling with ICG dye and the use of the green boost filter. Available at: bit.ly/RetSpec-3DHUD-Video-1-2023



A Wills Eye Hospital study compared 3D HUD and the standard operating microscope for ERM and macular hole surgery.² It showed that 3D HUD was safe for macular surgery, used lower-light settings and had similar outcomes compared to the conventional system. However, in this study, operating times were longer and surgeons found the operating microscope easier to use.²

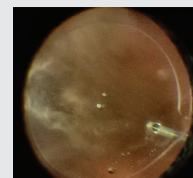
An Italian study reported ease of use was higher in the 3D HUD group than the operating microscope group.¹⁸ These researchers found that surgeon satisfaction and ease of use with the 3D HUD system likely correlated to experience and differences in learning curve. Interestingly, another study evaluated

VR fellows and surgical trainees performing macular hole closure, rates of which were higher in the 3D HUD group. The authors hypothesize that better visualization and instruction from mentors was possible with the 3D HUD system.¹⁹

• **Retinal detachment and vitreous hemorrhage.** Another study from Italy reported on 3D HUD for rhegmatogenous retinal detachment surgery with vitrectomy, finding that the 3D HUD group didn't need triamcinolone while the standard microscope group did.²⁰ The authors thought this was due to high-resolution images and use of digital filters with the 3D HUD system. They also reported reduced endoillumination settings in the 3D HUD group.

Video 2:

Vitrectomy for vitreous hemorrhage associated with a retinal tear. Available at: bit.ly/RetSpec-3DHUD-Video-2-2023



They found that the 3D HUD group had good outcomes with no redetachments and no major postoperative complications. Specific contrast adjustments can enhance vitreous visualization, leading to efficient removal of the vitreous hemorrhage and peripheral vitreous.

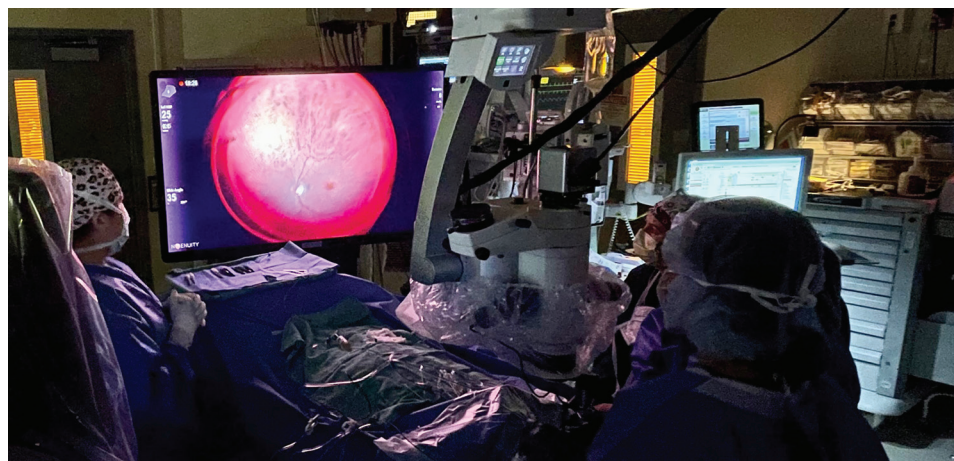


Figure 4. Layout of the three-dimensional, heads-up display system in the operating room.

- **Gene therapy.** 3D HUD can be valuable when performing subretinal gene therapy. The enhanced depth of view and high-resolution display can allow for improved surgical performance especially with subretinal bleb creation and propagation. In addition, as we mentioned, incorporating iOCT on the same display offers advantages. Delivering the gene therapy subretinally is important, but reflux from the retinotomy site or leakage into the intravitreal cavity can occur. This can be subtle in the microscope view, but on 3D HUD the leakage can be seen on the display, often more evident from the shadow of the needle.


- **Other uses.** HUD has been used for more challenging cases such as pathologic myopic foveoschisis, dislocated intraocular lens removal and exchange, retinal prosthesis implantation, such as the Argus II device, and more.²¹⁻²³

Future directions

Artificial intelligence and computer vision can be incorporated into 3D HUD and enhance audiovisual feedback to the surgeon. In cataract surgery, a deep-learning algorithm was developed that could provide real-time identification of surgical phase.

In addition, AI could provide guidance during surgery by outlining a template for capsulorhexis or displaying excessive turbulence.²⁴ In vitreoretinal surgery, an AI algorithm helped localize tissues, such as the fovea, and instruments, such as the vitrector tool tip. This type of surgical guidance could potentially avoid unintended contact of important structures leading to safer surgery.²⁵

Bottom line

3D HUD enhances visualization during vitreoretinal surgery and offers an advantage for surgical teaching through a shared surgical experience, although it involves a learning curve. 

REFERENCES

1. Williams GA. Surgical viewing: Do you see what I see? *Retina*. 2017;37:1219.
2. Talcott KE, Adam MK, Sioufi K, et al. Comparison of a three-dimensional heads-up display surgical platform with a standard operating microscope for macular surgery.

Ophthalmol Retina. 2019;3:244-251.

3. Eckardt C, Paulo EB. Heads-up surgery for vitreoretinal procedures: An experimental and clinical study. *Retina*. 2016;36:137-147.

4. González-Saldivar G, Chow DR. Optimizing visual performance with digitally assisted vitreoretinal surgery. *Ophthalmic Surg Lasers Imaging Retina*. 2020;51:S15-S21.

5. Freeman WR, Chen KC, Ho J, et al. Resolution, depth of field, and physician satisfaction during digitally assisted vitreoretinal surgery. *Retina*. 2019;39:1768-1771.

6. Thornton S, Adam MK, Ho AC, Hsu J. Endoillumination levels and display luminous emittance during three-dimensional heads-up vitreoretinal surgery. Poster presented at: Annual Meeting of the Association for Research in Vision and Ophthalmology; May 4, 2016; Seattle, WA.

7. Adam MK, Thornton S, Regillo CD, Park C, Ho AC, Hsu J. Minimal endoillumination levels and display luminous emittance during three-dimensional heads-up vitreoretinal surgery. *Retina*. 2017;37:1746-1749.

8. Agranat JS, Miller JB. 3D surgical viewing systems in vitreoretinal surgery. *Int Ophthalmol Clin*. 2020;60:17-23.

9. Shoshany TN, Agranat JS, Armstrong G, Miller JB. The user experience on a 3-dimensional heads-up display for vitreoretinal surgery across all members of the health care team: A survey of medical students, residents, fellows, attending surgeons, nurses, and anesthesiologists. *J Vitreoretin Dis*. 2020;4:459-466.

10. Bin Helayel H, Al-Mazidi S, AlAkeely A. Can the three-dimensional heads-up display improve ergonomics, surgical performance, and ophthalmology training compared to conventional microscopy? *Clin Ophthalmol*. 2021;15:679-686.

11. Ehlers JP, Uchida A, Srivastava SK. The integrative surgical theater: combining intraoperative optical coherence tomography and 3D digital visualization for vitreoretinal surgery in the DISCOVER study. *Retina*. 2018;38:S88-S96.

12. Ehlers JP, Petkovsek DS, Yuan A, Singh RP, Srivastava SK. Intraoperative assessment of subretinal tpa injection for submacular hemorrhage in the PIONEER study utilizing intraoperative OCT. *Ophthalmic Surg Lasers Imaging Retina*. 2015;46:327-332.

13. Raynor W, Li JD, Sastry A, et al. Optimizing subretinal gene therapy delivery with microscope-integrated optical coherence tomography and novel suprachoroidal delivery system. *Invest Ophthalmol Vis Sci*. 2020;61:4487.

14. Hsu ST, Gabr H, Viehland C, et al. Volumetric measurement of subretinal blebs using microscope-integrated optical coherence tomography. *Transl Vis Sci Technol*. 2018;7:19.

15. Sastry A, Li JD, Raynor W, et al. Microscope-integrated OCT-guided volumetric measurements of subretinal blebs created by a suprachoroidal approach. *Transl Vis Sci Technol*. 2021;10:24.

16. Vajzovic L, Sleiman K, Viehland C, et al. Four-dimensional microscope-integrated optical coherence tomography guidance in a model eye subretinal surgery. *Retina*. 2019;39:S194-S198.

17. Li JD, Raynor W, Dhalla AH, et al. Quantitative measurements of intraocular structures and microinjection bleb volumes using intraoperative optical coherence tomography. *Biomed Opt Express*. 2023;14:352-366.

18. Romano MR, Cennamo G, Comune C, et al. Evaluation of 3D heads-up vitrectomy: Outcomes of psychometric skills testing and surgeon satisfaction. *Eye (Lond)*. 2018;32:1093-1098.

19. Reddy S, Mallikarjun K, Mohamed A, et al. Comparing clinical outcomes of macular hole surgeries performed by trainee surgeons using a 3D heads-up display viewing system versus a standard operating microscope. *Int Ophthalmol*. 2021;41:2649-2655.

20. Coppola M, La Spina C, Rabiolo A, Querques G, Bandello F. Heads-up 3D vision system for retinal detachment surgery. *Int J Retina Vitre*. 2017;3:46.

21. Rachitskaya A, Lane L, Ehlers J, DeBenedictis M, Yuan A. Argus II retinal prosthesis implantation using three-dimensional visualization system. *Retina*. 2019;39:S199-S200.

22. Kantor P, Matonti F, Varenne F, et al. Use of the heads-up NGENUITY 3D Visualization System for vitreoretinal surgery: A retrospective evaluation of outcomes in a French tertiary center. *Sci Rep*. 2021;11:10031.

23. Zhang G, Yang M, Zeng J, et al. Comparison of intravitreal injection of ranibizumab versus laser therapy for zone II treatment-requiring retinopathy of prematurity. *Retina*. 2017;37:710-717.

24. Garcia Nespola R, Yi D, Cole E, Valikodath N, Luciano C, Leiderman YI. Evaluation of Artificial Intelligence-based intraoperative guidance tools for phacoemulsification cataract surgery. *JAMA Ophthalmol*. 2022;140:170-177.


25. Nespola RG, Yi D, Cole E, Wang D, Warren A, Leiderman YI. Feature tracking and segmentation in real time via deep learning in vitreoretinal surgery: a platform for artificial intelligence-mediated surgical guidance. *Ophthalmol Retina*. 2023;7:236-242.

Reframing the discussion around geographic atrophy

Understanding the natural disease progression will help us talk to our patients about new and emerging treatments.



Amer F. Alsoudi, MD



Henry C. Skrehot, MD



Ehsan Rahimy, MD

By Amer F. Alsoudi, MD, Henry C. Skrehot, MD, and Ehsan Rahimy, MD

Take-home points

- » Recent evidence suggests that geographic atrophy progresses at a more rapid rate than previously thought.
- » The rate of GA progression is highly variable and various patient factors influence it.
- » In its more advanced stages, GA can have a profound impact on a patient's quality of life.
- » New treatment interventions to slow the GA progression rate are meeting a need and retina specialists are learning how to integrate such therapies into routine clinical practice on a case-by-case basis.

Research has emerged over the past few years that has shown that geographic atrophy progresses more rapidly than previously thought.^{1,2} That created an opportunity for early treatment, which resulted in the Food and Drug Administration earlier this year approving pegcetacoplan (Syfovre, Apellis Pharmaceuticals) for treatment of GA and then granting priority review of avacincaptad pegol (Iveric Bio), setting an action date for August.

As more treatments emerge, understanding the natural progression of GA and the baseline characteristics that predict progression will help us to choose the optimal strategy. Here, we report on recent literature into the natural progression of GA, the rate of progression, interventions to slow its progression and the ultimate implications of untreated GA.

Natural history of GA

The advanced form of age-related macular degeneration, GA progresses at a highly variable rate. Factors including baseline lesion size, lesion location, multifocality,

imaging patterns and fellow-eye status have all been implicated in predicting disease progression and outcomes.

Most of the visual loss in AMD occurs in its advanced stages, which has two typical clinical forms: GA and nAMD. GA is characterized by loss of choriocapillaris, retinal pigment epithelium and photoreceptors.³ These areas of atrophy enlarge and coalesce, creating a “geographic” lesion with sharply demarcated borders between the atrophied and normal areas of the retina.

GA usually begins parafoveally and progresses to involve the fovea. With unrelenting progression, those with unilateral GA often go on to develop lesions at a more rapid rate in the fellow eye, as early as within the first 12 months of follow-up.²

Irreversible vision loss in GA is well documented, but the relationship between GA and vision is complex because of the wide variety of lesion locations, focality and degree of foveal involvement. A 2018 review on the progression of GA didn't find strong correlations between best-corrected visual acuity and lesion enlargement, thought to

BIOS

Dr. Alsoudi is an ophthalmology resident focusing on surgical retina and ocular oncology at Baylor College of Medicine, Houston.

Dr. Skrehot is a medical student at Baylor College of Medicine.

Dr. Rahimy is a vitreoretinal specialist at Palo Alto Medical Foundation as well as an adjunct clinical assistant professor of ophthalmology at Byers Eye Institute at Stanford University, both in Palo Alto, California.

DISCLOSURES: The authors have no relevant relationships to disclose.

be due to the variable extent of foveal sparing.⁴ However, newer data from the prospective Proxima A and B clinical trials published in 2020 suggested lesion size progression is associated with a decline in vision.²

Similar levels of vision decline in patients with nonfoveal and foveal lesions have also been described, suggesting GA of any form may have devastating implications on vision.⁸ Despite the natural history of GA leading to significant loss of visual function over a two-year period even in patients with earlier disease states, limited therapeutic strategies exist to prevent its onset or progression.²

In addition to lesion characteristics in the study eye, demographic factors, health status and lesion characteristics in the fellow eye have been linked with GA progression and subsequent BCVA decline. A recent large retrospective study from the United Kingdom found the type and stage of AMD in the fellow eye affected the GA progression rate in the study eye.⁵ It also found novel associations of age, female sex and cardiovascular disease with more rapid GA progression, whereas diabetes and glaucoma were found to decrease the risk of GA progression.⁵

GA progression

Color fundus photography, fundus autofluorescence and optical coherence tomography are commonly used to assess GA lesion size and other characteristics to evaluate progression risk. The rate of progression of atrophy in the setting of AMD has been reported to be 1.5 to 2.5 mm²/year, with significant variability between individuals and even within individual patients.^{2,4,6,7} The ability to identify GA progression early and understand high-risk signs of progression improves our

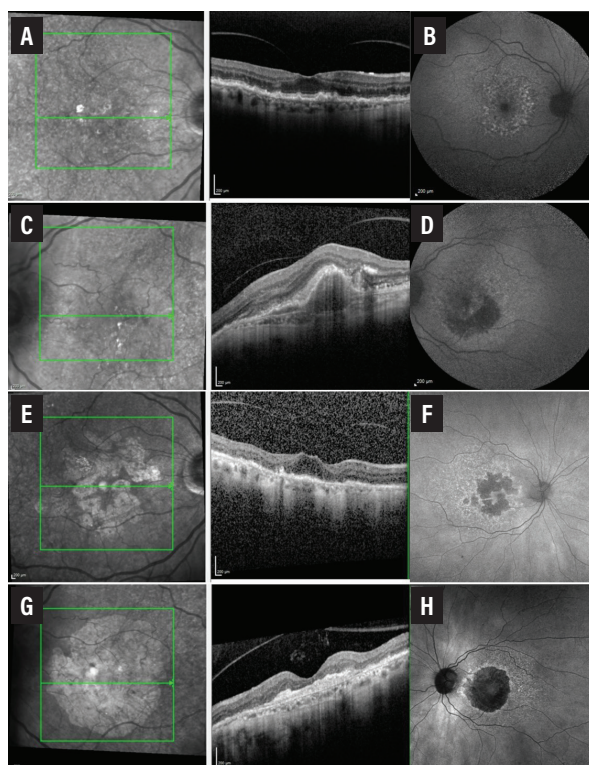


Figure 1. A through D) Spectral-domain optical coherence tomography and fundus autofluorescence of a patient initially presenting with exudative age-related macular degeneration of the left eye who was subsequently treated with anti-VEGF injections. E through H) Over the ensuing three years, the fellow right eye developed multifocal geographic atrophy encroaching near the fovea with a speckled fundus autofluorescence pattern.

understanding of the natural history of the disease, which can inform our decisions for early intervention as more treatment options become available.

Multifocal lesions, larger baseline lesion size, perilesional banded and diffuse FAF pattern as well as nonfoveal location have all been implicated in more rapid rates of GA progression (*Figure 1*). Moderate evidence supports more rapid rates of progression in patients with a history of a higher progression rate in the fellow eye and greater extent of abnormal hyperautofluorescence on FAF (*Figure 2, page 32*).⁴

More recently, an analysis using real-world data from the American Academy of Ophthalmology Intelligent Research In Sight (IRIS) registry highlighted a marked

deterioration of vision within the two years of the study, suggesting that GA may be progressing faster than previously thought.¹ This analysis also found that the time to foveal encroachment is much quicker than previous studies have reported.⁸ As reports emerge supporting the more rapid and progressive nature of GA, an increasing need for early intervention to slow or prevent GA progression to the fovea has become more apparent.

More recently, subretinal drusenoid deposits (SDDs), also commonly known as reticular pseudodrusen (RPD), have been identified as a macular risk feature that may aid in predicting GA progression in individuals with low or moderate AMD severity.⁹ RPD seemed to have a modest impact on progression. Furthermore, SDD was associated with a higher risk of progression to GA with and without other macular risk factors (*Figure 3*).

These studies have shown that accurate prognostic prediction of the GA progression risk requires several phenotypic and diagnostic markers. These findings support the new understanding of GA progression, its variability and the need for more information on the pathogenesis of GA to create more accurate prediction algorithms.

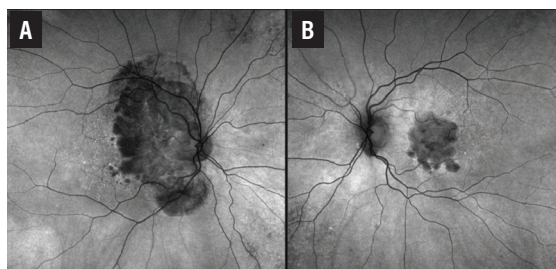


Figure 2. A) Fundus autofluorescence of a patient with advanced end-stage geographic atrophy in the right eye. B) The left eye demonstrates abnormally increased hyperautofluorescence around a central foveal GA lesion.

Interventions to slow progression

Although vascular endothelial growth factor inhibitors have been effective in treating neovascular AMD, effective GA treatments have remained an unmet need for many years. In early AMD, AREDS vitamins have demonstrated effectiveness in preventing progression to more severe AMD, but had no impact on GA specifically.¹⁰

FDA approval of pegcetacoplan came after results from the FILLY, OAKS and DERBY trials showed that the treatment reduced the rate of GA lesion growth, as measured by FAF.¹¹

Despite GA being a multifactorial and incompletely understood disease state, more recent evidence suggested that complement cascade dysfunction plays a role in its development.¹² These findings set off a race to develop complement inhibitors to target the cascade.

Pegcetacoplan, a C3 complement inhibitor that had been approved for treatment of paroxysmal nocturnal hemoglobinuria, became a front runner among other candidates when one of two large, multicenter, randomized controlled trials supported its effectiveness in slowing the progression of GA through regulating excessive activation of the complement immune system. Despite the growing evidence to support pegcetacoplan in slowing GA growth and the exciting implications of these

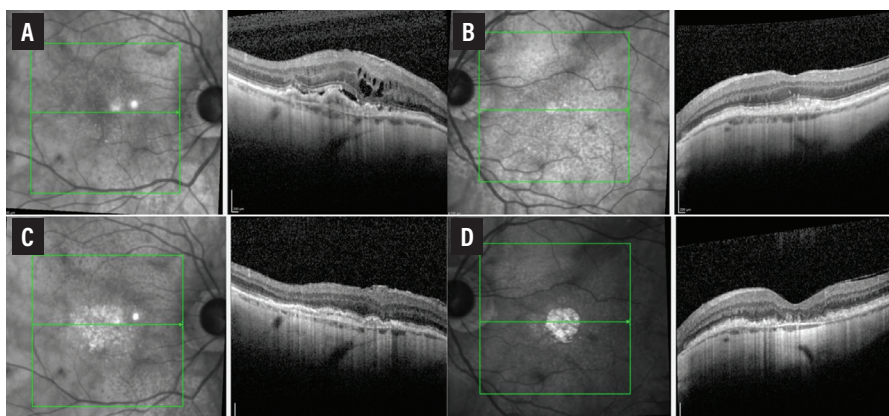


Figure 3. A, B) Spectral-domain optical coherence tomography in a patient with exudative age-related macular degeneration of the right eye and nonexudative AMD of the left eye shows subretinal drusenoid deposits. C) The right eye received treatment with anti-VEGF therapy. D) The left eye subsequently developed foveal geographic atrophy.

findings, treatment hasn't demonstrated improvement in visual function.

However, the most recent results have suggested lower vision loss and better quality of life compared to sham in a post hoc analysis.¹³ While the safety profile of pegcetacoplan is acceptable, an increased risk of developing exudative AMD in treated patients has been described.

If the prospect of pegcetacoplan wasn't already exciting enough, another agent, intravitreal avacincaptad, may be FDA-approved by the fall. Avacincaptad is a C5 complement inhibitor that demonstrated a statistically significant reduction in GA progression with a favorable safety profile, as described in the GATHER1 and GATHER2 trials.¹⁴

A robust pipeline of other drugs in earlier stages of development has shown promise (Table). These drugs mark the beginning of an effort to manage GA in ways that previously weren't possible.

Implications of untreated GA

The prevalence of GA increases with advancing age and it's a leading cause of blindness in the elderly. Without treatment, GA will inevitably progress in eyes that have it and in fellow eyes at a more rapid rate.² Patients with GA may experience difficulty with vision-related quality-of-life tasks, such as reading, driving and working. The economic burden through direct costs for treatment and indirect costs through lost productivity are substantial and expected to continue to grow without interventions to slow the progress of GA.¹⁵

Untreated GA can also have significant psychological and social impacts on patients. Visual impairment can lead to depression,

social isolation and decreased mobility, reducing overall quality of life and increasing the risk of falls and other injuries.¹⁵

Even more demoralizing for these patients has been the lack of treatment options to reverse and slow the disease's natural course. As a leading cause of blindness in the elderly in the western world and with immense negative impacts on quality of life, any validated treatment options for GA should be celebrated, even if the progress is measured in incremental steps rather than a major leap forward. While pegcetacoplan, by slowing the growth of lesions, gives new hope to patients with GA, research continues toward future therapies that can hopefully improve visual function or even prevent the onset of GA in the longer-term race against this disease.

Bottom line

Ultimately, the new understanding of the rapid, progressive nature of GA coupled with findings to support early treatment

(Continued on page 38)

Investigative and approved treatments for geographic atrophy

Product name (manufacturer)	Description	Status
ALK-001 (Alkeus Pharmaceuticals)	Oral modified vitamin A	Phase III
ANX007 (Annexon Biosciences)	Intravitreal antigen-binding fragment (Fab) to complement factor q1	Phase II
Avacincaptad pegol (Iveric bio)	C5 inhibitor	Food and Drug Administration scheduled action date
Danicopan (Alexion Pharmaceuticals)	Oral factor D inhibitor	Phase II
Elamipretide (Stealth BioTherapeutics)	Mitochondria-targeting cell-permeable peptide for subcutaneous injection	Phase II trial completed
IONIS-FB-LRx (Ionis Pharmaceuticals)	Anti-sense oligonucleotide inhibiting complement factor B	Phase II
NGM621 (NGM Biopharmaceuticals)	Humanized IgG1 monoclonal antibody inhibiting complement component 3	Phase II trial failed to meet endpoints
OpRegen (Lineage Cell Therapeutics)	Allogenic retinal pigment epithelium cells	Phase IIa
Pegcetacoplan (APL-1, Apellis)	C3 inhibitor	FDA approved
RPESC-RP-4Q (Luxa Biotechnology)	Allogeneic RPE stem cell	Phase I/IIa
Tinlarebant/LBS-008 (Belite Bio)	Oral small-molecule retinol binding protein specific antagonist	Phase III pending
Xifflam (InflamX Therapeutics)	Oral small-molecule connexin43 hemichannel blocker	Phase IIb pending

Surgical pearls from the Vit Buckle Society

Tips for pediatric and diabetic surgery, and foreign body removal, along with novel approaches for chronic macular holes and visualization in endophthalmitis.

Edited by Yoshihiro
Yonekawa, MD



The 11th Vit Buckle Society annual meeting in Las Vegas, Nevada, brought engaging, informative and spirited surgical discussion to the stage by a host of expert surgeons. Here, we provide summaries of five standout surgical talks.

Pediatric retina surgery tips

By Hong-Uyen Hua, MD



Dr. Hua is a second-year vitreoretinal surgery fellow at the Cleveland Clinic Cole Eye Institute.

DISCLOSURE: Dr. Hua disclosed relationships with Alimera Sciences, AbbVie/Allergan and Genentech/ Roche.



Pediatric retina surgery can be intimidating, but J. Peter Campbell, MD, distilled a few basic principles for these potentially challenging operations. Dr. Campbell is the Edwin and Josephine Knowles Professor at Casey Eye Institute at Oregon Health and Science University in Portland.¹

He elucidated essentials for fixing pediatric tractional retinal detachments: an understanding of the anatomy; and to get out of the eye as quickly and as safely as possible

after achieving the surgical goal. Dr. Campbell demonstrated these principles with a few surgical case studies.

In a 6-month-old with a history of abusive head trauma, examination demonstrated a limited view of the retina (Figure 1A). Subinternal limiting membrane hemorrhage was noted to be encompassing the macula and most of the posterior retina (Figure 1B). Clearing the sub-ILM hemorrhage involved removing the anterior-posterior traction 360 degrees around the hemorrhage as well as in the sub-ILM space without creating a break.

In another case, Dr. Campbell reported on an ex-26-week premature baby presenting as a near 40-week old baby with retinopathy of prematurity with continued progression after laser treatment. Exam under anesthesia revealed stage 4 retinal detachments (Figure 2A). Fluorescein angiography revealed a fibrovascular membrane with leakage at the disc and arcades (Figure 2B).

In this scenario, Dr. Campbell emphasized not to rush into a hot, active eye. The baby was given bilateral intravitreal bevacizumab. Neovascularization and tractional schisis resolved in the left eye with just intravitreal bevacizumab and panretinal

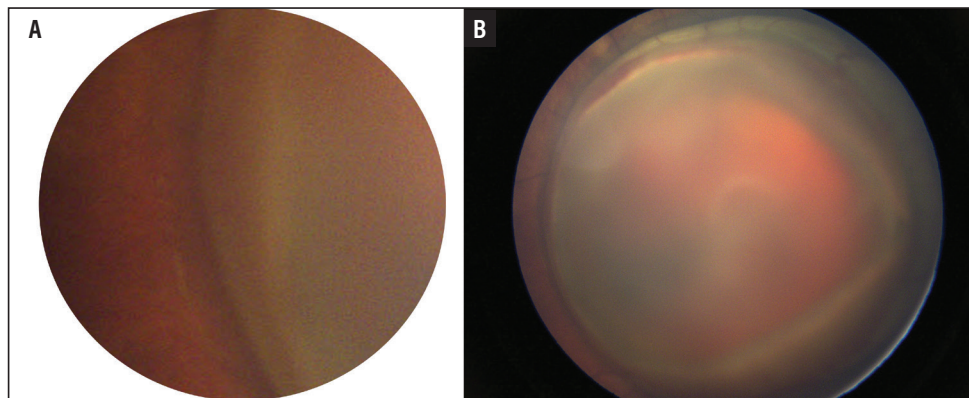


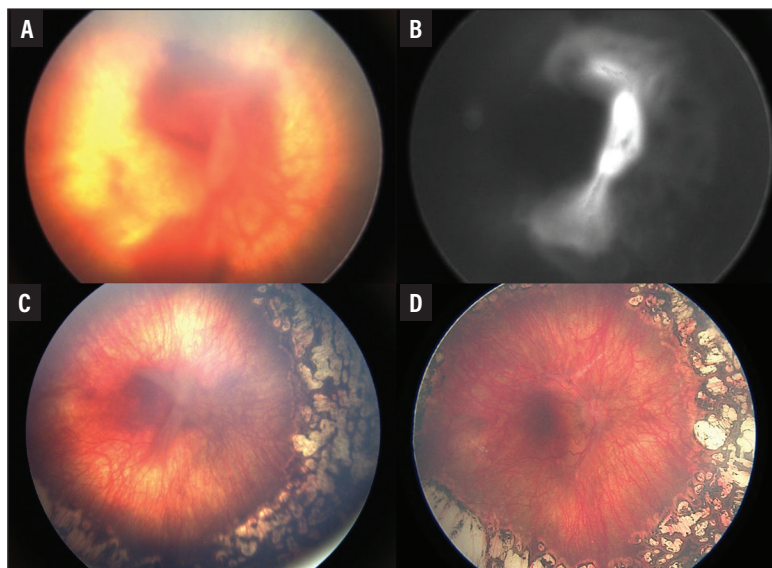
Figure 1. A) Fundus photo of a 6-month-old baby with a history of abusive head trauma demonstrates a limited view of the retina. B) A subinternal limiting membrane hemorrhage encompasses the macula and most of the posterior retina.

BIOS

Dr. Yonekawa is an adult and pediatric retina specialist at Wills Eye Hospital/Mid Atlantic Retina, Philadelphia.

DISCLOSURE: Dr. Yonekawa is a consultant for Alcon, Bausch Health, EyePoint Pharmaceuticals, Regeneron Pharmaceuticals and Versant Health.

Figure 2. Widefield fundus imaging of the right eye in a former 26-week-old premature baby with retinopathy of prematurity. A) The right eye shows stage 4 ROP. B) Fluorescein angiography shows leakage from the disc extending to the arcades. C) Vascular activity has decreased after an intravitreal bevacizumab injection, but the tractional retinal detachment persists as folds. D) The nicely flattened retina after lens-sparing vitrectomy with membrane peeling.



photocoagulation.

The right eye required a lens-sparing vitrectomy (Figure 2C). Selective areas of anterior-posterior traction were gently released without causing iatrogenic breaks with aggressive maneuvers. The enemy of good is better: Don't aim for perfection, and get out of the eye safely. The patient achieved an excellent anatomic result with a flat retina three years out from surgery (Figure 2D).

Amniotic membrane graft for chronic macular holes

By Suzanne Michalak, MD



Dr. Michalak is a second-year vitreoretinal surgery fellow at Byers Eye Institute, Stanford University, Palo Alto, California.

DISCLOSURES: Dr. Michalak serves on an advisory board for AbbVie/Allergan.



Rachel Mogil, MD, a second-year vitreoretinal surgery fellow at the Mayo Clinic, Rochester, Minn., presented a novel technique developed alongside Raymond Iezzi, MD, for closure of chronic macular holes following previous surgical failure with vitrectomy, ILM peeling and gas.² The premise is to leave an amniotic membrane patch graft covering the hole under silicone oil for three months.

The technique involves first inserting the standard three 23-gauge trocar ports and then a chandelier system. The next step is to ensure a complete vitrectomy has been performed previously with careful shaving of the vitreous base. The ILM is then stained with ICG, and any prior ILM peel extended to the arcades. Restaining

confirms ILM removal.

A corneal trephine is then used to size the amniotic membrane outside the eye. The amniotic membrane is then inserted into the eye through one of the 23-g cannulae using a 25-g forceps. A second forceps is used to unfurl the patch and to identify the chorion (sticky) side, which tends to scroll into itself and stick to the forceps.

Using a bimanual technique, the amniotic membrane is placed over the macular hole, chorion side down. Perfluoro-octane is injected onto the patch to stabilize it. Direct PFO/silicone oil exchange is then performed and intraoperative optical coherence tomography helps to confirm positioning and complete amniotic membrane graft coverage of the hole. The cannulae are removed and sclerotomies sutured.


Three months later, the team returns to remove the silicone oil and amniotic membrane. The results from the case presented were quite impressive for a chronic macular hole. Preoperative vision was 20/600 and vision three months following silicone oil/graft removal was 20/40. They plan an upcoming case series detailing more patients in whom this technique has been used successfully for chronic macular holes.

(continued on page 38)

The results using amniotic membrane graft for a case of chronic macular hole were quite impressive. Preoperative vision was 20/600 and vision three months following silicone oil/graft removal was 20/40.

Pearls for retinal surgery in patients with diabetes

By Abtin Shahlaee, MD



Dr. Shahlaee is a second-year vitreoretinal surgery fellow at Wills Eye Hospital/Mid Atlantic Retina in Philadelphia.

DISCLOSURE: Dr. Shahlaee has no relevant disclosures.



Irene Roh, MD, a vitreoretinal surgeon at Joslin Diabetes Center/Beetham Eye Institute in Boston, shared these pearls for optimizing surgical outcomes in patients with diabetic retinopathy.³

- **Preoperative evaluation.** Establish goals for surgery, including an estimation of visual potential as guided by your preoperative examination and, possibly, fluorescein angiography or OCT angiography. For example, evaluating the hyaloid status allows you to determine the optimal location to begin membrane dissection, specifically targeting the area where the separation between the posterior hyaloid and the underlying retinal surface is most pronounced.

- **Handle the hyaloid.** The initial stages of diabetic vitrectomy typically involve addressing anterior-to-posterior traction and detaching and removing the posterior hyaloid. Releasing the hyaloid establishes the appropriate surgical plane, facilitating the removal of fibrovascular membranes.

By utilizing small-gauge instruments and intraocular forceps, the dissection of membranes becomes more precise, enabling improved access to the membranes and potential space. Regardless of the perceived difficulty or inoperability of a tractional retinal detachment (TRD), a disciplined approach can lead to successful outcomes.

- **Improve your view.** Clear visualization is of utmost importance, particularly when dealing with complex dissections and lengthy surgical procedures. Patients with diabetes often have friable corneal epithelium, so use the appropriate vis-

coelastic agents. For phakic patients, incorporating dextrose into the balanced salt solution infusion can minimize lens opacity during the operation. In more advanced cataracts, consider simultaneous cataract extraction to ensure a clear view for vitrectomy.

- **Control bleeding.** Early and consistent hemostasis is crucial. Prolonged and uncontrolled bleeding can obscure the surgical view. The formation of pseudomembranes due to coagulated blood can further complicate membrane dissection. While elevating the intraocular pressure can be helpful, Dr. Roh recommended diathermy or long-duration endolaser to address the underlying cause of bleeding. Prolonged pressure can lead to premature corneal edema, worsening of ischemia and optic neuropathy.

- **Intravitreal triamcinolone.** This can aid in visualizing vitreoschisis and removing the hyaloid.

- **It's not just about the surgery.** Postoperatively, patients need close monitoring to evaluate for further DR complications, such as recurrent neovascularization, vitreous hemorrhage, macular edema, retinal redetachments, proliferative vitreoretinopathy and cataract and epiretinal membrane formation.

US-guided vitrectomy: A solution to the dreaded 'blind vitrectomy'

By Margaret M. Runner, MD



Dr. Runner is a second-year vitreoretinal surgery fellow with Associated Retinal Consultants at Beaumont Hospital in Royal Oak, Mich.

DISCLOSURE: Dr. Runner disclosed relationships with Alimera Sciences and AbbVie/Allergan.



Raul Velez-Montoya, MD, presented a novel technique for using intraoperative B-scan ultrasonography to guide vitrectomy in eyes with infectious keratitis endophthalmitis.⁴ Patients with advanced endophthalmitis (*Figure 3*) may present

When operating on patients with diabetes, establish goals for surgery, including an estimation of visual potential as guided by your preoperative examination and, possibly, fluorescein angiography or OCT angiography.

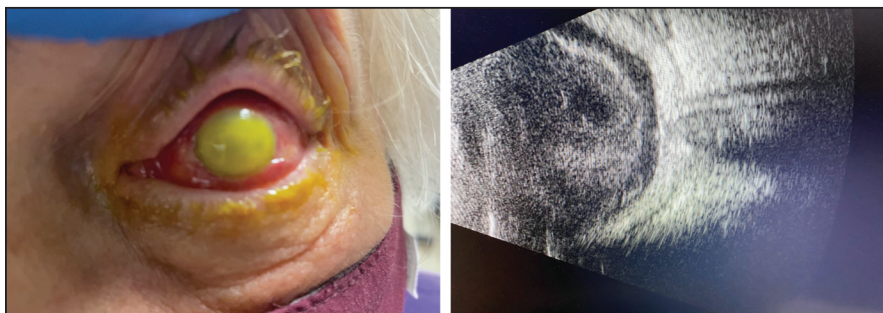

Figure 3. External photograph and B-scan ultrasonography of a 71-year-old male patient who presented two days after intravitreal aflibercept injection with corneal opacification and dense vitritis. Baseline vision was light perception with minimal improvement after intravitreal antibiotics and topical therapy, therefore patient underwent surgery two days after presentation. Vitreous cultures ultimately grew *Streptococcus mitis*.

with light perception vision or worse with minimal improvement after intravitreal antibiotics and aggressive topical therapy, thus prompting surgeons to consider vitrectomy.

Despite anterior chamber wash-outs, synechiolysis or corneal scraping, the view to the posterior pole can still be limited. To address this issue, Dr. Velez-Montoya, of the Association to Avoid Blindness in Mexico in Mexico City, demonstrated a technique utilizing intraoperative B-scan ultrasonography to visualize the cutter tip in relation to the eye wall. By holding in one hand the B-scan probe, protected in a sterile sleeve, and in the other the vitreous cutter, the surgeon can visualize the cutter on the monitor as a bright hyperechoic signal with posterior shadowing.

This technique may facilitate limited vitrectomy in challenging cases where there's no view to the posterior pole, when endoscopes may not be available and/or temporary keratoprotheses (TKP) may be contraindicated. Dr. Velez-Montoya confirmed that standard stainless-steel vitrectomy cannulae don't cause excessive internal echo noise to interfere with visualization by the probe. He recommended the standard 10-Mhz B-scan probe for visualization of intraocular landmarks.

Once the vitreous cutter's bright echo is visualized and in a good location, the foot pedal is engaged and the cutter left in place until there's no further movement of vitreous toward the cutter on the monitor. The procedure is repeated several times in different projections to safely remove the

maximum amount of vitreous.

To test this technique, Dr. Velez-Montoya enrolled patients with infectious keratitis endophthalmitis needing a PPV who weren't candidates for TKP. Baseline visual acuity was 2.3 ± 0.25 logMAR (light perception) and preoperative ultrasound showed attached retina. Case duration was on average 25 minutes and all patients received intravitreal vancomycin/ceftazidime at the end.

Eight patients (66 percent) achieved endophthalmitis inactivation, two ultimately required evisceration due to uncontrolled infection, and two developed retinal detachment at post-op weeks six and eight. Visual acuity at three months post-op had improved to 2.1 ± 0.25 logMAR (hand motions) in this small cohort. The adverse events during follow-up were likely related more to the severity of the endophthalmitis rather than the ultrasound-guided vitrectomy. Although further studies are needed, this approach is a feasible alternative to visualize the position of the vitreous cutter rather than using the traditional "blind vitrectomy" for severe active endophthalmitis cases.

Tips for intraocular foreign body removal

By Thomas Lazzarini, MD



Dr. Lazzarini is a second-year vitreoretinal surgery fellow at Bascom Palmer Eye Institute, University of Miami.

DISCLOSURE: Dr. Lazzarini is a consultant to Regenxbio.

(continued on page 38)

Although further study is needed, ultrasound-guided vitrectomy is a feasible alternative to visualize the position of the vitreous cutter rather than using the traditional "blind vitrectomy" for severe active endophthalmitis cases.



Vivek Dave, MD, used several cases to highlight practical surgical tips on the management of intraocular foreign bodies (IOFB) in ruptured globe injuries.⁵ IOFBs can be contained to the anterior segment or localized to the posterior segment following scleral injury or a corneal injury with lens or zonular violation.

In his first case, Dr. Dave, of the Anant Bajaj Retina Institute, LV Prasad Eye Institute in Hyderabad, India, reported on a patient with a corneal laceration and a retained metallic posterior-segment IOFB. Anterior-chamber and vitreous hemorrhage prevented visualization to the posterior segment. In such cases, a front-to-back approach is prudent to clear media in a step-wise fashion to safely enter the posterior segment and retrieve the foreign body.

First, an anterior chamber wash-out with the placement of an anterior infusion clears the hemorrhage and hyphema. A complete lensectomy via phacoemulsification or phaco-fragmentation follows. The anterior chamber infusion may improve the vitreous hemorrhage in the anterior vitreous.

Once posterior visualization is established, a posterior vitreous detachment is induced prior to IOFB retrieval to minimize vitreous traction and to reduce the risk of subsequent retinal detachment. PFO can prevent iatrogenic macular damage from the IOFB, which may fall posteriorly during removal.

An intraocular magnet is a good tool for removing metallic foreign bodies. Other options include intraocular forceps or aspiration with a cannula. With standard intraocular forceps, such as ILM forceps, the prongs may be spread manually for a larger foreign body. In aphakic

patients, the IOFB may be removed via a scleral tunnel or clear corneal wound, or via an enlarged, circumferential pars plana incision regardless of the lens status.

If a retinal detachment is identified, additional PFO may stabilize the retina during IOFB removal. Once the foreign bodies are removed, PFO may be brought up to drain the retina flat via a peripheral break or retinotomy. At this point, a direct PFO/silicone oil exchange or a fluid-air exchange is performed, followed by a gas or silicone oil tamponade, with the latter favored. All breaks should be lasered. A 360-degree peripheral laser can be considered given the possibility of missed or microscopic breaks in the setting of severe trauma.

Dr. Dave's second case demonstrated a technique for identifying foreign bodies hidden in the anterior chamber angle. The patient had inferior corneal edema and a self-sealing corneal laceration after an accident involving broken glass. A foreign body was suspected but couldn't be visualized because of the corneal edema.

In the operating room, the anterior chamber was filled with Healon, which also inflated the inferior angle. An endoscope helped visualize the angle, revealing a small piece of glass. Forceps were used to grasp and remove the glass through a limbal corneal wound. The corneal edema subsequently improved. ^{RS}

REFERENCES

- Campbell JP. Pediatric retina surgery tips. Paper presented at Vit Buckle Society; April 14, 2023; Las Vegas, NV.
- Mogil R, Iezzi R. Paper presented at Vit Buckle Society; April 14, 2023; Las Vegas, NV.
- Roh I. Pearls for diabetic surgery. Paper presented at Vit Buckle Society; April 14, 2023; Las Vegas, NV.
- Montoya RV. Session 9: International Surgical Retina "With Great Powre Comes Great Resonsibility." Paper presented at Vit Buckle Society; April 15, 2023; Las Vegas, NV.
- Dave V. Intraocular foreign bodies—the extreme ones! Paper presented at Vit Buckle Society; April 14, 2023; Las Vegas, NV.

Reframing GA discussion (Continued from page 33)

options has provided a glimmer of hope, but still leaves much to be desired in the effort to develop additional treatment strategies to slow or even prevent GA progression. Pegcetacoplan is an important first step in treatment for patients with advanced atrophic AMD. A discussion with our patients who have advanced atrophic AMD should address the need for repeated treatments, drug efficacy and safety signals. ^{RS}

REFERENCES

- Rahimy E, Khan MA, Ho AC, et al. Progression of geographic atrophy: Retrospective analysis of patients from the IRIS Registry. *Ophthalmol Sci*. Published online April 19, 2023;100318. doi:10.1016/j.jxops.2023.100318.
- Holekamp N, Wykoff CC, Schmitz-Valckenberg S, et al. Natural history of geographic atrophy secondary to age-related macular degeneration: results from the prospective Proxima A and B clinical trials. *Ophthalmology*. 2020;127:769-783.
- Sarks JP, Sarks SH, Killingsworth MC. Evolution of geographic atrophy of the retinal pigment epithelium. *Eye (Lond)*. 1988;2:552-577.
- Fleckenstein M, Mitchell P, Freund KB, et al. The progression of geographic atrophy secondary to age-related macular degeneration. *Ophthalmology*. 2018;125:369-390.
- Chakravarthy U, Bailey CC, Scanlon PH, et al. Progression from early/intermediate to advanced forms of age-related macular degeneration in a large UK Cohort: Rates and risk factors. *Ophthalmol Retina*. 2020;4:662-672.
- Holz FG, Bindowald-Wittich A, Fleckenstein M, et al. Progression of geographic atrophy and impact of fundus autofluorescence patterns in age-related macular degeneration. *Am J Ophthalmol*. 2007;143:463-472.
- Sunness JS, Margalit E, Srikanth D, et al. The long-term natural history of geographic atrophy from age-related macular degeneration: enlargement of atrophy and implications for interventional clinical trials. *Ophthalmology*. 2007;114:271-277.
- Lindblad AS, Lloyd PC, Clemons TE, et al. Change in area of geographic atrophy in the Age-Related Eye Disease Study: AREDS report number 26. *Arch Ophthalmol*. 2009;127:1168-1174.
- Agrón E, Domalpally A, Cukras CA, et al. Reticular pseudodrusen: The third macular risk feature for progression to late age-related macular degeneration: Age-Related Eye Disease Study 2 Report 30. *Ophthalmology*. 2022;129:1107-1119.
- Chew EY, Clemons TE, Agrón E, et al. Long-term outcomes of adding lutein/zeaxanthin and ω-3 fatty acids to the AREDS supplements on age-related macular degeneration progression: AREDS2 Report 28. *JAMA Ophthalmol*. 2022;140:692-698.
- Nittala MG, Metlapally R, Ip M, et al. Association of pegcetacoplan with progression of incomplete retinal pigment epithelium and outer retinal atrophy in age-related macular degeneration: A post hoc analysis of the FILLY randomized clinical trial. *JAMA Ophthalmol*. 2022;140:243-249.
- Boyer DS, Schmidt-Erfurth U, van Lookeren Campagne M, Henry EC, Brittain C. The pathophysiology of geographic atrophy secondary to age-related macular degeneration and the complement pathway as a therapeutic target. *Retina*. 2017;37:819-835.
- Apellis presents Phase 3 functional analyses of Syfovretm (pegcetacoplan injection) for geographic atrophy [press release. Waltham, MA: Apellis Pharmaceuticals; May 28, 2023. <https://investors.apellis.com/news-releases/news-release-details/apellis-presents-phase-3-functional-analyses-syfovretm>.
- Jaffe GJ, Westby K, Csaky KG, et al. C5 Inhibitor avacincaptad pegol for geographic atrophy due to age-related macular degeneration: A randomized pivotal Phase 2/3 trial. *Ophthalmology*. 2021;128:576-586.
- Sarda SP, Heyes A, Bektas M, et al. Humanistic and economic burden of geographic atrophy: A systematic literature review. *Clin Ophthalmol*. 2021;15:4629-4644.



Potential of low-light therapy for dry AMD

Trial shows effectiveness of the Valeda Light Delivery System photobiomodulation platform.

Photobiomodulation is a novel concept in treating retinal disease. It involves using a device to deliver low-level light to specific areas of the retina to stimulate cellular response. Two investigative devices are evaluating this concept: Valeda Light Delivery System (LumiThera) and Retilux (PhotoOpTx).

The Valeda device has been the subject of 24-month results from the LIGHTSITE III trial in patients with dry age-related macular degeneration.¹ The study reported minimal safety risks and high compliance. More than 80 percent of patients completed the trial.

In the LIGHTSITE III trial, treated patients also had statistically significant improvement in best-corrected visual acuity. Thirteen-month results reported that more than half of treated eyes had a more than 5-letter gain in best-corrected visual acuity. The 24-month results paralleled those findings.

The technology is already approved in Europe and South America for treatment of dry AMD, with an additional indication for diabetic macular edema in Europe. LumiThera reports that more than 9,000 patients worldwide have received the treatment.

Here, Eleonora M. Lad, MD, PhD, vice chair of ophthalmology at Duke University Medical Center in Durham, N.C., answers questions about the Valeda device and the LIGHTSITE III trial. Dr. Lad is a trial investigator and a member of LumiThera's scientific advisory board.

Q What is photobiomodulation (PBM) and how does the Valeda device work?

A PBM uses low-light at specific wavelengths to stimulate healthful cellular function. It has been used in other specialties besides ophthalmology, including physical therapy, rheumatology for arthritis, cardiol-

ogy and sports medicine, and it has been used in wound repair.

Valeda uses three specific wavelengths: 590, 660 and 850 nm. Each has a specific role in the cells they target. They are:

- 590 nm inhibits vascular endothelial growth factor expression and removes cellular deposits.
- 660 nm promotes oxygen binding and stimulates adenosine triphosphate (ATP), which inhibits inflammation and cellular loss.
- 850 nm stimulates metabolic activity as well as ATP, inhibits inflammation cellular loss and drives electron transfer.

Q What can you tell us about the LIGHTSITE III Trial design?

A LIGHTSITE III enrolled subjects with dry AMD with BCVA of 20/30 to 20/100 (n=100; 148 eyes). Average age was 75 years and the mean diagnosis was 4.9 years. The double-masked, control trial randomized patients 2:1 to PBM or active sham, which was a low-dose treatment of 50 to 100 times less than the two lowest doses.

Q What was the take-home from the 24-month results?

A The trial met the primary endpoint of BCVA improvement with a statistically significant difference between the treatment and sham groups. The results showed a sustained mean increase of >5 letters from baseline at both the 13 and 21 months. The improvement from baseline to 24 months was 5.9 letters vs. 1 letter for sham.

The treatment also demonstrated safety. No signs of phototoxicity or other side effects were reported through 24 months.

Q What other notable results did the trial produce?

A Another key finding was that 58 percent of the PBM-treated eyes had

With Eleonora Lad, MD, PhD



BIO

Dr. Lad is the vice chair of ophthalmology at Duke University Medical Center in Durham, N.C.

DISCLOSURE: Dr. Lad is an investigator for LumiThera and is a member of its scientific advisory board.

>5-letter gain, with a mean of 8.5 letters gained.

Also, a detailed morphology analysis using optical coherence tomography showed that fewer treated eyes developed geographic atrophy compared with sham: 5.7 percent (5:88) vs. 21.6 percent (11:51). That was statistically significant ($p=0.003$).

Additionally, 26.5 percent of PBM patients gained >10 letters and a small number of them, 5.5 percent, had a >15-letter improvement in BCVA vs. 1.9 percent of sham.


Q What types of dry AMD patients would be best suited for PBM?

A Those analyses are ongoing. It's important that more than 55 percent of eyes had a >5-letter gain because that's not the natural progression of this disease. Typically these eyes lost 2 to 3 letters per year. The natural history studies have been consistent on that. We would love to understand who those patients are who gain >5 letters, and who are the patients who gain >10 or even 15 letters.

Our reading center at Duke University and other collaborators are evaluating the OCT characteristics of these patients to identify structural features that will help us predict who might have the best and worst response to this treatment.

Ultimately, this may be helpful in the retina specialist's armamentarium to use in conjunction with the anti-complement therapeutics, such as pegcetacoplan (Syfovre, Apellis Pharmaceuticals) and avacincaptad pegol (Iveric Bio), for treating dry AMD and GA.

Q What are the next steps in the development of Valeda?

A The company will submit the 24-month results to the Food and Drug Administration for approval. LumiThera is also pursuing a holistic approach to AMD management with its acquisition of the AdaptDx Pro dark adaptation testing platform for early monitoring of AMD and the Diopsys electroretinography and visual evoked potential systems for evaluating the visual pathway. Another possibility is pursuing an additional indication for DME at some point. 

REFERENCE

1. Munk MR, Gonzalez V, Boyer DS, et al. LIGHTSITE III 24-month analysis: Evaluation of multiwavelength photobiomodulation in dry age-related macular degeneration using the LumiThera Valeda Light Delivery System. *Invest Ophthalmol Vis Sci.* 2023;64:5059.



**Support the Education
of Future Healthcare &
Eyecare Professionals**

**THE RICK BAY
FOUNDATION**

for Excellence in Eyecare Education

Scholarships are awarded to advance the education of students in both **Optometry** and **Ophthalmology**, and are chosen by their school based on qualities that embody Rick's commitment to the profession, including integrity, compassion, partnership and dedication to the greater good.

**INTERESTED IN BEING
A PARTNER WITH US?**

www.rickbayfoundation.org

(Contributions are tax-deductible in accordance with section 170 of the Internal Revenue Code.)

ABOUT RICK

Rick Bay served as the publisher of *The Review Group* for more than 20 years.

To those who worked for him, he was a leader whose essence was based in a fierce and boundless loyalty.

To those in the industry and the professions he served, he will be remembered for his unique array of skills and for his dedication to exceeding the expectations of his customers, making many of them fast friends.



THE RICK BAY FOUNDATION
for Excellence in Eyecare Education

(The Rick Bay Foundation for Excellence in Eyecare Education is a nonprofit, tax-exempt organization under section 501(c)(3) of the Internal Revenue Code.)

SYFOVRE™ (pegcetacoplan injection), for intravitreal use
BRIEF SUMMARY OF PRESCRIBING INFORMATION
Please see SYFOVRE full Prescribing Information for details.

INDICATIONS AND USAGE

SYFOVRE is indicated for the treatment of geographic atrophy (GA) secondary to age-related macular degeneration (AMD).

CONTRAINDICATIONS

Ocular or Periocular Infections

SYFOVRE is contraindicated in patients with ocular or periocular infections.

Active Intraocular Inflammation

SYFOVRE is contraindicated in patients with active intraocular inflammation.

WARNINGS AND PRECAUTIONS

Endophthalmitis and Retinal Detachments

Intravitreal injections, including those with SYFOVRE, may be associated with endophthalmitis and retinal detachments. Proper aseptic injection technique must always be used when administering SYFOVRE in order to minimize the risk of endophthalmitis. Patients should be instructed to report any symptoms suggestive of endophthalmitis or retinal detachment without delay and should be managed appropriately.

Neovascular AMD

In clinical trials, use of SYFOVRE was associated with increased rates of neovascular (wet) AMD or choroidal neovascularization (12% when administered monthly, 7% when administered every other month and 3% in the control group) by Month 24. Patients receiving SYFOVRE should be monitored for signs of neovascular AMD. In case anti-Vascular Endothelial Growth Factor (anti-VEGF) is required, it should be given separately from SYFOVRE administration.

Intraocular Inflammation

In clinical trials, use of SYFOVRE was associated with episodes of intraocular inflammation including: vitritis, vitreal cells, iridocyclitis, uveitis, anterior chamber cells, iritis, and anterior chamber flare. After inflammation resolves patients may resume treatment with SYFOVRE.

Increased Intraocular Pressure

Acute increase in IOP may occur within minutes of any intravitreal injection, including with SYFOVRE. Perfusion of the optic nerve head should be monitored following the injection and managed as needed.

ADVERSE REACTIONS

Clinical Trials Experience

Because clinical trials are conducted under widely varying conditions, adverse reaction rates observed in the clinical trials of a drug cannot be directly compared to rates in the clinical trials of another drug and may not reflect the rates observed in practice.

A total of 839 patients with GA in two Phase 3 studies (OAKS and DERBY) were treated with intravitreal SYFOVRE, 15 mg (0.1 mL of 150 mg/mL solution). Four hundred nineteen (419) of these patients were treated in the affected eye monthly and 420 were treated in the affected eye every other month. Four hundred seventeen (417) patients were assigned to sham. The most common adverse reactions ($\geq 5\%$) reported in patients receiving SYFOVRE were ocular discomfort, neovascular age-related macular degeneration, vitreous floaters, and conjunctival hemorrhage.

Table 1: Adverse Reactions in Study Eye Reported in $\geq 2\%$ of Patients Treated with SYFOVRE Through Month 24 in Studies OAKS and DERBY

Adverse Reactions	PM (N = 419) %	PEOM (N = 420) %	Sham Pooled (N = 417) %
Ocular discomfort*	13	10	11
Neovascular age-related macular degeneration*	12	7	3
Vitreous floaters	10	7	1
Conjunctival hemorrhage	8	8	4
Vitreous detachment	4	6	3
Retinal hemorrhage	4	5	3
Punctate keratitis*	5	3	<1
Posterior capsule opacification	4	4	3
Intraocular inflammation*	4	2	<1
Intraocular pressure increased	2	3	<1

PM: SYFOVRE monthly; PEOM: SYFOVRE every other month

*The following reported terms were combined:

Ocular discomfort included: eye pain, eye irritation, foreign body sensation in eyes, ocular discomfort, abnormal sensation in eye

Neovascular age-related macular degeneration included: exudative age-related macular degeneration, choroidal neovascularization

Punctate keratitis included: punctate keratitis, keratitis

Intraocular inflammation included: vitritis, vitreal cells, iridocyclitis, uveitis, anterior chamber cells, iritis, anterior chamber flare

Endophthalmitis, retinal detachment, hyphema and retinal tears were reported in less than 1% of patients. Optic ischemic neuropathy was reported in 1.7% of patients treated monthly, 0.2% of patients treated every other month and 0.0% of patients assigned to sham. Deaths were reported in 6.7% of patients treated monthly, 3.6% of patients treated every other month and 3.8% of patients assigned to sham. The rates and causes of death were consistent with the elderly study population.

USE IN SPECIFIC POPULATIONS

Pregnancy

Risk Summary

There are no adequate and well-controlled studies of SYFOVRE administration in pregnant women to inform a drug-associated risk. The use of SYFOVRE may be considered following an assessment of the risks and benefits.

Systemic exposure of SYFOVRE following ocular administration is low. Subcutaneous administration of pegcetacoplan to pregnant monkeys from the mid gestation period through birth resulted in increased incidences of abortions and stillbirths at systemic exposures 1040-fold higher than that observed in humans at the maximum recommended human ophthalmic dose (MRHOD) of SYFOVRE (based on the area under the curve (AUC) systemically measured levels). No adverse maternal or fetal effects were observed in monkeys at systemic exposures approximately 470-fold higher than that observed in humans at the MRHOD.

In the U.S. general population, the estimated background risk of major birth defects and miscarriage in clinically recognized pregnancies is 2-4% and 15-20%, respectively.

Lactation

Risk Summary

It is not known whether intravitreal administered pegcetacoplan is secreted in human milk or whether there is potential for absorption and harm to the infant. Animal data suggest that the risk of clinically relevant exposure to the infant following maternal intravitreal treatment is minimal. Because many drugs are excreted in human milk, and because the potential for absorption and harm to infant growth and development exists, caution should be exercised when SYFOVRE is administered to a nursing woman.

Females and Males of Reproductive Potential

Contraception

Females: It is recommended that women of childbearing potential use effective contraception methods to prevent pregnancy during treatment with intravitreal pegcetacoplan. Advise female patients of reproductive potential to use effective contraception during treatment with SYFOVRE and for 40 days after the last dose. For women planning to become pregnant, the use of SYFOVRE may be considered following an assessment of the risks and benefits.

Pediatric Use

The safety and effectiveness of SYFOVRE in pediatric patients have not been established.

Geriatric Use

In clinical studies, approximately 97% (813/839) of patients randomized to treatment with SYFOVRE were ≥ 65 years of age and approximately 72% (607/839) were ≥ 75 years of age. No significant differences in efficacy or safety were seen with increasing age in these studies. No dosage regimen adjustment is recommended based on age.

PATIENT COUNSELING INFORMATION

Advise patients that following SYFOVRE administration, patients are at risk of developing neovascular AMD, endophthalmitis, and retinal detachments. If the eye becomes red, sensitive to light, painful, or if a patient develops any change in vision such as flashing lights, blurred vision or metamorphopsia, instruct the patient to seek immediate care from an ophthalmologist.

Patients may experience temporary visual disturbances associated either with the intravitreal injection with SYFOVRE or the eye examination. Advise patients not to drive or use machinery until visual function has recovered sufficiently.

Manufactured for:
Apellis Pharmaceuticals, Inc.
100 Fifth Avenue
Waltham, MA 02451

SYF-PI-17Feb2023-1.0

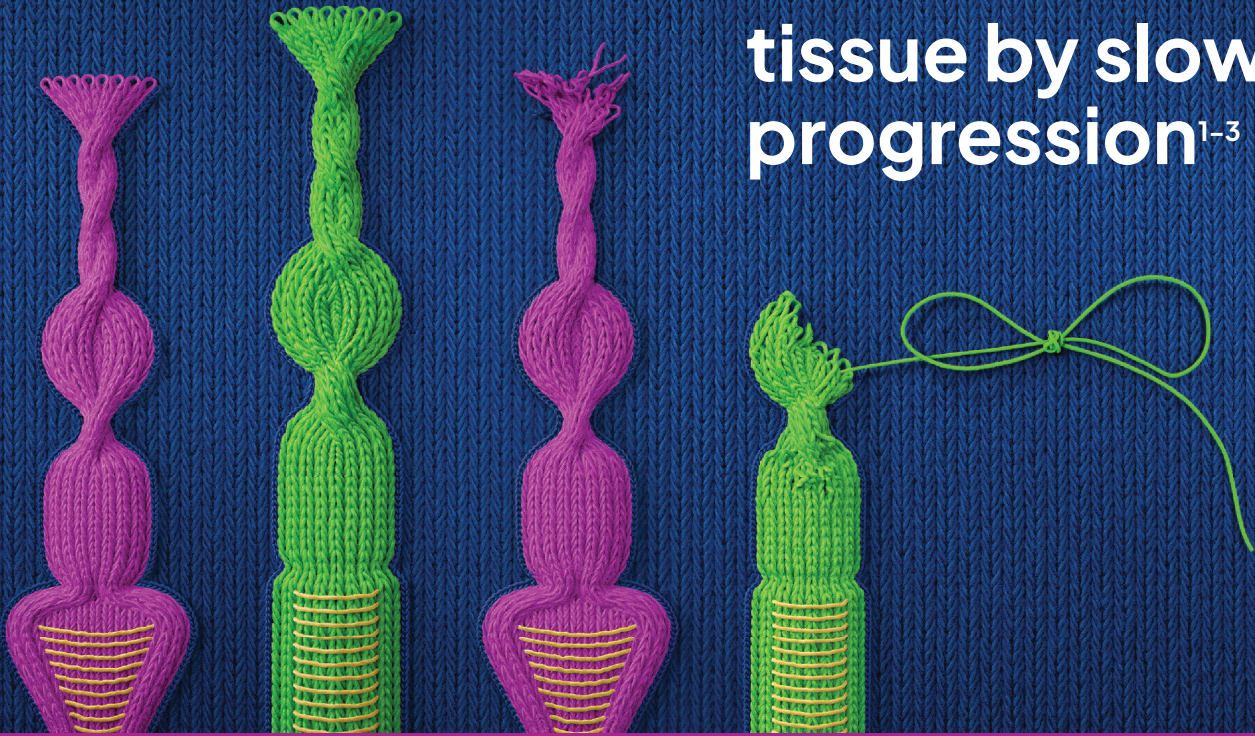APELLIS®, SYFOVRE™ and their respective logos are registered trademarks and/or trademarks of Apellis Pharmaceuticals, Inc.
©2023, Apellis Pharmaceuticals, Inc.

2/23 US-PEGGA-2200163 v2.0

NOW APPROVED: the first and only
FDA-approved treatment for GA
secondary to AMD¹

GA unravels so much

**Save retinal
tissue by slowing
progression¹⁻³**



INDICATION

SYFOVRE™ (pegcetacoplan injection) is indicated for the treatment of geographic atrophy (GA) secondary to age-related macular degeneration (AMD).

IMPORTANT SAFETY INFORMATION

CONTRAINDICATIONS

- SYFOVRE is contraindicated in patients with ocular or periocular infections, and in patients with active intraocular inflammation

WARNINGS AND PRECAUTIONS

● Endophthalmitis and Retinal Detachments

- Intravitreal injections, including those with SYFOVRE, may be associated with endophthalmitis and retinal detachments. Proper aseptic injection technique must always be used when administering SYFOVRE to minimize the risk of endophthalmitis. Patients should be instructed to report any symptoms suggestive of endophthalmitis or retinal detachment without delay and should be managed appropriately.

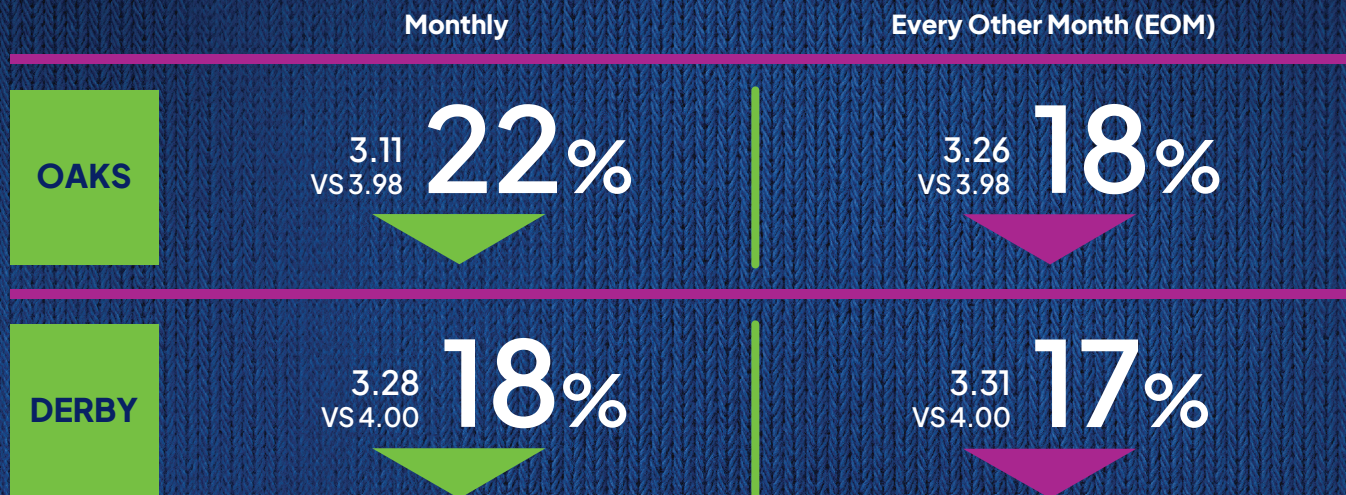
● Neovascular AMD

- In clinical trials, use of SYFOVRE was associated with increased rates of neovascular (wet) AMD or choroidal neovascularization (12% when administered monthly, 7% when administered every other month and 3% in the control group) by Month 24. Patients receiving SYFOVRE should be monitored for signs of neovascular AMD. In case anti-Vascular Endothelial Growth Factor (anti-VEGF) is required, it should be given separately from SYFOVRE administration.

● Intraocular Inflammation

- In clinical trials, use of SYFOVRE was associated with episodes of intraocular inflammation including: vitritis, vitreal cells, iridocyclitis, uveitis, anterior chamber cells, iritis, and anterior chamber flare. After inflammation resolves, patients may resume treatment with SYFOVRE.

SYFOVRE achieved continuous reductions in mean lesion growth rate* (mm²) vs sham pooled from baseline to Month 24¹



SE in trials (monthly, EOM, sham pooled): OAKS: 0.15, 0.13, 0.14; DERBY: 0.13, 0.13, 0.17.

*Slope for baseline to Month 24 is an average of slope of baseline to Month 6, Month 6 to Month 12, Month 12 to Month 18, and Month 18 to Month 24.¹ Based on a mixed effects model for repeated measures assuming a piecewise linear trend in time with knots at Month 6, Month 12, and Month 18.¹ AMD=age-related macular degeneration; GA=geographic atrophy; SE=standard error.



Explore more at
SyfovreECP.com

IMPORTANT SAFETY INFORMATION (CONT'D) WARNINGS AND PRECAUTIONS (CONT'D)

● Increased Intraocular Pressure

- Acute increase in IOP may occur within minutes of any intravitreal injection, including with SYFOVRE. Perfusion of the optic nerve head should be monitored following the injection and managed as needed.

ADVERSE REACTIONS

- Most common adverse reactions (incidence $\geq 5\%$) are ocular discomfort, neovascular age-related macular degeneration, vitreous floaters, conjunctival hemorrhage.

Trial Design: SYFOVRE safety and efficacy were assessed in OAKS (N=637) and DERBY (N=621), multi-center, 24-month, Phase 3, randomized, double-masked trials. Patients with GA (atrophic nonexudative age-related macular degeneration), with or without subfoveal involvement, secondary to AMD were randomly assigned (2:2:1:1) to receive 15 mg/0.1 mL intravitreal SYFOVRE monthly, SYFOVRE EOM, sham monthly, or sham EOM for 24 months. Change from baseline in the total area of GA lesions in the study eye (mm²) was measured by fundus autofluorescence (FAF).^{1,4}

References: **1.** SYFOVRE (pegcetacoplan injection) [package insert]. Waltham, MA: Apellis Pharmaceuticals, Inc.; 2023. **2.** Pfau M, von der Emde L, de Sisternes L, et al. Progression of photoreceptor degeneration in geographic atrophy secondary to age-related macular degeneration. *JAMA Ophthalmol.* 2020;138(10):1026–1034. **3.** Bird AC, Phillips RL, Hageman GS. Geographic atrophy: a histopathological assessment. *JAMA Ophthalmol.* 2014;132(3):338–345. **4.** Data on file. Apellis Pharmaceuticals, Inc.

Please see Brief Summary of Prescribing Information for SYFOVRE on the adjacent page.

Apellis

APELLIS®, SYFOVRE™ and their respective logos are registered trademarks and/or trademarks of Apellis Pharmaceuticals, Inc. ©2023, Apellis Pharmaceuticals, Inc. 2/23 US-PEGGA-2200051 v1.0

SYFOVRE™
(pegcetacoplan injection)
15mg / 0.1mL

WE SHARE YOUR INSPIRATION



The hopes of patients with retinal disease guide our shared focus.
Working together, we strive to improve the lives of more people every year.
Watch the Regeneron commitment at [RegeneronPossibilities.com](https://www.regeneronpossibilities.com).

REGENERON
SCIENCE TO MEDICINE®

REGENERON OPHTHALMOLOGY
With you, dedicated to eye health

Science to Medicine® is a registered trademark of Regeneron Pharmaceuticals, Inc.
© 2022, Regeneron Pharmaceuticals, Inc. All rights reserved.
777 Old Saw Mill River Road, Tarrytown, NY 10591

07/2022
OPH.22.07.0008