

AMYLOIDOSIS OF THE LOWER RESPIRATORY TRACT

BY

C. BARRINGTON PROWSE

From the Royal Sussex County Hospital, Brighton

(RECEIVED FOR PUBLICATION APRIL 8, 1958)

This paper reports two new examples of a rare form of amyloidosis affecting the lower respiratory tract, and reviews previous cases. A short survey of amyloid disease is included. The cases under consideration belong to the localized tumour-forming variety of the disease and do not include examples of the primary systemic form in which bronchopulmonary deposits are present.

HISTORY

Rokitansky (1842) is generally credited with the first account of lardaceous disease although it had been observed long before. Jeremiah Wainwright gave an unmistakable description of it in 1737, as did John Abercrombie in 1828. Lardaceous disease became established as a clinical entity between 1850 and 1888, with several reported series of sufferers, notably 83 by Dickinson (1879), 58 by Charleswood Turner (Dickinson, 1879), 36 by Samuel Wilks (1856), and 244 by Hilton Fagge (1876), who analysed necropsy records of 20 years at Guy's Hospital. Virchow (1858) was the first to describe the minute pathology of the condition, which he named amyloid disease.

In 1886 Wild described a woman with amyloid deposits of unusual distribution. The heart, intestines, tongue, peritoneum, urinary bladder, and lungs were chiefly affected, whereas the spleen, liver, and kidneys were completely free from deposits. Furthermore there was no antecedent chronic sepsis. Wichmann (1893) referred to local and generalized forms of amyloidosis, and Lubarsch (1929), reporting three cases resembling that described by Wild (1886), classified the disease into typical, common, or secondary, and atypical, primary, or systematized forms, suggesting diagnostic criteria. Primary amyloidosis was first recognized clinically by Reimann, Koucky, and Eklund in 1935; they classified amyloidosis under four headings, namely, (1) primary, (2) secondary, (3) tumour-forming, and (4) associated with multiple myeloma, but they commented that the groups overlapped, particularly the first, third, and fourth. Group 4 they regarded as secondary, in

spite of a resemblance to the primary form in the character and distribution of the amyloid deposits. Tumour-forming amyloidosis they regarded as primary in type and characterized by small, solitary, or multiple tumours in the eye, bladder, urethra, pharynx, tongue, and, especially, the respiratory tract. Primary amyloidosis is rare, and in 1950 Higgins and Higgins could find records of only 71 authentic cases, including one of their own. These 71 cases do not include examples of the primary tumour-forming variety of the disease.

Burow described an amyloid tumour of the larynx in 1875, and in 1883 Balser reported a man who had "tracheo- and broncho-stenosis with amyloid in the wall of the airway." Kramer and Som, reviewing the literature in 1935, found reports of 95 cases with primary tumour-forming amyloidosis of the respiratory tract, in 36 of which the larynx alone was involved, and with the tongue in another eight; the trachea was affected alone in 13 cases, and with a bronchus in another four; the lung alone in four cases. Stark and McDonald (1948) and Stark and New (1949) found 15 out of 28 cases in the Mayo Clinic records up to 1949 in which they were able to confirm the diagnosis, and among these the larynx was involved in eight, in one of which a bronchus was also affected. More recently Schottenfeld, Arnold, Gruhn, and Etes (1951) in America and Whitwell (1953) in England collected the records of primary tumour-forming amyloidosis of the lower respiratory tract. Five of Schottenfeld's cases, however, had amyloid deposits only in the larynx and trachea, or the trachea by itself, and because no bronchus or lower part of the respiratory tract was involved, these have been excluded from the present review. Schottenfeld and others described one new case (1951), Noring and Paaby (1952), Schmidt, McDonald, and Clagett (1953), and Gordon (1955) one each, and Whitwell 10, from the earlier literature as well as one of his own. Gordon referred to two cases recorded by Lunzenauer (1952), who found des-

criptions of nine others in the literature. Five of the latter are included in the two series reported by Whitwell and Schottenfeld and others; the other four and Lunzenauer's second case are not acceptable as examples of localized tumour-forming amyloidosis. With the two further cases here, the total of those now recorded is 18.

Hitherto no attempt has been made to classify these or to determine whether the clinical pattern can be distinguished from that of other affections of the lower respiratory tract. The main purpose of this paper is to put forward such a classification and to show that in a majority group the clinical features and bronchoscopy appearances are both singular and characteristic. Thirteen of the 16 recorded cases are men and three women; moreover, all the female patients belong to a group in which the amyloid deposits were found only in the lungs, and remained clinically silent. No case belonging to the characteristic majority group has ever before been described in a woman, and the new cases, of which detailed accounts follow, although only two in number, must in this respect be regarded as unique. One has died during the preparation of this paper, the other survives.

CLINICAL PICTURE OF TWO NEW CASES

CASE 1.—An unmarried female clerk aged 52 years had enjoyed good health until in September, 1952, she had an attack of "acute bronchitis." In February, 1953, she had a second and in November, 1953, a third similar attack. Although the acute symptoms subsided on each occasion an irritating but unproductive cough and effort dyspnoea persisted from the time of the first attack. A radiograph of the chest in March, 1954, was reported to show incomplete expansion of the left lower lobe, possibly affecting only one segment, with slight mediastinal displacement to the left. As her symptoms persisted the radiograph was repeated a month later; this showed no change and further investigation was advised.

She was healthy but overweight at 181 lb. (82 kg.). There was slightly impaired resonance and reduced air entry over the lower lobe of the left lung, where a well-marked and persistent expiratory wheeze could be heard. The cardiovascular and other systems were normal. There was no enlargement of liver, spleen, or lymph nodes and the urine contained no abnormal constituents. The erythrocyte sedimentation rate (E.S.R.) was 48 mm. in one hour by Wintrobe's method.

After three weeks, during which she had another cold, the cough and effort dyspnoea were unchanged, although she had lost 10 lb. in weight by dieting. When I saw her at this time she had evident stridor and paroxysmal cough suggesting an obstructive lesion in a segmental bronchus of the left lower lobe. She

was admitted to hospital, and bronchoscopy (Fig. 5) revealed a remarkable appearance of the mucous lining of the trachea and bronchi described as follows: The cords were normal. The mucous membrane of the trachea was thickened and had a gelatinous appearance, the changes having a focal rather than a general distribution so that small plaques and mounds stood away from what remained of the normal surface of the mucous membrane. The carina was thickened because of this abnormality of its epithelial covering, and the same condition became more pronounced in the peripheral parts of the bronchial tree. The left side was more affected than the right, and swelling of the mucous membrane lining the stem bronchus to the left lower lobe was of a degree to prevent entry of the bronchoscope into it. All main and segmental bronchi were affected and bled easily in their narrowed distal parts. At the time I thought these changes were probably inflammatory, but a biopsy showed extensive amyloid infiltration in the bronchial submucosa (Fig. 3). Microscopic examination of the sputum was repeatedly negative for acid-fast bacilli. Blood examination showed haemoglobin 112%, leucocytes 8,300 per c.mm., E.S.R. 23 mm., and a normal blood cell morphology. The urine contained no cells, casts, albumin, or Bence Jones protein.

She lost more than 28 lb. (13 kg.) after a month's dieting, and felt better than for two years. She received no other treatment except postural drainage and breathing exercises daily. A little stridor could still be heard, but no other abnormal signs were to be found and a radiograph showed improved expansion of the left lower lobe segments. Another bronchoscopy six months after the first showed no significant change in the condition of the bronchial mucosa, but the stem bronchus to the left lower lobe was less narrowed than previously. At the same time a Congo red test was negative, 95% of the original dye remaining after one hour. The serum proteins were normal with a total of 7.8 g. per 100 ml., of which the albumin was 5.7 g. and globulin 2.1 g., with an A/G ratio of 2.7. The electrophoretic pattern of the serum proteins was normal. The E.S.R. had fallen to 19 mm. in one hour, and Bence Jones protein was again absent from the urine.

During the next three years she remained well and free from symptoms other than slight exertional dyspnoea. She had cough and sputum only with a cold and she never had any haemoptysis. Slight stridor was noted sometimes, but no physical signs or radiographic changes reappeared in the left lower lobe area. Her weight remained steady at just over 165 lb. (75 kg.). Serum protein electrophoresis was twice repeated and similar normal curves were obtained. Sternal marrow biopsy produced smears in which the cells were normal in their appearance and distribution; there was no excess of plasma cells.

She was last seen at hospital in January, 1956, when she attended as an out-patient for routine examination. She was then well, free from all symptoms, well covered, and had gained a little weight; there

was no stridor and no abnormal signs were observed in her lungs or elsewhere. The chest was normal radiographically except for slight accentuation of the lung markings in the posterior basic segment of the left lower lobe. Two months later she had bronchitis again and became very wheezy, but the attack responded to penicillin and she returned to work after 10 days in bed at home. Thereafter she was well for nine months until another bout of bronchitis developed in December, 1956, when she failed to respond to penicillin and after 10 days became very ill. Her doctor noted cyanosis, intense dyspnoea, and

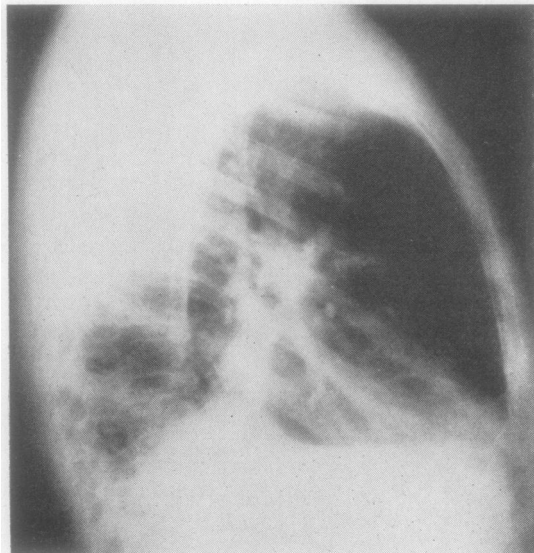
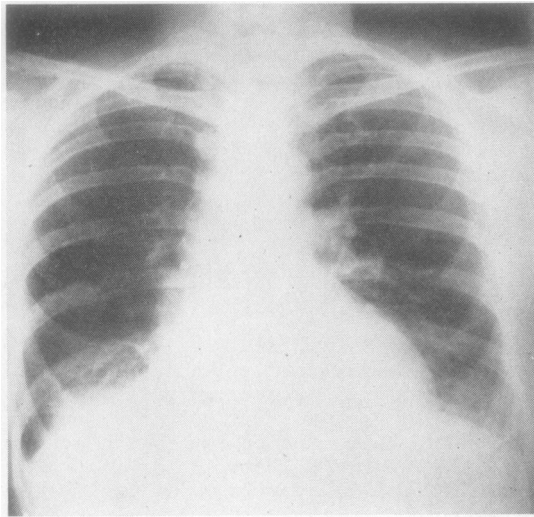


FIG. 1a and b.—Case 2, May, 1952. Postero-anterior and right lateral radiographs showing collapse and consolidation of the posterior basic segment of the lower lobe of the right lung.

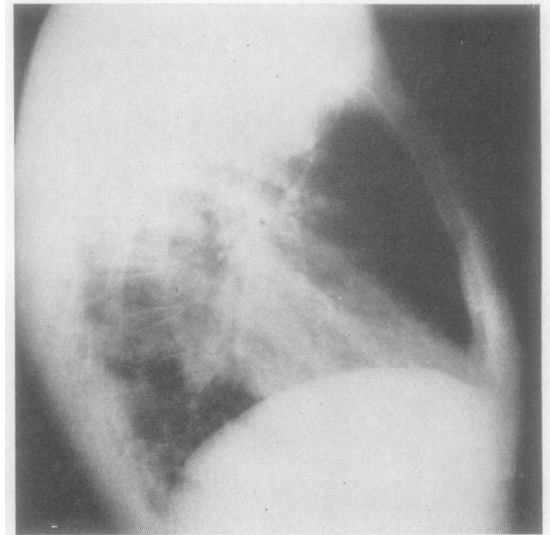
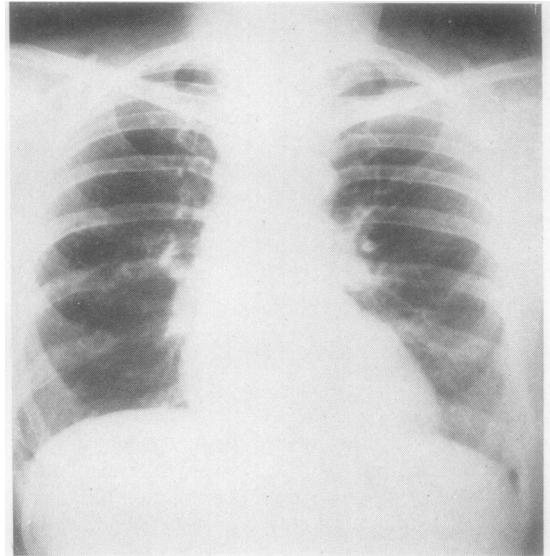


FIG. 2a and b.—Case 2, February, 1956. Postero-anterior and right lateral radiographs showing resolution.

what he described as “roaring” breath sounds audible at a distance. Her condition deteriorated rapidly and “she quite suddenly collapsed and died.” A necropsy was not obtained.

CASE 2.—In April, 1949, a married woman of 47 complained of wheezing and difficult breathing. Her general health, she said, was satisfactory, she had no cough or sputum and her weight was steady. There was no history of chest disease or other relevant illness in her family, but she herself had been subject to “chesty colds” for most of her life. It was in one of these, nine years previously, that she had lost her

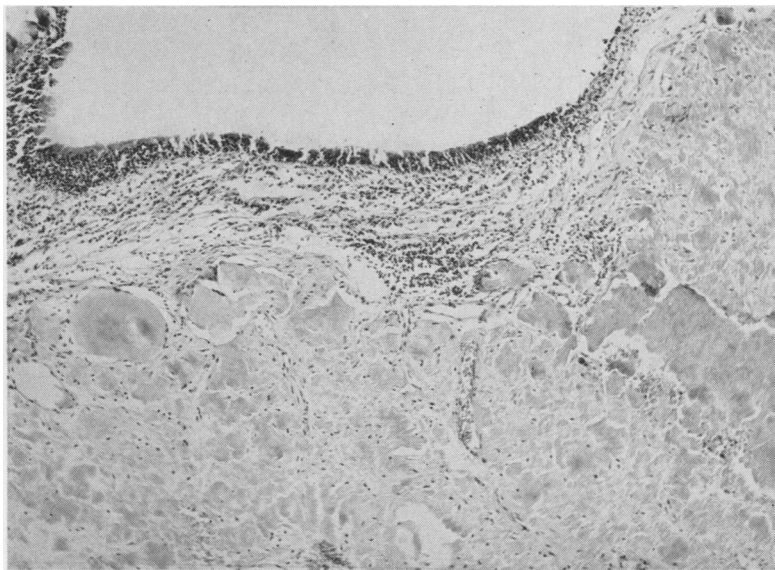


FIG. 3.—Case 1. Bronchial biopsy, showing deposits of amyloid in the submucosal tissues. Haematoxylin and eosin. $\times 100$.

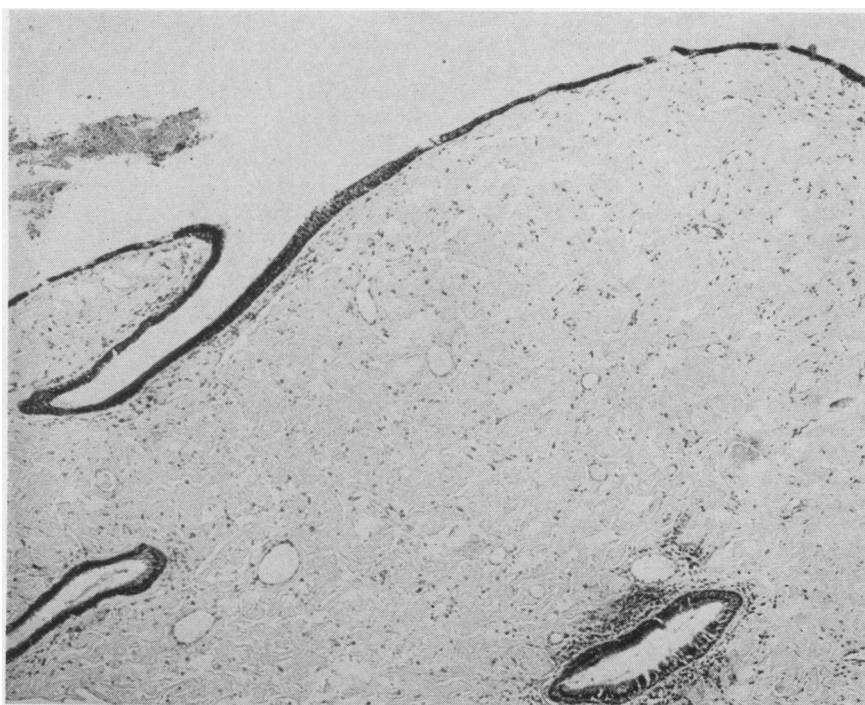


FIG. 4.—Case 2. Laryngeal biopsy, showing deposits of amyloid in the submucosal tissues. Haematoxylin and eosin. $\times 50$.

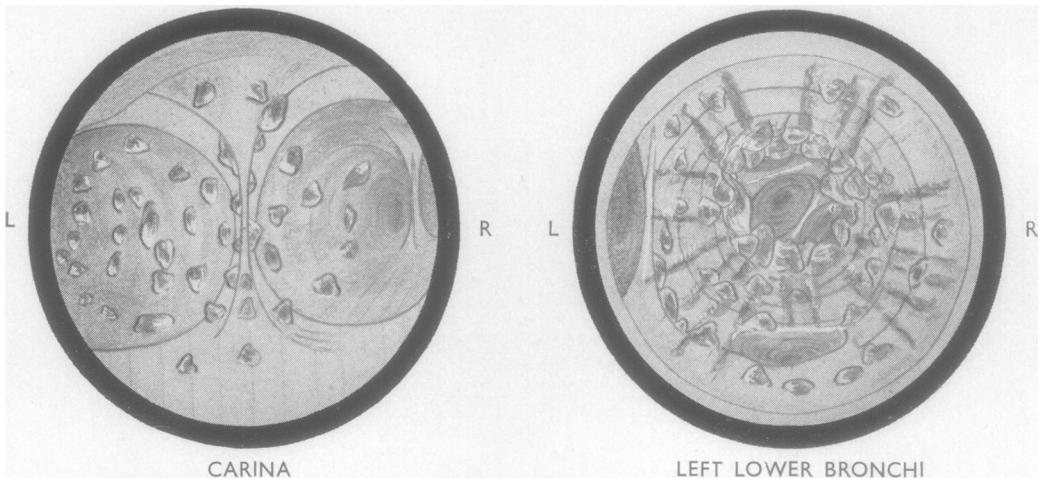


FIG. 5.—Case 1. Drawings of carina and left lower lobe bronchus with its branches seen at bronchoscopy.

voice, which had never afterwards regained its full tone and power. Thereafter she had lost it again and noticed wheezing and difficulty with breathing whenever she developed a cold. Her voice was a little hoarse and stridor was marked, but her appearance was healthy and her general condition good. Her throat and neck were normal and examination of the heart, lungs, and abdomen was negative. Radioscopy revealed no abnormality in the lung fields or mediastinum. I thought that the stridor was probably due to an intrinsic obstructive lesion of the larynx or trachea and referred her to the throat surgeon, who saw a "red swelling" through the glottis and later removed, from the anterior commissure of the larynx, what was reported to be a chronically inflamed "simple cyst," lined by squamous epithelium.

For three years she remained well, troubled only by slight hoarseness of the voice, worse whenever she contracted a cold. In May, 1952, however, wheezing and difficult breathing returned with noisy stridor and severe dyspnoea. In the subglottic region, arising anterolaterally on the left side, was an irregular, pale greyish-yellow mass which occupied two-thirds of the airway; this was removed piecemeal and found histologically to consist of laryngeal mucous membrane heavily infiltrated with amyloid (Fig. 4).

Well-marked stridor and dyspnoea persisted and were still sufficiently severe after two months for tracheostomy to be considered, but gradual improvement followed and she remained comfortable except for slight exertional dyspnoea until a year later, when severe stridor and breathlessness returned and greyish-yellow masses could be seen in the subglottic region once more. Tracheostomy was done in July, 1953, and the trachea above found to be much narrowed by amyloid infiltration of its mucous membrane, confirmed again histologically.

Once reconciled to a permanent tracheostomy she remained comfortable for 12 months, but then developed bronchitis with severe dyspnoea, unrelieved by bronchial suction. At bronchoscopy the right

main bronchus was found to be narrowed by thickened mucous membrane, which had a yellowish-grey appearance; the bronchial tree on the left side showed acute inflammatory changes only. A considerable quantity of viscid mucus was sucked up from the right main bronchus, but the bronchoscope could not be passed beyond the narrowed portion and no view of the distal parts of the bronchial tree was obtained.

In January, 1955, she was admitted to hospital with haemoptysis, but this ceased within 48 hours and no bronchoscopy was done; the source of the haemorrhage, therefore, was not proved but was thought more likely to have been granulation tissue at the tracheostoma than the amyloid-infiltrated mucosa. After her recovery from the haemoptysis, dyspnoea and stridor gradually diminished until, in the summer of 1955, she was able to breathe easily, even with the tracheostomy covered. For two months then she wore no tube, but she would not have the tracheostomy closed. The following winter passed without any serious respiratory infection, but in the autumn she complained of some increase in exertional dyspnoea. Her general condition was good, but stridor was more pronounced than it had been and another bronchoscopy was advised. This was done with a child's bronchoscope introduced through the tracheostomy opening; a good view was obtained of the carina and main bronchi, both of which were greatly narrowed by submucous deposits of amyloid. The tracheal lining was pale greyish and had a slightly irregular surface. The right main bronchus was reduced to a third of its normal diameter by a large, darker grey plaque on its postero-lateral wall which gripped the bronchoscope and felt boggy; the stem bronchus beyond was not much narrowed, but its lining was so irregular that no individual segmental bronchial orifice could be identified. The lumen of the left main bronchus was even smaller and seemed to close completely in some phases of respiration; the obstructing mass was less well defined than on the right

side, but it could also be passed and the segmental branches arising from the stem bronchus beyond could all be recognized. A total of about 5.0 ml., by volume, of tissue was nibbled away with biopsy forceps, principally from the region of the carina, and there was very little bleeding. Histological examination showed tall ciliated columnar epithelium with areas of squamous metaplasia and extensive infiltration of the submucosa with amyloid material which took up Congo red and gave a slightly metachromatic reaction with methyl violet.

For three days after this operation the stridor was worse, but she then improved sufficiently for a cine-bronchogram to be attempted. She became acutely distressed when the opaque oil was introduced, and the examination had to be abandoned before any useful information had been obtained. Two weeks later she had recovered sufficiently to return home, but almost at once developed bronchitis and became acutely ill. When readmitted to hospital she was pale, cyanosed, sweating, and terribly distressed; the stridor could be heard outside the ward as she struggled to get air into her lungs and to raise the copious viscid sputum which clogged the trachea and threatened to suffocate her. She was nursed in an oxygen tent and tracheal suction was maintained through a rubber catheter inserted into the tracheostomy opening. "Alevaire" inhalations helped to liquefy the sputum and the bronchial infection was controlled by antibiotics. After a fortnight she was able to return home, but still had well-marked stridor, which was not improved when a larger tracheostomy tube was inserted at her own request. A month later the stridor was less and she has remained fairly well since.

Radioscopy revealed no pulmonary abnormality in April, 1949, when stridor was first observed, but when acute symptoms returned in May, 1952, radiographs showed collapse and consolidation in the lower lobe of the right lung affecting principally its posterior basic segment, with compensatory emphysema in the right upper lobe; the left lung was clear and the hilar shadows normal (Fig. 1). In August, 1953, a week after tracheostomy, resolution and re-expansion of the right lower lobe had taken place except in its posterior basic segment, but even in February, 1956, (Fig. 2), when the patient was very well and when closure of the tracheostomy was considered, both lower lobes were still not completely expanded. In December, 1956, on the other hand, when bronchoscopy showed gross narrowing of both main bronchi, chest radiographs were normal, and even after the severe attack of bronchitis in January, 1957, both lungs remained fully expanded.

Abnormal signs, reduced movement, impaired resonance, and weaker breath sounds with rhonchi and medium rales were found at every clinical examination after the summer of 1954, when bronchoscopic evidence was obtained of amyloid infiltration in the right main bronchus. Similar signs, though less well marked, were observed at the left base in September, 1955, when imperfect expansion of the left lower lobe

was also visible radiographically. In December, 1956, no abnormal signs were present except the stridor, and even when respiratory distress was at its most dramatic, in January, 1957, the lungs remained resonant and air could be heard entering all parts, though medium and coarse rales were numerous. Unfortunately no record was made of clinical examination other than that of the larynx and trachea between 1949 and 1954, so that it is impossible to be certain whether the clinical and radiographic findings since then merely reflect recurring inflammatory episodes in a condition of partial bronchial obstruction which has not itself progressed, or whether the amyloid infiltration has increased.

Serum protein estimations on four occasions between 1953 and 1957 gave normal figures for total protein and the albumin and globulin fractions. The electrophoretic curve was normal in March, 1955, but showed slight excess of γ globulin when repeated six months later; in January, 1957, the α_2 globulin was increased, the β and γ fractions were normal.

The haemoglobin level has remained between 80 and 90%, and total leucocyte counts between 6,000 and 8,000 per c.mm., with a normal differential distribution, and the red cell morphology have always been normal. The erythrocyte sedimentation rate at the time of the last serum protein estimation was 17 mm. in one hour (Wintrobe). The cellularity of the bone marrow and the morphology of the constituent cells were normal; there was no excess of plasma cells. There has never been albuminuria or Bence Jones proteinuria, and a Congo red absorption test was negative.

REVIEW AND CLASSIFICATION OF ALL CASES (18) NEW AND PREVIOUSLY DESCRIBED

Of the 18 patients with amyloidosis of the lower respiratory tract so far described, seven from German writings between 1883 and 1928, Lunzenauer's case (1952), and one from Sweden very briefly outlined by Falconer (1938) were recognized only at necropsy. The other nine, described in modern accounts from America, Scandinavia, and Great Britain between 1947 and 1955, were diagnosed by biopsy. Five of these patients survived at the time of reporting. The clinical features, pathological changes, and bronchoscopic appearances found in these 18 patients prompt their division into three groups:

GROUP I.—In this group the amyloid material occurred in the lung only, producing silent tumours found incidentally at necropsy after death from an unrelated cause.

In this group are four of the 18 patients: two women, aged 52 and 72, who died of pneumonia, in the substance of whose lungs Hallermann (1928) found "peculiar foci" having the gross and microscopic appearances and some of the staining

properties of amyloid; Lunzenauer's first case (1952), another woman, who was 83 years old when she died from a short, undiagnosed illness and whose lungs at necropsy were closely studded with discrete amyloid tumours varying in size from that of a hazel nut to that of an apple; and Meyer's patient (1911), a man of 57 with chronic interstitial nephritis, who died from a cerebral haemorrhage and in whom, at necropsy, were found two subpleural amyloid tumours the size of apples and many smaller pea- and bean-sized deposits, each having a grey transparent surface on section. None of these patients had had any antecedent respiratory symptoms or illness, and the larynx, trachea, and bronchi were not involved in any of them.

GROUP II.—This group consists of three patients, each one of whom had an amyloid tumour involving a branch or branches of the bronchial tree and causing respiratory symptoms, but in whom the bronchial passages as a whole were free from amyloid deposits. All three cases were recorded by Weismann, Clagett, and McDonald (1947), Haynes, Clagett, and McDonald (1948), Schmidt and others (1953), and McDonald (1957), and all were men. Clinical summaries are given in the Appendix.

GROUP III.—The characteristic feature of this group is diffuse infiltration of the trachea and bronchial passages with amyloid material which is deposited under an intact mucosa in ridges, folds, plaques, and mounds, and causes intrinsic narrowing. This is the largest of the three groups and comprises nine cases in men already reported, and the two new cases—both in women—here recorded. Six are from the modern group of cases diagnosed during life and in these valuable clinical details are available which make it possible to distinguish a clear clinical picture. Necropsy material is also available in two of the six recent cases, and although clinical details are scanty in the five earlier examples, their pathological anatomy is fully described and accords so closely with that described by Noring and Paaby (1952) and by Gordon (1955) in their necropsy reports that the clinical manifestations cannot have been very different. Clinical summaries are given in the Appendix.

DISCUSSION

It is doubtful if the few recorded examples of amyloidosis of the lower respiratory tract reflect its present incidence. It must have been rare in the past since reference to it in necropsy reports is so scanty, but during the last decade the recorded

cases have been more than doubled. Those in Group I are clinically silent, do not affect longevity, and need to be remembered only in the differential diagnosis of other solitary tumour masses. Those in Group II may also be silent, but even when the amyloid tumour involves a bronchus the resulting features do not differ from those of other solid tumours within the lungs or mediastinum. Bronchoscopy in this group is of value only to exclude commoner causes of bronchial obstruction unless the bronchial wall itself is infiltrated with amyloid and gives biopsy proof. Thoracotomy is generally necessary to establish the diagnosis and offers the prospect of curative resection. Radiotherapy is probably useless and local removal of amyloid tissue of limited value and not without hazard.

By contrast the cases of Group III have a clear clinical pattern and unique bronchoscopic and pathological features by which they may be recognized and which earn them the right to be considered as constituting a distinct clinicopathological syndrome for which "diffuse tracheo-bronchial amyloidosis" would be a suitable name. This is the largest group and it includes 11 of the 18 cases. The distinctive feature is the wide and irregular distribution of the amyloid deposits within the trachea and bronchi to produce narrowing, which may cause temporary or permanent occlusion and lead to inadequate ventilation of the pulmonary bed as a whole.

DIFFUSE TRACHEO-BRONCHIAL AMYLOIDOSIS (Group III).—There is no occupation, habit, or physical peculiarity which seems to predispose to this variety of amyloid disease, but it has a regular clinical pattern which is clearly discernible in the 11 cases in the present series.

The average age at onset of symptoms is 45 years; men predominate and the two new examples recorded here are in fact the only two women in whom this disease has ever been described. Some respiratory symptoms will generally have been present for years before medical advice is sought and the period may be very long. In the present series recurrent bronchitis, hoarseness or loss of voice, wheezing, stridor, and progressive effort dyspnoea were all encountered either singly or in combination for varying periods up to 40 years. The four principal symptoms are cough, dyspnoea, stridor, and hoarseness of the voice, and especially the latter two. Hoarseness was noted in four, and stridor, the most striking and characteristic symptom, in seven of the 11 cases. The stridor

is remarkable in its chronicity, and, even when not immediately obvious, it may often be recognized locally by auscultation. During attacks of bronchitis, which commonly complicate this variety of amyloid disease, it may be heard at a distance in inspiration and expiration. Inspiration is characteristically prolonged and difficult, in contrast to the expiratory difficulty of asthma. The cough is persistent, dry, and hacking alike during the early stages of the disease and between the acute inflammatory episodes; it is often, also, slightly "brassy" because of the associated stridor. Sputum is scanty and mucoid except when irritation of the bronchi, whether from infection or instrumentation, causes thick, viscid, sometimes purulent secretion so difficult to raise that the patient may risk suffocation. During the premonitory period and between episodes of secondary infection, dyspnoea is disproportionate to effort and to other clinical evidence of respiratory disease. Haemoptysis was an early symptom in two cases. It also occurred later in two; in Schottenfeld's case (1951) during an attack of pneumonia, and later as the terminal event of his life (Schottenfeld, 1957), and severely also in my second case when she had bronchitis. Here the source of haemorrhage may well have been granulation tissue at the tracheostomy rather than the amyloid-infiltrated bronchial mucosa.

The physical signs are those of associated bronchopulmonary infection and pulmonary collapse and consolidation. Attacks of bronchitis and pneumonia first brought the patient under observation in four of the six with clinical records; Noring and Paaby's patient (1952) had seven attacks of pneumonia in one year, followed by eight further admissions to hospital for bronchitis or pneumonia during the next four years. Stridor was a striking feature with each attack, and respiratory distress was graver on each succeeding occasion. Lobar collapse and consolidation or clinical pneumonia are not necessarily confined to a single lobe or segment, but characteristically occur in varying situations; moreover, these changes tend to be insidious or to complicate mild upper respiratory or bronchial infections. Conversely, they may be absent during the most severe episodes of bronchitis.

Even after several attacks of bronchitis or pneumonia and when the bronchoscopic appearances seem to be unchanged, lobes and segments which have remained collapsed for many months may, nevertheless, and often most surprisingly, re-expand. This occurred after long periods in both my own cases, and the second woman—who

is still alive—has survived desperate illnesses as a result of infection and instrumentation; collapsed lower lobes on both sides have also re-expanded, the right having been at one time partially deflated for more than a year. In Schottenfeld's case the lingula and left lower lobe re-expanded after nine months, though this may have been assisted by regular removal of amyloid tissue. The right lower lobe never completely resolved and re-expanded in Noring and Paaby's case, nor the left lower lobe in Gordon's, though the left upper lobe did reopen partially. These two patients took a steadily downward course and respectively died within five and two years of the onset of severe symptoms.

BRONCHOSCOPY.—Bronchoscopy is the most useful and important of all aids to diagnosis in this condition, and so characteristic are the naked-eye appearances (Fig. 5) that histological examination of biopsy material is only required to confirm the diagnosis or if the observer is unfamiliar with the condition. Because of the rarity of this form of amyloidosis no standard description of the bronchoscopy appearances has yet found its way into medical literature and the accounts of those who have observed the condition consequently retain a refreshing individuality.

Typically, the lesions are widely dispersed, irregular in size and shape, and diverse in colour. In the subglottic region, where the largest deposits occur, they may reach the size of a cherry and become pedunculated; in the trachea smaller deposits are the rule and they vary in form from small, flat elevations, conical mounds, and pinhead-sized drops, to broad plaques and longitudinal folds, sometimes having a polypoid appearance, particularly at the carina, where deposits are generally greatest and may be 7 or 8 mm. thick. Similar lesions are to be seen in the major bronchi and their lesser divisions, but their individuality is lost in the more peripheral parts where longitudinal folds predominate and may so reduce the lumen, even of the main bronchi, that the tip of the bronchoscope cannot enter. When the instrument is gripped in such narrowed parts the tough and sometimes gritty consistence of the lesions can be appreciated. Whatever their form, the deposits invariably lie under intact mucous membrane which probably accounts for their glistening and translucent appearance. Grey is their predominating colour, but bluish-white, pale yellow, orange, and red tints have been noted by different observers both bronchoscopically and at necropsy. The lesions are not friable and, in spite of some contrary assertions, they do not bleed

easily; nevertheless, haemoptysis is a fairly common symptom, and, since the deposits themselves are not vascular, it must be assumed that secondarily infected intact mucous membrane between the deposits is the source of haemorrhage when it occurs.

RADIOGRAPHY.—Radiography may show all degrees of lobar or segmental consolidation and collapse as well as compensatory emphysema and pleurisy with or without effusion, but the diagnosis cannot be made without a knowledge of the clinical picture and bronchoscopy findings. Bronchograms will sometimes demonstrate extreme bronchial narrowing or occlusion, but this examination is not well tolerated by patients with this disease; they are easily suffocated by the introduction of opaque oil which blocks the narrowed bronchi and cannot readily be raised again by coughing. Hilar lymph node enlargement is not a usual feature of this condition.

LABORATORY INVESTIGATIONS.—A number of laboratory investigations were carried out in the six most recent cases. None of the tests made contributed to the diagnosis, but certain negative findings were of interest.

Serum Proteins.—The albumin and globulin fractions and A/G ratios were normal in all cases. The electrophoretic pattern of the serum proteins was normal on two occasions in my first case; a normal curve was also obtained once in my second case, but two later curves showed abnormalities, one a slight increase in the γ globulin, and the other a more striking increase in the α_2 fraction. It may be significant that she was recovering from a severe attack of acute bronchitis when the last estimation was made.

Congo Red Absorption.—This test was carried out in five cases and showed normal results in all.

Urine.—Bence Jones protein was not present in any case.

Blood.—The numbers of red cells and their haemoglobin content were normal. The E.S.R. was raised in several instances but not consistently, and the higher readings almost certainly reflected a response to secondary infection rather than to the primary disease, as a polymorph leucocytosis certainly did on the two occasions when it occurred.

Marrow Biopsy.—This was performed in four cases and the findings were normal in all. No increase in plasma cells was observed in any.

PATHOLOGY.—The pathological changes occur only in the respiratory tract and those organs and tissues closely associated with it. Amyloid

deposits may be present in the submucous tissues of the larynx, trachea, bronchi of all sizes, and sometimes even in the alveolar septa. They occur in the form of granules, plaques, ridges, tumours, or even pedunculated masses, and cause narrowing and rigidity of the passages. The mucosal lining of the bronchi may be 6 to 8 mm. thick; it generally feels firm, but may be soft if the deposits are extensive and have eroded the mucosa and distorted the cartilaginous rings, or gritty if they contain spicules of bone. The colour of the deposits varies from bluish white to green, yellow, orange, or red, and their cut surface is glassy and shining. They are avascular. Secondary inflammatory changes are to be expected in the bronchi and lungs in the later stages of the disease.

Microscopically the amyloid is deposited in the submucous connective tissue close to the cartilage; the bands of the latter may be forced apart by it and altered in appearance. Deposits have been noted in the media and subintimal connective tissues of the pulmonary artery and its branches, and a hilar lymph node was involved in one instance, but amyloid deposits in other organs have been otherwise notable by their absence.

DIFFERENTIAL DIAGNOSIS.—The differential diagnosis has to be made from other conditions which cause bronchial irritation or obstruction. Whereas it may be impossible to distinguish a single large amyloid tumour from a neoplasm without surgical exploration or examination of biopsy material, the long history, good general condition of the patient, and the widely distributed bronchial lesions characteristic of cases in Group III make a diagnosis of foreign body or neoplasm, even an innocent tumour, improbable. Bilateral lesions may simulate tuberculous infiltration at first, but, as before, the excellent general condition of the subject suggests the alternative, and the subsequent clinical and radiological course of the two diseases is entirely different. Pneumonia has always to be considered initially, but will either clear quickly and completely or, if resolution is delayed, demand fuller investigation, including bronchoscopy, generally to exclude carcinoma. The long history with wheezing, effort dyspnoea, and recurrent bronchitis may suggest a diagnosis of asthma, in which lobar and segmental atelectasis or consolidation are also not uncommon; but in amyloid disease there is no tendency to sudden, seasonal, or climatic variation in the severity of symptoms and a past personal or family history of allergy would be less frequently obtained. The history

may also suggest bronchiectasis, particularly when chronic lobar collapse and consolidation are associated with cough and copious mucopurulent sputum, but the sputum is never persistently copious or purulent in amyloid disease and is less easily raised by postural drainage. There is usually evidence of a predisposing cause for bronchiectasis.

Very chronic stridor in the absence of laryngeal disease is a symptom which is virtually exclusive to this type of amyloidosis of the lower respiratory tract, and the peculiar prolongation of inspiration which sometimes accompanies it may help to distinguish the respiratory embarrassment occurring in this disease from that commonly found in asthma. If these features are recognized they should settle any doubts in diagnosis; final confirmation may always be obtained by bronchoscopy.

TREATMENT.—There is as yet no known means of preventing or curing this diffuse form of tracheo-bronchial amyloidosis and, until the reasons for and the manner of amyloid deposition are more fully understood, and prevention or reversal of the process consequently become possible, only palliative treatment for the progressive bronchial obstruction and to combat secondary infection is available.

Piecemeal removal of amyloid tissue endoscopically has been used and has been life-saving when large pedunculated masses have threatened laryngeal obstruction, but less successful as a means of dealing with the bronchial lesions. Schottenfeld (1951 and 1957) also used electrocoagulation in his case, hoping thereby to open up the smaller distal bronchi; but, although the procedure was well tolerated and successful in the lower trachea and major bronchi, it was impracticable for the smaller divisions. He observed, too, that "even if mechanical obstruction can be relieved, any procedure which denudes the bronchus of functioning ciliated mucous membrane must, of necessity, hamper drainage from its more distant portions."

No lasting value is to be expected from piecemeal removal or electrocoagulation therapy, and the risks of infection by interference with normal bronchial drainage or by direct spread through damaged or even perforated bronchial walls make it unwise to recommend such procedures except in emergency for the removal of obstructing polypoid masses, particularly from the larger air passages.

Plastic surgical reconstruction offers an attractive alternative to these destructive methods of

treatment and is theoretically possible. Practically, however, the area involved is likely to be too great and the calibre of the bronchi too small to permit this in most cases.

PROGNOSIS.—The high average age of cases in Group I suggests that the mere presence of amyloid deposits in the lower respiratory tract does not tend to shorten life, and even when bronchial obstruction has developed, provided that this is localized and the tumour causing it removable, as in the first two cases in Group II, recovery and a normal span of life after operation are to be expected.

In Group III the prognosis is less good although here, too, the long period during which premonitory symptoms may be present without any threat to life confirms the innocence of the amyloid deposits themselves. Once narrowing of the lower air passages has reached a stage at which there is interference with pulmonary ventilation and bronchial drainage, however, secondary infection of bronchopulmonary tissues leads to recurrent haemoptysis, bronchitis, pneumonia, and pulmonary collapse, and at once shortens the expectation of life, which then does not exceed five years. Persisting lobar collapse and consolidation appears to be an unfavourable prognostic feature, and there is no evidence that the long-term prognosis is improved by endoscopic removal of amyloid tissue.

SUMMARY AND CONCLUSIONS

Attention is drawn to the rarity with which localized tumour-forming amyloidosis is found in the lower respiratory tract. Men are much more frequently affected than women.

Two new cases of this variety of amyloid disease, both in women, are described in detail and the 16 previously recorded cases are reviewed. Classification of the 18 cases has been made into three groups.

Amyloid deposition confined to the lower respiratory tract is in itself a benign affection; it may also be symptomless and, when the deposits occur only in the lungs, it may remain so. The symptoms and signs may be indistinguishable from those of bronchial or mediastinal neoplasm when single deposits of sufficient size are so placed as to interfere with the bronchi or important mediastinal structures; but when amyloid deposits occur diffusely in the trachea and bronchial walls, as in the cases in Group III, the clinical manifestations and bronchoscopic features

are distinctive. The designation "diffuse tracheo-bronchial amyloidosis" is suggested for this group.

Treatment, at present, is satisfactory only when bronchial obstruction is strictly localized, and, although the condition is itself benign, the prognosis when the respiratory passages are diffusely involved becomes progressively more unfavourable as bronchial obstruction advances and secondary infection occurs more frequently.

APPENDIX

SUMMARY OF CASES PREVIOUSLY RECORDED

Group II consisted of three cases.

CASE 1 (Haynes and others, 1948).—Male; 66 years; seven weeks' history of cough, mucoid sputum, loss of weight and epigastric pain, and dyspnoea with effort. General condition good, no signs in chest. *Radiography*—atelectasis of right middle lobe and a filling defect of right middle lobe bronchus by bronchography. *Bronchoscopy*—no intrabronchial abnormality. *Treatment*—right pneumonectomy. *Pathology*—tumour embedded in collapsed middle lobe, supplying bronchus passed into tumour and occluded by it. *Microscopically*—an amyloid tumour. No amyloid deposits elsewhere in bronchi or elsewhere in amputated lung. *Course*—one year after operation, dysphagia due to extrinsic pressure on oesophagus, assumed to be due to amyloid deposits in mediastinal lymph nodes and treated by radiotherapy and dilatation by bougies. Well six years later.

CASE 2 (Weismann and others, 1947).—Male; 35 years; nine years' history of recurrent pulmonary illnesses characterized by cough, fever, rigors, haemoptysis, and right-sided pleuritic pain. No loss of weight. General condition good; signs of partial collapse right lower lobe with overlying fluid. *Radiography*—partial collapse with patchy consolidation right lower lobe, small pleural effusion. *Bronchoscopy*—right lower lobe bronchus filled with blood. *Treatment*—right pneumonectomy. *Pathology*—hard, irregular, whitish-yellow tumour surrounding right main bronchus, right pulmonary artery, and inferior pulmonary vein, extending into right middle and lower lobes about their supplying bronchi. Microscopically, amyloid deposits in surrounding connective tissue and external coats of bronchi, but cartilaginous rings intact; arteries of all sizes in the vicinity contained amyloid deposits in varying degree. No other amyloid deposits in the bronchi or elsewhere in the amputated lung or its blood vessels. *Course*—uneventful recovery; well and working seven years later.

CASE 3 (Schmidt and others, 1953).—Male; 34 years; 18 months after an illness diagnosed as lobar

pneumonia, haemoptysis, recurring several times during next four years; left-sided parasternal pleuritic pain and loss of weight for one year. *Bronchoscopy*—carina widened, the left main and the right main and lower lobe bronchi narrowed and "infiltrated with tumour." *Biopsy*—amyloid material. *Tomography*—large mass below carina constricting both main bronchi. *Course and Treatment*—radiotherapy; developed cough, purulent sputum, fever, and loss of weight with right-sided encysted pleural effusion. Fluid aspirated; bronchoscopic removal of tumour tissue with improvement. Four years later general condition good, but dry, hacking cough.

Group III contained 11 cases.

A. Diagnosed at Necropsy

CASE 1 (Balsler, 1883).—Male; 45 years; recurrent attacks of bronchitis for 19 years, asthma 14 years and hoarseness two years. Signs of bronchostenosis with progressive anaemia and loss of weight. *Pathology*—lungs distended; larynx, trachea, and bronchi rigid and narrowed by ridges, grooves, and granules in the mucous membrane, bluish white to orange or red, glassy in appearance, and penetrated by spicules of bone. These, as well as peribronchial deposits and hilar lymph nodes, gave amyloid reaction with iodine. Aniline violet stained sections typical of amyloid.

CASE 2 (Glockner, 1900).—Male; 76 years; died of urethral obstruction, had had symptoms of laryngo-tracheal stenosis. *Pathology*—continuous armour-like thickening of lining of larynx and trachea, uniform in the former but irregular and in lumps of varying size in the latter and the main bronchi. Characteristic staining reactions of amyloid. Trachea rigid and stenosed.

CASE 3 (Herxheimer, 1903).—Male; 65 years; hoarseness of voice for 40 years. Died with un-drained empyema complicating pulmonary abscess. *Pathology*—larynx narrowed to a slit by large tumour-like masses of amyloid; similar smaller submucosal deposits in trachea and "yellow and greenish-yellow shining glassy deposits," 1 mm. in diameter, in left lung.

CASE 4 (von Werdt, 1908).—Male; 71 years; six years' hoarseness of voice and gradually increasing dyspnoea, dysphagia, and stridor from an amyloid tumour filling most of the larynx. *Pathology*—several large amyloid deposits in trachea and bronchi and many small transparent greyish-red irregular intra-bronchial nodules giving amyloid staining reactions. Excellent illustration. *Course and Treatment*—died 11 hours after tracheostomy for laryngeal obstruction.

CASE 5 (Falconer, 1938).—Male; 71 years; two months increasing dyspnoea. Died of haematemesis from gastric ulcer; amyloid infiltration of bronchial tree a chance finding post mortem. *Pathology*—both main bronchi and their lobar branches, the carina, and the lower part of the trachea narrowed to quarter of normal size by "diffuse tumourous formation" of

woody consistency, reddish grey and semi-transparent; calcification and ossification observed microscopically.

B. Diagnosed During Life

CASE 6 (Noring and Paaby, 1952).—Male; 39 years; six years of pulmonary illness. Pleurisy with effusion and recurrent episodes of "bronchitis" and "pneumonia" characterized by stridor, hoarseness, cough with tenacious mucoid, sometimes blood-stained sputum, and increasing respiratory distress; finally, pallor, cyanosis, severe effort dyspnoea and whistling inspiratory stridor audible at a distance. Signs of generalized emphysema and incomplete resolution of an inflammatory process, right lower lobe. *Radiography*—at first right pleural effusion and a florid-sized opacity at right hilum, later consistent with incomplete resolution of chronic inflammatory process in right lower lobe. *Bronchogram*—filling defect of bronchus to its posterior basic segment. *Bronchoscopy*—"Widespread, soft, partly waving tumour-like lesions" in larynx, trachea and bronchi, moulding them and their finer divisions. *Biopsy*—amyloid deposits. *Treatment*—tracheal resection attempted but found impossible; tumour tissue removed piecemeal at open operation. *Post-operative Course*—subcutaneous emphysema, abundant bronchial secretion, bronchopneumonia, death. *Pathology*—walls of trachea, main lobar and segmental bronchi thick and soft, cartilaginous rings distorted and hidden by coarse, granular, eroded mucosa; thick and narrowed bronchi communicated with brownish areas of lung. No amyloid deposits elsewhere in body. *Microscopically*—amyloid deposits in trachea, bronchi of all sizes, alveolar septa, media, and subintimal tissues of pulmonary artery and branches.

CASE 7 (Gordon, 1955).—Male; 53 years; 14 years recurrent bronchitis; two years repeated haemoptysis, one year chronic cough, dyspnoea, and attacks of acute bronchitis with loss of weight. Wasted, cyanosed, dyspnoeic; signs of collapse and consolidation left lung. *Radiography*—opacity left lung with small translucencies suggesting bronchiectatic cavitation. *Bronchoscopy*—left main bronchus partly occluded by grey, warty, freely bleeding tissue, irregular mass protruding from left upper lobe bronchus. *Biopsy*—submucosal amyloid deposits. *Treatment and Course*—infiltrated tissue nibbled away with biopsy forceps. No benefit, cough, dyspnoea, and cyanosis progressive. Died in six months. *Pathology*—purulent bronchitis, amyloid infiltration of submucosa, muscularis, and adventitia of both main bronchi. No amyloid deposits elsewhere and no disease of other organs.

CASE 8 (Schottenfeld and others, 1951).—Male; 43 years; wheezing, effort dyspnoea and winter cough with viscid mucoid, later purulent, sputum, progressive over a period of five years, marked by four attacks of pneumonia with haemoptysis and unusual dyspnoea. Well nourished, breathless, audible and palpable inspiratory and expiratory wheezing, moist

sounds left lower lobe area. *Radiography*—abnormal shadow extending from left hilum into lingula and left lower lobe. *Bronchoscopy*—thickened carina, narrowing of trachea and main bronchi by submucous globular projections and broad, flat elevations of firm consistency, varying in size; little vascularity. *Biopsy*—submucosal amyloid deposits. *Treatment and Course*—piecemeal removal with biopsy forceps of nodular masses from trachea and larger bronchi and later electrocoagulation of deposits in lobar branches, at monthly intervals for two years with clinical and radiological improvement. Bronchus to left lower lobe remained narrow and secondary infection occurred there twice during the 12 more months before death from a massive haemoptysis. No necropsy obtained.

CASE 9 (Whitwell, 1953).—Male; 48 years; slight cough for many years. Haemoptysis. Clinical examination reported negative. *Radiography*—collapse of apical segment right lower lobe. *Bronchoscopy*—thickened folds of mucous membrane in lower trachea, almost polypoid at carina; single very thick fold from carina into left main bronchus and several cornified folds into right main bronchus, narrowing it; discrete tumour "like a chondroma" in relation to orifice of apical bronchus of right lower lobe. *Biopsy*—submucosal amyloid infiltration. *Course*—No treatment. Reported symptom free and clinically and radiologically normal six months later.

Cases 10 and 11 are the new cases, already described in detail.

It is a pleasure to acknowledge encouragement and much wise and constructive criticism from Drs. Wilfred Oakley and Clifford Hoyle, and to thank Drs. Schottenfeld and McDonald for valuable follow-up reports on their cases, and Miss Amy Papazian for having so willingly and efficiently added to her secretarial duties. The drawings were executed by Mr. Leslie Fairweather.

REFERENCES

- Abercrombie, J. (1828). *Pathological and Practical Researches on Diseases of the Stomach, the Intestinal Canal, the Liver and other Viscera of the Abdomen*, 1st ed., Section 11, p. 339. Waugh and Innes, Edinburgh.
- Balsler, W. (1883). *Virchows Arch. path. Anat.*, **91**, 67.
- Burow, A. (1875). *Arch. klin. Chir.*, **13**, 242.
- Dickinson, W. H. (1879). *Trans. path. Soc. Lond.*, **30**, 511.
- Fagge, C. H. (1876). *Ibid.*, **27**, 324.
- Falconer, B. (1938). *Acta oto-laryng. (Stockh.)*, **26**, 353.
- Glockner, A. (1900). *Virchows Arch. path. Anat.*, **160**, 583.
- Gordon, W. (1955). *Brit. med. J.*, **1**, 825.
- Hallermann, W. (1928). *Frankfurt Z. Path.*, **36**, 471.
- Haynes, A. L., Claggett, O. T., and McDonald, J. R. (1948). *Surger*, **24**, 120.
- Herxheimer, G. (1903). *Virchows Arch. path. Anat.*, **174**, 130.
- Higgins, W. H., and Higgins, W. H., Jr. (1950). *Amer. J. med. Sci.*, **220**, 610.
- Kramer, R., and Som, M. L. (1935). *Arch. Otolaryng. (Chicago)*, **21**, 324.
- Lubarsch, O. (1929). *Virchows Arch. path. Anat.*, **271**, 867.
- Lunzenauer, K. (1952). *Frankfurt. Z. Path.*, **63**, 519.
- McDonald, J. R. (1957). Personal communication.
- Meyer, O. (1911). *Frankfurt. Z. Path.*, **8**, 304.

- Noring, O., and Paaby, H. (1952). *Acta path. microbiol., scand.*, **31**, 470.
- Reimann, H. A., Koucky, R. F., and Eklund, C. M. (1935). *Amer. J. Path.*, **11**, 977.
- Rokitansky, C. (1842). *Handbuch der speciellen pathologischen Anatomie*, vol. 11, pp. 311–312. Braumüller and Seidel, Vienna.
- Schmidt, H. W., McDonald, J. R., and Clagett, O. T. (1953). *Ann. Otol. (St. Louis)*, **62**, 880.
- Schottenfeld, A. (1957). Personal communication.
- Arnold, L. M., Gruhn, J. G. and Etess, A. D. (1951). *Amer. J. Med.*, **11**, 770.
- Stark, D. B., and McDonald, J. R. (1948). *Amer. J. clin. Path.*, **18**, 778.
- and New, G. B. (1949). *Ann. Otol. (St. Louis)*, **58**, 117.
- Virchow, R. (1858). *Die Cellularpathologie*, Hirschwald, Berlin. Eng. trans. by F. Chance (1860). *Cellular Pathology*, pp. 367–384. Churchill, London.
- Wainwright, J. (1737). *A Treatise of the Liver* appended to *A Mechanical Account of the Non-Naturals*, 5th ed., p. 19 and pp. 731–733. Clarke, London.
- Weismann, R. E., Clagett, O. T., and McDonald, J. R. (1947). *J. thorac. Surg.*, **16**, 269.
- Werdt, F. von (1908). *Beitr. path. Anat.*, **43**, 239.
- Whitwell, F. (1953). *Thorax*, **8**, 309.
- Wichmann, G. (1893). *Beitr. path. Anat.*, **13**, 487.
- Wild, C. (1886). *Ibid.*, **1**, 175.
- Wilks, S. (1856). *Guy's Hosp. Rep.*, Third Series, **2**, 103.