

SECTION III

THE HYPOGASTRIC ROUTE

THE MIDLINE EXTRAPERITONEAL HYPOGASTRIC ROUTE

This route allows us to reach and deal with various objectives such as the following :—

The pelvic stage of both ureters in relation to stone and stricture.

Femoral hernia, single or bilateral.

The blood supply of the prostate and of other pelvic organs.

The bladder pedicles in relation to cystectomy.

Obturator-nerve trunks (for bilateral resection in adductor spasm).

Hip-joint nerves in a complete exposure from in front.

I shall not deal with bilateral exposure of the pelvic stage of the ureter : stone and, in Egypt, stricture due to schistosomiasis have made this a matter of routine.¹

Use of the midline route for femoral hernia is sufficiently established. Retropubic prostatectomy has its own literature, and the simple bilateral *pelvic* resection of obturator-nerve trunks for adductor spasm needs nothing but mention in the paragraphs on complete exposure of hip-joint nerves (p. 171).

I shall deal with only two objectives, each in relation to one of the following procedures :—

1. Prelusive vascular control in extraperitoneal prostatectomy.

2. Complete exposure of hip-joint nerves by anterior access.

But though the midline route itself, aside from a particular objective, has seen long service, some of its features still need notice.

¹ I have described these strictures and their treatment in the section 'Schistosomiasis' *British Surgical Practice*, vol. vii, 1950.

INCISION: 'RETZIUS': CLOSURE

Skin incision and rectus separation.—Owing to the slight overlap (unpredictable as to side) that occurs below the navel at the medial borders of the recti, and owing also to the fact that only *there* is linea alba actually linear, clean separation of the recti is often missed; incidentally, too, midline incision in this part usually opens both rectus sheaths. Separation, however, is easy to effect, since the recti—as at a traffic roundabout—pass the navel on opposite sides. If, then, we prolong the top of our midline incision to skirt the navel (Fig. 100), we can there expose

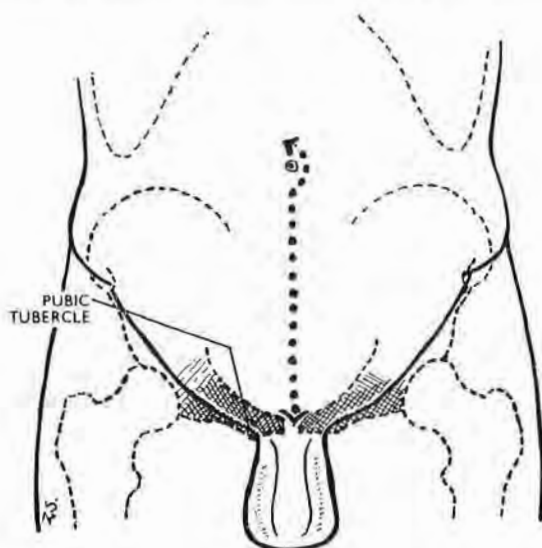


Fig. 100

For a clean and complete access to 'Retzius' the midline incision meets the pubic symphysis and goes to skirt the navel.

the wide umbilical parting of the muscles, and follow down their cleavage to the symphysis. And, if we require maximal exposure of the lateral pelvic limbs of 'Retzius,' rectus separation *should* reach that level—leaving the joint unscotched.

The space of Retzius.—The midline hypogastric route allows us to open and explore the pelvic part of the potential space of Retzius. (The *abdominal* part goes up towards the navel between the two obliterated umbilical arteries.) The large pelvic component is frequently and wrongly called 'retropubic' or 'prevesical'—naming the whole space from the smallest part. Its full extent

spreads far from the 2 in. width of pubic bodies and the sharp bows of the empty bladder, going obliquely back a further handbreadth on either side. Here it separates the inferolateral vesical surfaces from structures that are either lightly held or firmly fixed to the side walls of the true pelvis.

The ground plan of the opened *pelvic* portion of the space is, therefore, like a massive U whose thick loop lies behind the symphysis, while the somewhat splayed-out limbs spread backwards and embrace the sides of the bladder. These limbs end posteriorly, to right and left, at a frontally disposed septum. This important structure carries the ureter from the pelvic wall to the bladder in company with relevant vessels. In the male it includes those vessels that supply the organs sandwiched by the two layers of rectovesical fascia—the vesicles and vasa. Each of these two isolable septa forms, to right or left, a bladder *pedicle*, and thus becomes a major key to radical cystectomy. (Through the courtesy of Mr T. J. D. Lane, I had the privilege of demonstrating the potential value of these two pedicles in regard to that operation before a distinguished group of visiting British urologists at the Meath Hospital, Dublin, in October 1947.)

The surgeon opening the space of Retzius by stripping up pelvic peritoneum exploits and magnifies the change produced by a filling bladder. For this reason, in the absence of previous infection, the peritoneum lifts easily and, if gently handled, without hæmorrhage.

Stripping pelvic peritoneum.—This, I find, is done best by beginning anterolaterally, towards the *side* of the bladder rather than straight in front.

Adherent structures.—In the male four things related to the pelvic part of 'Retzius' adhere normally to *raised* peritoneum in some at least of their extent: (1) the urachus; (2) the obliterated umbilical artery in its distal, or front, portion; (3) the vas as it lies between the internal ring and the back of the empty bladder; (4) the upper and major length of the pelvic stage of the ureter.

Two of these structures will be seen or felt as cords crossing the opened space: (*a*) the proximal and pervious part of the umbilical artery—free of peritoneum—slopes up and inward either from the end of the undivided internal iliac trunk, or from the beginning of its anterior division, to reach the side of the bladder; (*b*) the vas deferens—stuck tightly to peritoneum—goes to reach the *back* of the bladder at a higher level than the umbilical artery.

As peritoneal stripping proceeds, the vas comes to lie at the forward and concave edge of a peritoneal fold that forms a shelf above the posterior limb of 'Retzius.'

Rectus-sheath closure.—When separation has been carried *right* down to the pelvic symphysis, a precautionary stitch is advisable; otherwise a hernia may show at the upper edge of the joint in a matter of weeks. For that reason I have found it well to place a single mattress suture in the divided aponeurosis at this level, bringing the two deep faces of sheath flatly together like the palms of hands. The rest of the aponeurotic layer can be closed with a 'running mattress,' leaving a low ridge of sound union palpable through skin.

JUXTASYMPHYSEAL HERNIA AFTER MIDLINE INCISION

A neglected detail of anatomy perhaps explains the need for placing the single mattress suture immediately above the symphysis. The linea, a fingerbreadth below the navel, becomes a strip whose thin edges look front and back; its width (because of slight rectus overlap) lies in a plane a trifle off the sagittal. Towards their pubic ends the two thin *edges* of linea (anterior and posterior) widen out, most often like river deltas (Fig. 101), though sometimes the hinder edge may thicken and bifurcate. These anterior and posterior widenings are known as the *feet* of linea.

The two feet of linea alba.—The *anterior* (and lesser) widening, or foot, shows a featureless triangular surface whose base gains attachment to the anterior and upper border of the symphysis and pubic crests. It lies concealed behind the *superficial* suspensory genital ligament (the fundiform or sling) that is attached to linea and joins on either side with Scarpa's fascia. (The *deep* suspensory ligament springs from the symphysis and linea.)

The widening of the *posterior* edge of linea goes to the corresponding upper border of symphysis and pubic crests. It is unsuitably called the *adminiculum* or *prop* of linea alba. (Paturet's 'posterior foot,' in spite of tradition, is a better term, which pairs well with its anterior fellow.) This hinder foot, or 'adminicular' widening, is sometimes simple and imperforate like the forefoot; more often it either forks before reaching the symphysis, or else is pierced at the centre of its triangular face. These openings, whether forked or perforate, transmit a *cul-de-sac*

of thinned out transversalis fascia that goes a thumbwidth forward between the lower parts of the two recti and ends behind the blank triangular face of the forefoot. The sac is filled with

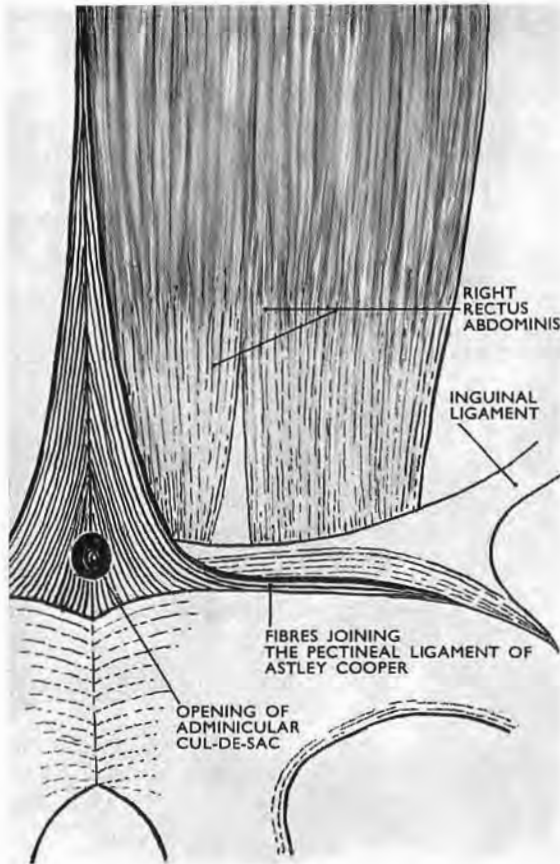


Fig. 101

The so-called prop (the *adminiculum*) of linea alba, seen from behind. The variety shown here has an opening that leads into a fascial *cul-de-sac*, filled normally with fat—a combination which, if unregarded, may favour juxta-symphyseal hernia after a low midline section of the rectus sheath. (The adminicular opening is sometimes arched. It may be absent.)

extraperitoneal fat supplied by a twig from the pubic branch of the inferior epigastric artery.

Thus, when the anterior end of the *cul-de-sac* is unmasked or split by a midline incision that reaches the symphysis and cuts through the fibrous barrier provided by the forefoot of linea plus portions of the two suspensory ligaments, a path may open for

the sort of hernia which calls for a deterrent juxtasympyseal 'mattress.'

I have seen three of these post-operative protrusions immediately above the symphysis, small at first but soon expanding.

PRELUSIVE VASCULAR LIGATION IN PROSTATECTOMY¹

The wide access we obtain to the pelvic part of the space of Retzius by the midline route (p. 161) suggests a means of controlling blood supply as a first step in extraperitoneal prostatectomy.

Control of blood supply at *source*, which is the rule in thyroid resection, is not a recognised procedure in dealing with the prostate. Yet in open prostatic surgery the loss of blood will often fall on persons unsuited by their age for ordinary deprivations.

The blood supply of the prostate comes through branches that spring directly or indirectly from the internal iliac artery, but we cannot count much on diminishing the arterial inflow to the prostate (or indeed to any other pelvic organ) by tying that main trunk: its anastomoses with offsets that stem at pelvic level from the external iliac, and in the thigh from profunda femoris, are far too free.

We are thus led to seek for vessels that reach the gland directly, and in particular the vessels *named* prostatic. They, in presence of moderate glandular enlargement, may have calibres equal to the average bore of radial arteries—a fact which on ordinary grounds would seem to call for their ligation as a first step in open prostatectomy. I say 'seem' advisedly, because countless successful operations have been performed without thought for any bleeding excepting that from ultimate prostatic twigs.

It would none the less be interesting to know in what proportion of these fortunate patients there has been significant bleeding after operation, and, more recently, to learn how many have received post-operative blood transfusion.

Supposing then that we should wish to limit the blood supply of the prostate before operation as we do that of the thyroid, we must first review the visceral branching of the internal iliac artery in relation to the space of Retzius.

¹ The work embodied here was completed in 1952. It was published in the *Irish Journal of Medical Science*, August 1954.

VISCERAL BRANCHES OF THE INTERNAL ILIAC ARTERY

The origins of these branches vary so much that Poirier (*Traité d'Anatomie Humaine*, 1902, vol. ii, fasc. 2, p. 786)

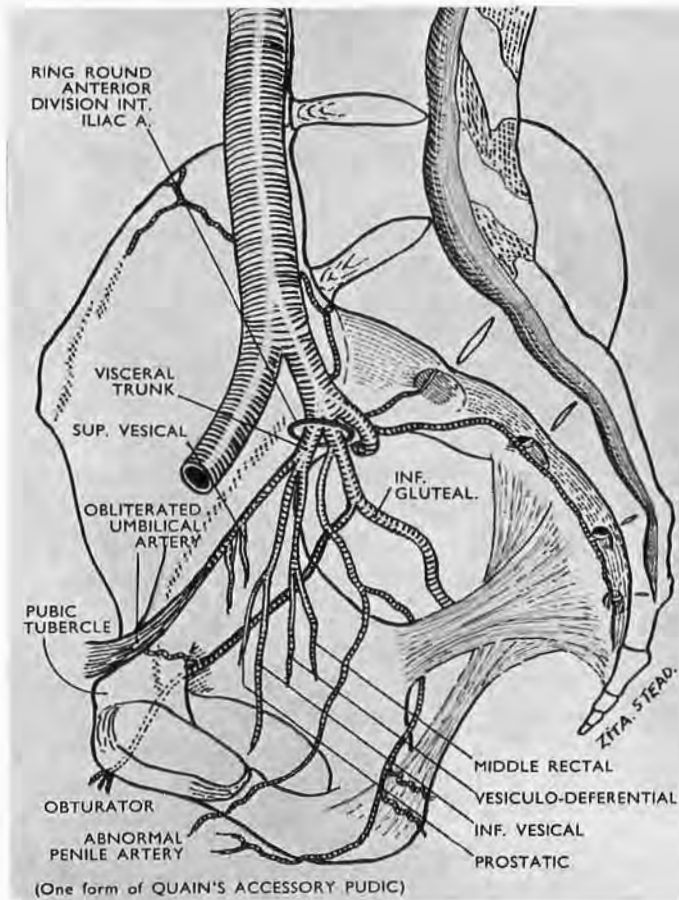


Fig. 102

High 'terminal' forking of the anterior division of the internal iliac into pudental and inferior gluteal (*alias sciatic*) arteries.

abandons the attempt to give average accounts of how they spring from parent stems. Thus, to quote extreme cases, they may arise (1) like tentacles, as a single bunch from the anterior limb of the internal iliac trunk—as if their several stems were absorbed at one place into it (Fig. 102); or (2) they may spring separately along its length (Fig. 103). Between these extremes of concentration and dispersion there is a rich variety of pattern.

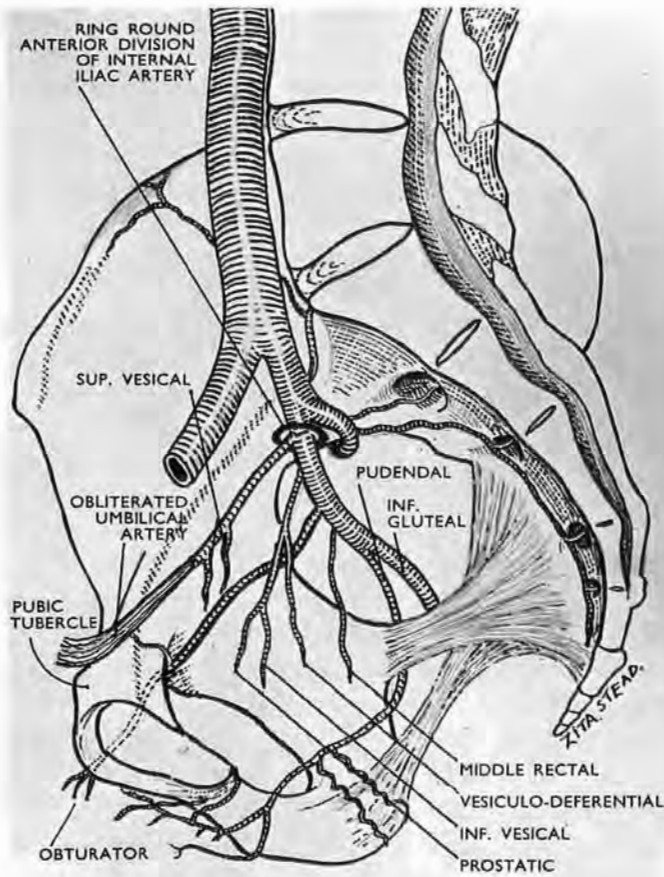


Fig. 103

Low 'terminal' forking of the anterior division of the internal iliac into pudendal and inferior gluteal (*alias sciatic*) arteries.

Poirier therefore begins his account by refusing to classify *origins* of visceral branches, and describes them instead according to their goals. He does this, for the male, as follows :—

<i>Visceral Branches of the Internal Iliac Artery</i>	}	Anterior or vesical	}	Obliterated umbilical giving superior vesical
				Inferior vesical
		Intermediate or genital	}	Prostatic
	Vesiculodeferential			
		Posterior or rectal—		Middle rectal

Our first object is to identify these arteries so that we can tie relevant vessels at points immediately prior to their distribution. It is also important to leave sufficient blood supply for the bladder and prostatic bed, and to avoid damaging the penile inflow.

These requisites call for a rapid survey of internal iliac branchings, whose pattern on the two sides of the pelvis is often asymmetrical and sometimes widely different. There is, too, a further complication.

Intrapelvic penile arteries.—Poirier's table has the merit of showing the common distributive order of visceral branches from before back, but interloping arteries may break in. These are most often penile arteries that have an intrapelvic course—an arrangement so frequent that Vesalius gave it as orthodox.¹ The vessels may come from the obturator or the inferior gluteal (the old sciatic) artery; but far more commonly the whole main stem of internal pudendal is as it were diverted from the ischiorectal fossa to course *above* levator ani and reach the penis through the space of Retzius (Figs. 102 and 104).

In virtue of their goal all intrapelvic penile arteries before emerging from the pubic arch will closely *precede* prostatic branches. It is well, therefore, to keep lively watch for this Vesalian breach with orthodoxy lest we tie the wrong artery.

A survey on both sides of the pelvis will also prevent unwise ligation of common stems. Thus, if an inferior vesical artery gives rise to the prostatic and to the vesiculodeferential vessels, its closure may compromise the blood supply to the prostatic bed or to the bladder. So, if we are to have the chance of testing effects of transient occlusion, the patterns of *origin* as well as those of distribution must be producible for prompt assessment.

These considerations stress the need for some physical means that will literally and quickly find and *bring out* the relevant pattern of internal iliac branching. The want is met by the obliterated umbilical artery which—used as a leash—can be made to serve both as clue and as tractor (Fig. 104).

The arterial leash.—The umbilical artery is a constant feature; it varies little, aside from the extent of its patency and the number of its vesical branches. It springs from the extreme end of the internal iliac *trunk*. Fortunately for our purpose, this origin gives the leash attachment to the precise spot where traction best brings out the pattern of visceral branching. The leash then crosses the hinder part of the space of Retzius, going obliquely up, forward,

¹Poirier (*loc. cit.*, p. 808) quotes Krause to this effect.

and in to, the side of the bladder, where it clings to the vesical wall, lying just below the flat upper face of the empty viscus. Leaving the front of the bladder it again crosses 'Retzius,' this

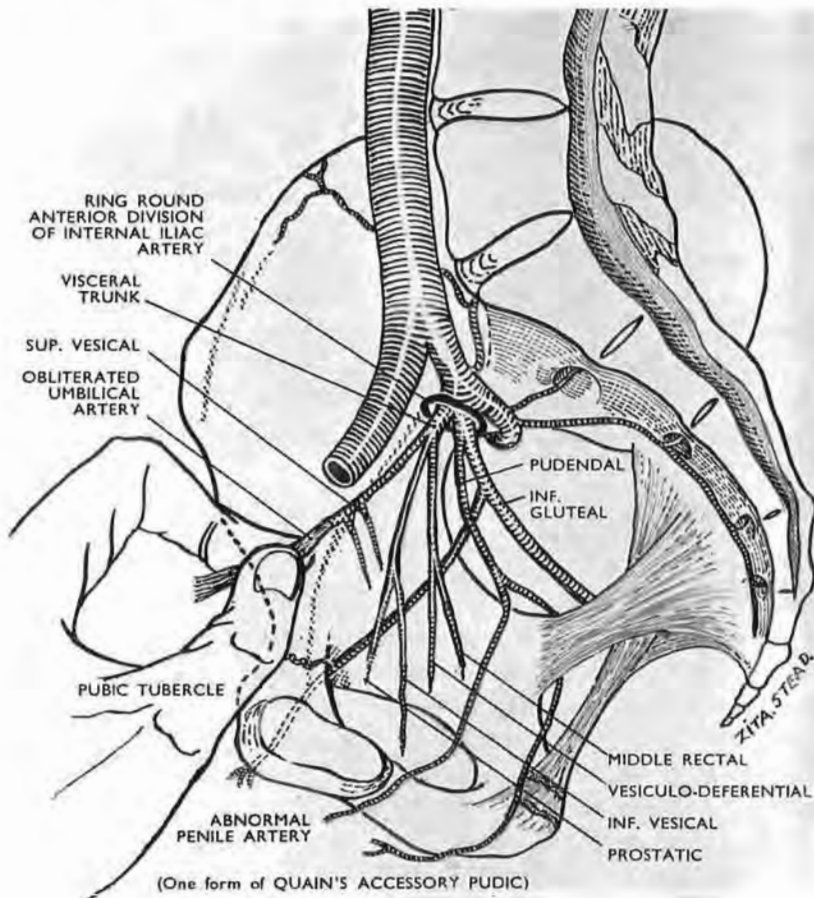


Fig. 104

The obliterated end of the umbilical artery freed from the pubis and used as a tractor

This yields an ideal windfall ; from it sprang the axial vessel which became the parent stem of every artery that serves the limb—and half its girdle. Traction made thereon elicits in particular the *visceral* pattern of pelvic branching on the ipsilateral side.

time through its prevesical part, and reaches the pelvic wall in the region of the pubic tubercle ; from there it slopes up to the navel.

As a rule the vessel loses its lumen while it lies on the side of the bladder, and before the lumen shuts it gives off one, two, three, or rarely four superior vesical arteries ; it may, however, be patent up to the navel.

Most commonly we find the vessel first as a whitish band flattened by contact with the pubis and raised with the peritoneum, to which it sticks. If we separate this band towards the pelvis, we are supplied with the tough handle of a leash whose deep end is attached to the source of visceral arteries. With it—if used discreetly—we can draw their whole ipsilateral pattern sufficiently away from the pelvic wall to let us recognise and test constituent vessels from stem to distribution.¹ This can be done because the pattern is elastic and is *thinly* pasted to the pelvic wall by a translucent areolar covering from which we have already detached the thick sheet of parietal peritoneum.

Two precautions are essential: gentleness first, for the pull will pass from the fibrous handle of the leash to the softer patent portion, and thence by way of the anterior limb of the internal iliac trunk to the pattern of branches; secondly, the pull should be made in the antero-mesial direction in order to reduce strain on the often delicate superior vesical twigs that leave the unobliterated reach of the artery.

THE ARTERIAL SUPPLY OF THE PROSTATE

The prostatic artery comes from the anterior limb of the internal iliac trunk, though seldom directly. It shares more often a common stem with the inferior vesical, or with the middle rectal and vesiculodeferential arteries. It may even spring from the patent part of the obliterated umbilical, being then merely an enlargement of one of the fine anastomotic twigs which normally link the two vessels. These fine twigs are liable to rupture when we open the space of Retzius, and their value in maintaining a residual supply to the prostatic bed must be uncertain. (The risk of confusing prostatic and intrapelvic penile arteries has already been stressed.)

The vesiculodeferential artery generally arises in common with the prostatic and middle rectal. It passes between the two stout layers of rectovesical fascia which enclose and sandwich the seminal vesicles together with the ends of the ureters and the ends of vasa deferentia. After branching widely to supply the front of the vesicle, the artery sends branches to the base (or postero-inferior aspect) of the bladder, and so to the prostatic bed. The deferential artery is given off above the branching,

¹ It is likely that the small non-damaging clamps used for *temporary* vascular occlusion will serve in testing residual vascularity in the prostatic bed.

and its fine descending twig goes with the vas to the prostate. (An ascending recurrent twig follows the vas to reach the epididymis and anastomose with the testicular artery—a link which is broken by vasectomy.)

SUMMARY

These paragraphs suggest that in prelude to certain prostactomies (1) the whole pelvic part of the space of Retzius be opened up; (2) that the obliterated umbilical artery be used on either side as a tractor leash which will bring out the variable pattern of visceral pelvic arteries for recognition, assessment, and possible ligation.

My own work of necessity was done on bodies prepared for the dissecting room and my thanks are therefore due to my colleague Mr W. A. L. MacGowan, F.R.C.S.I., who has confirmed the innocuous and satisfactory effect of adequate traction on the obliterated umbilical artery at post-mortem in *fresh* cadavers of very different age and obesity: in each the pattern of visceral branching was plainly elicited. It has been a pleasure to have the help of so accurate and critical an observer.

COMPLETE ACCESS TO HIP-JOINT NERVES FROM IN FRONT¹

Current procedures on arthritic hips include resection of nerves that bring painful stimuli from the joint, and if the surgeon deals first with anterior nerves and then with posterior, his patient will be turned from a supine to a prone position.

With that change from recumbency to 'face down' goes a threefold nuisance, viz., the need for incisions front and back; renewal of sheets and towels; the chance of shock.

The object of this paper is to show that *all* nerves to the hip joint can be reached, exposed, and resected *from in front* in the recumbent patient, with a maximum regard to anatomy and a negligible sacrifice of muscle innervation.

THE TWO METHODS

(A) If the surgeon has no scruple about denervating the main mass of the adductor group, he will take the simple course of dividing the obturator *trunk* on the side wall of the pelvis after

¹ T. P. Garry and A. K. Henry, *Irish Journal of Medical Science*, April 1953, p. 177.

he has displaced the peritoneum. In that event an abdominal extraperitoneal approach suffices, and the incision (excepting for a small extension at the navel) is mesial and hypogastric. But use of (A) prevents resection of certain contributions from the femoral nerves.

(B) If, on the other hand, he should think it well to hesitate

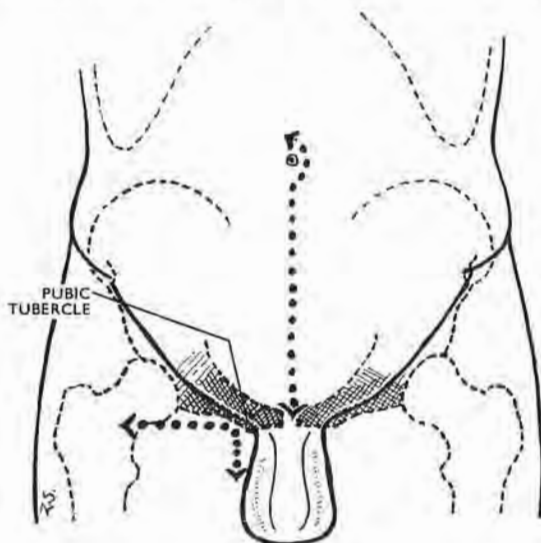


Fig. 105

The two incisions

The **abdominal incision** is the same as that used by one of us for extraperitoneal access to the lowest part of both ureters. (The extension at the navel allows *clean* separation of the recti, since that is where they separate (p. 161).)

The **thigh incision** (a) lets us liberate parts of the obturator nerve below the obturator tunnel and thus makes possible our 'pull-through' technique; (b) gives access to extra-abdominal recurrent contributions from the femoral nerve to the front of the hip joint (Figs. 106 and 107).

before he gravely jeopardises muscles of adduction—known abroad as 'muscles of chastity' though taking part as well in usual, uncanonised activities—then, in the case of such demur, the surgeon will add a *thigh* incision (Fig. 107).

This extra cut allows him to spare the branches of the obturator nerve that supply the bulk of the adductor mass while he resects those obturator twigs that serve the hip joint.

The thigh incision, too, gives access to certain *femoral* branches that carry articular nerves.

Whether he chooses (A) or (B) the surgeon stands on the side of the patient remote from the seat of operation.

METHOD B.—Let us suppose Method B is used. The obturator nerve, after peeling off peritoneum, is found at once on the side wall of the pelvis, lying directly above the companion artery and

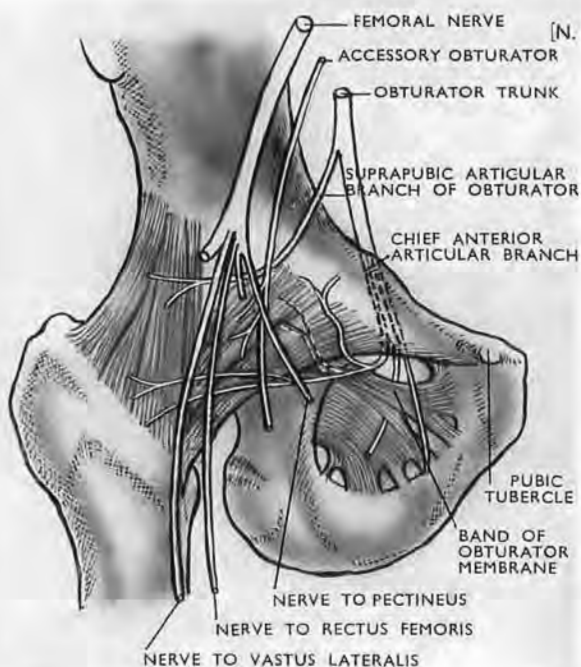


Fig. 106

Anterior nerve to the hip joint (after Paturet)

Note the unlabelled dotted twig, deep to pubofemoral ligament. This twig forms part of a neurovascular bundle that makes a constant but undescribed groove at the 'exit' of the obturator tunnel (see text). This 'exit' is often masked by a well-developed pubofemoral ligament, which then requires division for access to anterior offsets.

vein. Mobilise the nerve as far up as possible, then loosen it and its divisions at and through the $\frac{1}{2}$ in. length of obturator tunnel, in which the nervous structures keep their superior relation to artery and vein. This mobilisation lets us note whether—as in 12 per cent. of subjects—the nerve lying on the pelvic wall gives off a suprapubic articular branch (Fig. 106, after Paturet) *before* entering the obturator tunnel—a branch which, of course, we cut.

The thigh incision.—Next, passing to the thigh, find first the pubic tubercle. At this level make a hockey-stick incision with a

short limb descending for 2 in. from the tubercle down the thigh, and a long *transverse* limb measuring a wide handbreadth outwards from the tubercle (Fig. 105). From this tubercle the plane of cleavage between pectineus and adductor longus slants down and out. Open the plane and part these muscles widely, but, if pectineus is thick and resistant, sever the medial half of the belly from its J-shaped linear attachment to the pectineal face of pubis and turn the muscle outwards. With either means, pectineus buffers the femoral vein whose upper end lies in the groove between pectineus and psoas.

The superficial opening, or 'exit,' of the obturator tunnel can then be reached from the thigh, but the upper portion of the 'exit' is still masked by an overhang of the part of the pubo-femoral ligament that goes medially to join the pubic tubercle (Fig. 106) and sometimes, too, by an associated piece of obturator externus muscle.

The *anterior division* of the obturator nerve is found at once as it passes down from the tunnel's 'exit' over the outer face of the outer obturator to supply the *front* of adductor brevis. The upper course of the *posterior division* varies; it may run in front of, through, or deep to obturator externus: and when it lies deep to the muscle, it may also go deep to a strong outlying band of obturator membrane—which the French call by, what is to us, the misleading name of 'subpubic ligament'—a band which may be strengthened by an offshoot of fibres from the pubofemoral (Fig. 106).

The obturator nerve and the 'pull-through' method.—Our object is to mobilise a whole segment of the obturator nerve together with its branches—a segment that lies above, in, and below the obturator tunnel—so that we can get a to-and-fro 'pull-through' movement of the nerve constituents. The obturator branches now appear and can be classed very simply as *thick* and *thin*. The thick we spare; they go to adductor muscles. The thin, which include anterior articular branches to the hip, are indiscriminately cut. This, of course, means that branches going to obturator externus and perhaps to pectineus are sacrificed. The sacrifice is minimal. Downward traction on the two obturator divisions—which now begin to slide through the obturator tunnel—drags on the small articular twigs, so that they are seen to run *proximally* from the parent trunks. One of these is very constant; it turns backwards from the parent stem and helps, with offsets from the obturator vessels, to make a

definite but undescribed groove on the hinder lip of the obturator 'exit' within a fingerbreadth of its arched top. The nerve then passes through the acetabular notch bridged by the transverse ligament. There is a certain risk of missing twigs, like this one, that arise just within the tunnel's 'exit,' when they are masked by an overhang of pubofemoral ligament (Fig. 106). For that reason it is well to divide the overhang in order to see these offsets springing from main divisions.

The accessory obturator nerve.—This nerve, described first by Schmidt in 1774, occurs (on the average of findings by six different authors) in 17 per cent. of subjects. It will be looked for above the pelvic brim, descending vertically in front of and often touching the obturator trunk, which should be stroked gently with a ball-ended dental burnisher to avoid missing an adherent but easily separable accessory obturator. Lower down it becomes more difficult to reach, for it may lie deep to the external iliac vein and run within the psoas sheath before going under Poupart's ligament to supply pectineus, hip joint, skin, and femoral artery.

The chief and most constant anterior articular branch to the hip springs from the back of the obturator trunk (Fig. 106), or from the posterior division of the trunk, just before or just after the trunk enters the obturator canal—a variation that lends value to the 'pull-through' technique which delivers the branch for section when the trunk is drawn up towards the pelvic cavity. The *back* of the trunk or the back of its posterior division will then be stroked with the burnisher, and any *thin* branch that the ball-end separates off will be resected in due conformance with our classification of 'thick' branches to be saved and 'thin' to be cut.

Femoral branches to the joint.—Twigs to the hip joint stem from three branches of the femoral trunk:—

(1) *From the branch to pectineus* which goes behind the femoral sheath. It has its origin, however, within the abdomen and leaves the parent trunk *above* and very close to Poupart's ligament. (Soulié, in Poirier and Charpy's *Anatomie*, describes *two* nerves to pectineus—one from the femoral trunk; one from its so-called internal musculocutaneous division (see footnote, p. 231).)

The branch or branches slope inwards from the trunk and, therefore, can be hooked by drawing the dental burnisher *up* along the medial edge of the femoral nerve, after that nerve has been clearly defined.

(2) and (3) *From branches to rectus femoris and from branches to vastus lateralis.*

These are small recurrent *upper* branches to the muscles. They reach the lateral part of the anterior face of the hip joint, and may either form a plexus on the joint or unite before they reach it or spring from a common stem. They are the first lateral offsets that leave the femoral nerve in the *thigh*.

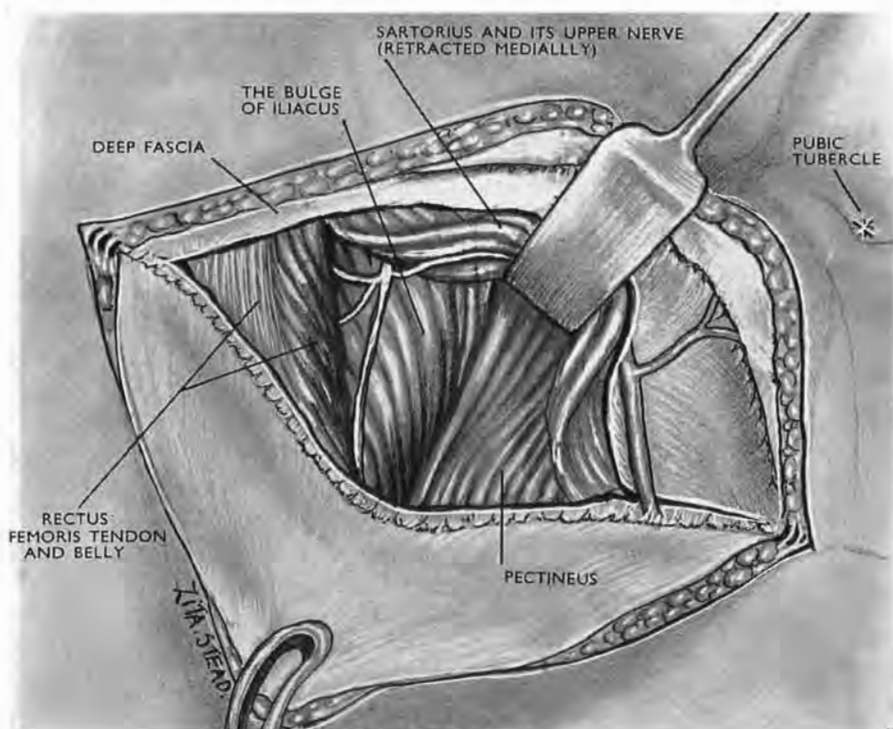


Fig. 107

The transverse part of the thigh incision opened up

Two proximal branches of the femoral nerves are seen passing deep to rectus femoris. In this subject they sprang from a common stem: one branch supplied rectus, the other vastus lateralis; each ended in recurrent twigs to the front of hip joint.

These branches are easily found through the transverse part of the thigh incision. Mark a point level with the pubic tubercle and distal by one handbreadth to the anterior superior spine of ilium. At this point displace sartorius medially; separate rectus femoris from vastus lateralis. Then you will see the forward bulge of iliacus belly (*lateral* to its attachment to psoas tendon). The nerve, or nerves, to rectus femoris and vastus lateralis pass obliquely down and out on the steep slope of this forward bulge. Still farther out they turn up towards the joint (Fig. 107).

It is difficult to isolate the tiny articular twigs that spring from these recurrent branches; and since the branches themselves are small, and since they form only a minor fraction of the large nerve supply to rectus femoris and vastus lateralis, they may be resected without anxiety.

POSTERIOR NERVES TO THE HIP JOINT

Approached from in front, after reflecting pelvic peritoneum, these nerves, despite their depth, are easier to deal with than the anterior nerves we have just reviewed: their stems are found in close and definite relation to a single bony point—the spine of ischium; they spring from the *front* of the sciatic trunk; they can be felt and picked up blindfold after dividing a single layer of fascia.

In general, *one* nerve (Fig. 108)—that shared by the quadratus femoris and gemellus inferior—gives a branch to the back of the hip joint. The articular twig, however, may be double, and in 12 per cent. of subjects it is supplemented by a further twig that comes *direct* from the sciatic trunk and may itself be double (Paturet).

The nerve to quadratus and Garry's manoeuvre.—Stand on the side of the patient *remote* from the seat of operation. Separate the peritoneum from the side wall of the true pelvis until you can feel the curved anterior edge of the greater sciatic notch. At the caudal end of the notch locate the spine of ischium. A strong but loose sheet of fascia occludes the bight of the notch. *Open the fascia a fingerbreadth headwise to the spine of ischium.* Make an inch-long opening. For the patient's *right* side use the longest finger of your *left* hand, turning its palm towards the patient's head. Use a right finger for the patient's left side. Pass the finger

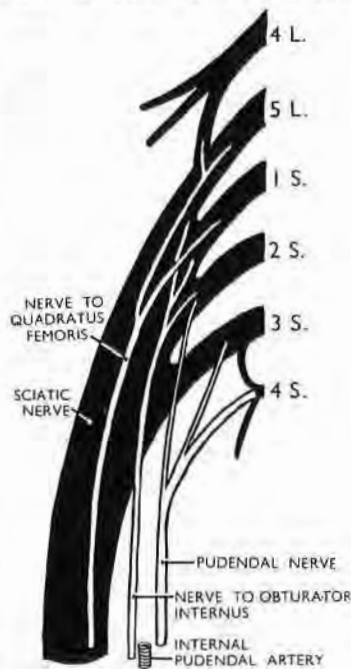

Fig. 108
The pelvic part of right sciatic trunk

A front view showing the order in which branches leave its anterior face. The quadratus branch is the most lateral.

through the opening you have made in the fascia; the soft resistance that you feel is the sciatic trunk.

With the finger press the trunk gently backwards towards the table. Flex the finger tip towards the spine of ischium. The

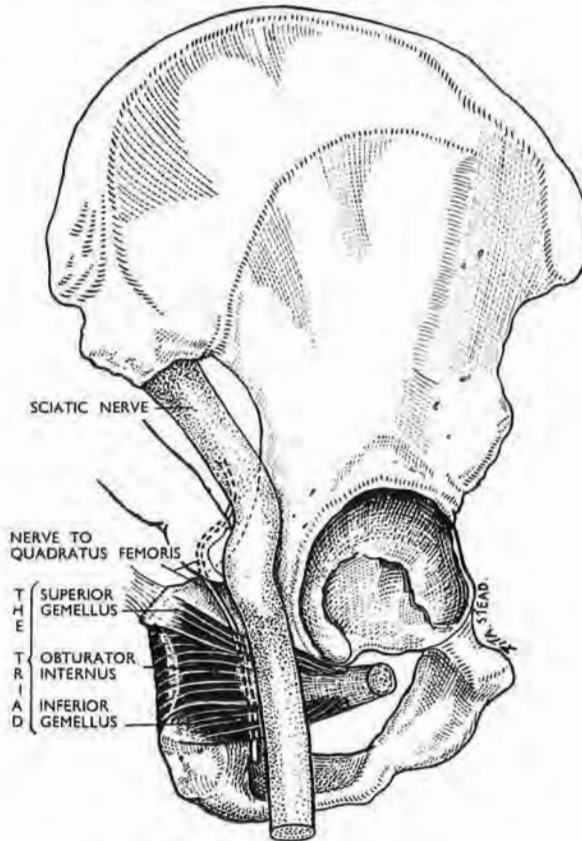


Fig. 109

Quadratus nerve and sciatic trunk

The diagram shows how a muscle triad (a) parts the nerve from its parent trunk; (b) straps the nerve to the bone. The free trunk, therefore, moves back when a finger thrusts against it from in front, but the nerve stays forward and is felt *in situ*.

firm, thin cord now felt crossing the pulp of the finger is the nerve to quadratus femoris, and any other similar cord found at this level (a fingerbreadth headwise to the spine of ischium) is either a twin nerve to quadratus or the occasional direct articular branch from the sciatic trunk.

Anatomical relations (Fig. 109) make this simple manœuvre

feasible. Just below the level of our fascial opening the *back* of the nerve to quadratus (with its articular twigs) is crossed by a transverse muscle triad—gemelli plus obturator-internus tendon; the triad straps the nerve to the back of ischium. The sciatic trunk, on the other hand, from which the nerve to quadratus springs, lies free *behind* the triad and, at the level of our opening, is backed by the loose belly of piriformis. For that reason a finger pushing through the opening thrusts the yielding, unfettered trunk dorsally towards the table, while the nerve to quadratus—caught between triad and bone—stays ventrally and feels like tight string. (This interpretation, like the manoeuvre, is Garry's—each of them a *tour de maître*.)

We would add that caudal to the site of the quadratus nerve three structures hug the spine of ischium. From without inwards, these are :—

(1) The nerve common to obturator internus and gemellus superior; (2) the pudendal vascular bundle; (3) the pudendal nerve (Fig. 108). We need disturb none of them, though if we cut the thin nerve shared by obturator internus and gemellus superior it would scarcely matter.

Before attempting these procedures, the surgeon will waste no time if he consults Gimbernat's favourite text-book of anatomy—the cadaver.

Soon after this paper appeared the operation we described was carried out at the Richmond Hospital, Dublin, through the initiative of my former colleague, Mr W. A. L. MacGowan, by Mr C. Gleadhill, then Assistant in the Department of Neurosurgery. The patient, a man over 70, was bedridden with marked osteoarthritic changes in both hip joints. A month after a bilateral resection of hip joint nerves he walked to his church and back, a total distance of about a half mile.

