Author Manuscript

Author Manuscript

Author Manuscript

Author Manuscript

HHS Public Access

Author manuscript

Clin Microbiol Infect. Author manuscript; available in PMC 2019 June 01.

Published in final edited form as:

Clin Microbiol Infect. 2018 June ; 24(Suppl 2): S95–S107. doi:10.1016/j.cmi.2018.01.030.

ESCMID Study Group for Infections in Compromised Hosts (ESGICH) Consensus Document on the safety of targeted and biological therapies: an Infectious Diseases perspective (Immune checkpoint inhibitors, cell adhesion inhibitors, sphingosine-1-phosphate receptor modulators and proteasome inhibitors)

Gil Redelman-Sidi[1], **Olivier Michielin**[2], **Carlos Cervera**[3], **Camillo Ribi**[4], **José María Aguado**[5,6], **Mario Fernández-Ruiz**[5,6], and **Oriol Manuel**[7]

[1]Service of Infectious Disease, Department of Medicine, Memorial Sloan-Kettering Cancer Center, New York, USA [2]Department of Oncology, Centre Hospitalier Universitaire Vaudois and University of Lausanne, Lausanne, Switzerland [3]Department of Medicine, University of Alberta, Edmonton, Alberta, Canada [4]Department of Immunology and Allergy, Centre Hospitalier Universitaire Vaudois and University of Lausanne, Lausanne, Switzerland [5]Unit of Infectious Diseases, Hospital Universitario “12 de Octubre”, Instituto de Investigación Hospital “12 de Octubre” (i+12), Madrid, Spain [6]Spanish Network for Research in Infectious Diseases (REIPI RD16/0016), Instituto de Salud Carlos III, Madrid, Spain [7]Department of Infectious Diseases, Centre Hospitalier Universitaire Vaudois and University of Lausanne, Lausanne, Switzerland

Abstract

Background—The present review is part of the ESCMID Study Group for Infections in Compromised Hosts (ESGICH) Consensus Document on the safety of targeted and biological therapies.

Aims—To review, from an Infectious Diseases perspective, the safety profile of immune checkpoint inhibitors, LFA-3-targeted agents, cell adhesion inhibitors, sphingosine-1-phosphate receptor modulators and proteasome inhibitors and to suggest preventive recommendations.

Sources—Computer-based MEDLINE searches with MeSH terms pertaining to each agent or therapeutic family.

Corresponding author: Gil Redelman-Sidi. Service of Infectious Disease, Department of Medicine, Memorial Sloan-Kettering Cancer Center, 1275 York Ave, New York, NY 10065, USA. redelmansidi@hotmail.com.

Publisher's Disclaimer: This is a PDF file of an unedited manuscript that has been accepted for publication. As a service to our customers we are providing this early version of the manuscript. The manuscript will undergo copyediting, typesetting, and review of the resulting proof before it is published in its final citable form. Please note that during the production process errors may be discovered which could affect the content, and all legal disclaimers that apply to the journal pertain.

Conflict of interest disclosure: C.C. received personal fees from Novartis, Sunovion and Merck. J.M.A. received personal fees from Pfizer, Astellas and Merck. The remining authors declare no conflicts of interest (i.e., payment or services from a third party; relevant financial activities outside the submitted work; or patents planned, pending or issued broadly relevant to the sumitted work).

Author Manuscript Author Manuscript Author Manuscript Author Manuscript

Content—CTLA-4- and PD-1/PD-L1-targeted agents do not appear to intrinsically increase the risk of infection, but can induce immune-related adverse effects (irAEs) requiring additional immunosuppression. Although CD4+ T-cell lymphopenia is associated with alefacept, no opportunistic infections have been observed. Progressive multifocal leukoencephalopathy (PML) may occur during therapy with natalizumab (anti-α4-integrin monoclonal antibody [mAb]) and efalizumab (anti-CD11a mAb), but no cases have been reported to date with vedolizumab (anti-α4β7 mAb). In patients at high-risk for PML (positive anti-JC polyomavirus serology with serum antibody index >1.5 and duration of therapy ≥48 months), the benefit/risk balance of continuing natalizumab should be carefully considered. Fingolimod induces profound peripheral blood lymphopenia and increases the risk of varicella-zoster virus (VZV) infection. Prophylaxis with (val)acyclovir and VZV vaccination should be considered. Proteasome inhibitors also increase the risk of VZV infection, and antiviral prophylaxis with (val)acyclovir is recommended. Anti-*Pneumocystis* prophylaxis may be considered in myeloma multiple patients with additional risk factors (i.e., high-dose corticosteroids).

Implications—Clinicians should be aware of the risk of irAEs and PML in patients receiving immune checkpoint and cell adhesion inhibitors, respectively.

Keywords

ipilimumab; nivolumab; pembrolizumab; alefacept; natalizumab; vedolizumab; progressive multifocal leukoencephalopathy; fingolimod; proteasome inhibitors; infection

Introduction

The present review paper is part of a larger effort launched by the ESCMID (European Society of Clinical Microbiology and Infectious Diseases) Study Group for Infections in Compromised Hosts (ESGICH) and aimed at analyzing, from an Infectious Diseases perspective, the safety profile of biological and targeted therapies. By means of a set of unrestricted computer-based MEDLINE (National Library of Medicine, Bethesda, MD) searches based on the MeSH terms appropriate for each agent or therapeutic family, we identified literature pertaining to the subject. In addition, package information and boxed warning alerts from regulatory agencies (European Medicines Agency [EMA] and US Food and Drug Administration [FDA]) were reviewed. Methodological details are provided in the Introduction section of the present Supplement issue [1]. For each agent (or class of agents), a common outline is offered: (a) summary of mechanism of action, approved indications and most common off-label uses; (b) theoretically expected impact on the host's susceptibility to infection; (c) available evidence emerging from the clinical use of that agent (i.e., randomized clinical trials [RCTs], post-marketing studies, case series and single case reports); and (d) suggested preventive and risk minimization strategies. This section is focused on the risk of infection entailed by the use immune checkpoint inhibitors, cell adhesion inhibitors, sphingosine-1-phosphate receptor modulators (fingolimod) and proteasome inhibitors (PIs). In addition, the literature on alefacept (a T-cell activation inhibitor whose production has been discontinued) is briefly reviewed. These therapeutic families are not covered in other sections of the document. In general terms, all of them have a roughly common impact on the functionality, activation and/or migration of immune cells

Author Manuscript Author Manuscript Author Manuscript Author Manuscript

(in particular T-cells), rather than a direct cytotoxic action as that exerted by monoclonal antibodies targeting cell surface antigens.

Cytotoxic T lymphocyte-associated antigen 4 (CTLA-4)-targeted agents: ipilimumab and tremelimumab

Mechanism of action, approved indications and off-label uses

The cytotoxic T-lymphocyte-associated antigen 4 (CTLA-4), also known as CD152, was the first immune checkpoint described in human immunobiology [2, 3]. CTLA-4 plays an important role in the regulation of T-cell priming by dendritic cells (DCs) [3]. Upon initial antigen presentation, the T-cell receives two different stimulatory signals coming from the T-cell receptor and from the positive co-stimulatory receptor CD28, which are triggered by interactions with the peptide-MHC complex and the B7 molecules on the surface of DCs, respectively. A few hours after these initial steps, the co-inhibitory receptor CTLA-4 (a member of the immunoglobulin superfamily) is expressed on the surface of T-cells and transmits an inhibitory signal that ultimately downregulates immune responses [3]. Monoclonal antibodies targeted against CTLA-4 prevent such inhibitory function, resulting in enhanced priming (Figure 1). Ipilimumab, an IgG1 isotype, and tremelimumab, an IgG2 isotype, are two clinically developed, fully human monoclonal antibodies that bind CTLA-4 with high affinity and block its function.

Ipilimumab (Yervoy®, Bristol-Myers Squibb) was first approved by the US FDA in 2011 for the treatment of unresectable melanoma. The EMA approval was granted in 2012 for the same indication. In 2015 the FDA also approved ipilimumab in the adjuvant setting following complete surgical resection of melanoma. In the same year, the combination of ipilimumab with nivolumab, a programmed death (PD)-1 blocking monoclonal antibody, was also approved by the FDA for advanced (unresectable or metastatic) melanoma, whereas EMA approval for this association was obtained in 2016.

Expected impact on the susceptibility to infection

As CTLA-4 blockade promotes T-cell priming, therapy with these agents is not expected to increase susceptibility to infection. There are, however, two scenarios that could potentially predispose ipilimumab-treated patients to such complication. The first scenario is that CTLA-4 blockade induces auto-immune reaction directed against neutrophils [4]. This is, however, a rather rare adverse event. On the other hand, the therapeutic approach to CTLA-4 blockade-induced autoimmune phenomena usually requires the use of immunosuppressive agents. In the latter setting, infectious risks are increased [5], often due to the reactivation of chronic or latent infections such as hepatitis B virus (HBV), hepatitis C virus (HCV) or latent tuberculosis infection (LTBI), although the extent of such this has not been yet clearly established.

Available clinical data

Phase 2 clinical RCTs evaluating the safety of ipilimumab therapy for patients with advanced melanoma did not suggest an increased risk of infection [6–9]. A head-to-head comparison between a combination of ipilimumab plus dacarbazine versus placebo plus

Author Manuscript Author Manuscript Author Manuscript Author Manuscript

dacarbazine did not reveal a significant difference in the incidence of infection between both arms [10]. Similarly, phase 2 trials did not reveal a relationship between tremelimumab therapy and infection [11–13].

Studies did, however, find an association between CTLA-4-targeted agents and a series of unique immune-related adverse effects (irAEs) emerging from the upregulation of immune response. These toxicities can affect a variety of organ systems including skin (rash), gastrointestinal tract (colitis), pancreas (pancreatitis), liver (hepatitis), endocrine (hypophysitis or thyroiditis), lung (pneumonitis) and kidneys (nephritis) [14,15]. Treatment of these irAEs typically implies the use of corticosteroids and, in some cases, tumour necrosis factor (TNF)-α-targeted agents [14, 16–18].

An initial report described a case of invasive pulmonary aspergillosis (IPA) in a melanoma patient treated with ipilimumab [5]. Of note, the patient had developed ipilimumab-induced colitis and had previously received infliximab and high-dose corticosteroids. Subsequent cases of *Pneumocystis jiroveci* pneumonia (PCP) or cytomegalovirus (CMV) hepatitis among ipilimumab-treated patients that had received corticosteroids (with or without infliximab) due to the development of irAEs were also reported [19,20].

To date, only one retrospective study has systemically evaluated the risk of infection in patients receiving CTLA-4 blockade as treatment of melanoma [21]. Among 748 patients treated with ipilimumab, alone or in combination with a second immune checkpoint blocking agent, 7.3% developed serious infections, including bacterial pneumonia, intra-abdominal infection, *Clostridium difficile*-associated diarrhea, IPA, PCP, disseminated herpes zoster (HZ), CMV colitis and *Strongyloides stercoralis* hyperinfestation syndrome. The major risk factor for infection was the prior use of corticosteroids and/or TNF-α-targeted agents. A higher rate of infection was also noted among patients receiving a combination of ipilimumab with nivolumab as compared to those receiving ipilimumab monotherapy, likely because of the increased occurrence of irAEs further requiring immunosuppression.

Conclusions and suggested prevention strategies

- In view of available data, CTLA-4 blockade with ipilimumab or tremelimumab does not appear to be independently associated with the occurrence of infection, although can lead to a constellation of irAEs that usually requires additional immunosuppressive therapy with corticosteroids and/or TNF-α-targeted agents, thus increasing the risk of infection.
- Anti-*Pneumocystis* prophylaxis is recommended for patients with CTLA-4 blockade-induced irAEs who are expected to receive 20 mg of prednisone daily (or equivalent) for at least 4 weeks, in accordance with the current guidelines for patients with hematological conditions not infected with human immunodeficiency virus (HIV) [22].
- Due to the potential requirement of additional immunosuppressive therapy, conventional screening for chronic (latent) infections, including LTBI, HBV or

Author Manuscript Author Manuscript Author Manuscript Author Manuscript

HCV, is advisable before starting treatment with CTLA-4-targeted agents, followed by appropriate prophylaxis or therapy if needed.

- Clinicians caring for patients receiving corticosteroids and/or TNF-α-targeted agents for treatment of CTLA-4 blockade-induced irAEs should maintain close monitoring for the occurrence of symptoms or signs suggestive of infection. A multidisciplinary approach, including oncologists and Infectious Disease specialists, is highly advisable.

Programmed death (PD)-1 and PD-1 ligand 1 (PD-L1)-targeted agents: nivolumab, pembrolizumab and atezolizumab

Mechanism of action, approved indications and off-label uses

PD-1 is a key immune checkpoint that inhibits T-cell activity in peripheral tissues [23]. It is mainly expressed on activated CD4+ and CD8+ T-cells, but also on B-cells, monocytes, natural killer (NK) cells, and DCs [24]. PD-1 can be triggered by two ligands, PD-L1 and PD-L2. Engagement of PD-1 by either ligand results in a profound inhibition of CD8+ T-cell effector functions. PD-L1 can be expressed at the surface of tumor cells and of various cells present in the tumor microenvironment. T-cells infiltrating tumor tissues secrete interferon-γ (INF-γ), which triggers regulatory immunosuppressive loops including PD-L1 expression (Figure 2). Upregulation of PD-1 expression is, therefore, the reflection of an active T-cell infiltrate, and intensity of PD-L1 staining is associated with the clinical benefit expected in many tumor types such as non-small lung carcinoma [25] and melanoma [26].

PD-1 or PD-L1 blockade has been granted several approvals in the last years. Pembrolizumab (Keytruda®, Merck Sharp & Dohme) and nivolumab (Opdivo®, Bristol-Myers Squibb) are IgG4 monoclonal antibodies (humanized and fully human, respectively) targeted against PD-1. Both agents were first approved for the treatment of unresectable melanoma in 2014 and, subsequently, for advanced non-small cell lung cancer (2015), recurrent or metastatic head and neck carcinoma (2016), Hodgkin lymphoma (2016–2017), and urothelial carcinoma (2017). Additionally, nivolumab was granted for metastatic renal cell carcinoma in 2015, whereas pembrolizumab has been approved in 2017 for the treatment of any tumor with microsatellite instability. Atezolizumab (Tecentriq®, Roche) is a humanized IgG1 monoclonal antibody targeted against PD-L1 that was approved for urothelial carcinoma and lung cancer in 2016 and for bladder cancer in 2017.

Expected impact on the infection risk

Similarly to CTLA-4-targeted agents, it is not expected that the blockade of the PD-1/PD-L1 axis would result in an increased risk of infection since such an approach promotes T-cell effector functions. Nevertheless, PD-1/PD-L1 blockade-induced autoimmune manifestations (irAEs) may also require additional immunosuppression with corticosteroids and/or TNF-α-targeted agents, as before described for ipilimumab or tremelimumab [21].

Author Manuscript Author Manuscript Author Manuscript Author Manuscript

Available clinical data

Pivotal RCTs did not reveal an increased risk of infection for patients receiving PD-1 or PD-L1 blocking agents [27–32]. However, these studies show an association between this therapy and the occurrence of a wide range of irAEs involving different organ systems [27–33]. The safety profile of PD-1/PD-L1-targeted agents appears to be more favorable than that of CTLA-4-targeted agents, with a lower proportion of exposed patients developing severe irAEs [26, 34]. However, combination therapy with ipilimumab and a PD-1 blocking agent such as nivolumab is associated with significantly more irAEs than either agent alone [26, 35, 36]. This observation is important since the risk of infection related to PD-1 or PD-L1 blockade seems to be directly linked to the use of immunosuppressive medications for treating irAEs.

A retrospective analysis of melanoma patients treated with immune-checkpoint inhibitors (including 52 patients who received nivolumab alone, 80 who received a combination of nivolumab and ipilimumab, and 83 who received pembrolizumab) revealed 13 episodes of severe infection (cumulative incidence of 6.0%) [21]. These included 2 cases of PCP. The vast majority of these infections occurred among patients who received the combination of nivolumab and ipilimumab. The main risk factor for development of infection was the prior or concurrent receipt of corticosteroids and/or TNF-α-targeted agents for the therapeutic management of irAEs [21].

Of note, it has been recently reported various cases of reactivation of LTBI among patients treated with nivolumab or pembrolizumab in the absence of irAEs or additional immunosuppression other than cytotoxic chemotherapy [37–39]. The clinical onset of active tuberculosis disease was very rapid in these patients, within the first 3 months from the initiation of PD-1/PD-L1 blockade. These two circumstances raise the possibility that nivolumab or pembrolizumab might have unmasked latent (dormant) infection by boosting *Mycobacterium tuberculosis*-specific T-cells, resembling the immune reconstitution inflammatory syndrome (IRIS) observed in HIV patients upon initiation of antiretroviral therapy. A similar phenomenon has been hypothesized in form of acute progression of chronic progressive pulmonary aspergillosis [40]. On the basis of a multicenter post-marketing registry, the incidence of active tuberculosis among cancer patients receiving PD-1 or PD-L1 blocking agent in France (a low-prevalence country) has been estimated in about 1 case per 1,000 patients [38].

On the other hand, the enhancement in T-cell effector functions derived from PD-1/PD-L1 (and likely also CTLA-4) blockade may be beneficial for the immune control of certain infections in immunocompromised hosts [41] or during the so-called immunoparalysis phase of the course of sepsis, characterized by an excessive compensatory anti-inflammatory response and T-cell immune exhaustion [42]. There is an anecdotal case of invasive fungal disease (mucormycosis) successfully treated with a single dose of nivolumab and INF-γ [43], and a phase I RCT aimed at evaluating the safety and tolerability of nivolumab in participants with severe sepsis or septic shock is currently ongoing (ClinicalTrials.gov identifiers: NCT02960854).

Author Manuscript Author Manuscript Author Manuscript Author Manuscript

On the basis of this rationale, it could be hypothesized that the use of immune checkpoint inhibitors (CTLA-4 or PD-1/PD-L1 blocking agents) would not be necessarily detrimental among cancer patients with ongoing viral or fungal infections. However, it should be highlighted that the presence of active infectious processes constituted an exclusion criterion in pivotal RCTs.

Conclusions and suggested prevention strategies

- PD-1 or PD-L1 blocking agents do not appear to independently increase the risk of infection, although can lead to a constellation of irAEs that can require additional immunosuppressive therapy with corticosteroids and/or TNF-α-targeted agents, increasing in turn the risk of infection.
- Anti-*Pneumocystis* prophylaxis is recommended for patients with PD-1/PD-L1 blockade-induced irAEs who are expected to receive 20 mg of prednisone (or equivalent) for at least 4 weeks, in accordance with the current guidelines for non-HIV patients with hematological conditions [22].
- Due to the potential requirement of additional immunosuppressive therapy, conventional screening for chronic (latent) infections, including LTBI, HBV or HCV, is advisable before starting treatment with PD-1/PD-L1-targeted agents, followed by appropriate prophylaxis or therapy if needed.
- Clinicians caring for patients receiving corticosteroids and/or TNF-α inhibitors for treatment of PD-1/PD-L1 blockade-induced irAEs should maintain close monitoring for the occurrence of symptoms or signs suggestive of infection. A multidisciplinary approach, including oncologists and Infectious Disease specialists, is highly advisable.

Lymphocyte function-associated antigen 3 (LFA-3)-targeted agents: alefacept

Mechanism of action, approved indication and off-label uses

Alefacept (Amevive®, Astellas Pharma) was the first biological agent approved by the FDA for the treatment of moderate to severe chronic plaque psoriasis. It is a dimeric fusion protein that consists of the extracellular CD2-binding portion of the human leukocyte function antigen-3 (LFA-3) linked to the Fc portion of human IgG1. Therefore, this agent inhibits the activation and proliferation of T-cells by blocking LFA-3/CD2 interaction. An additional effect of the molecule is the induction of apoptosis in activated memory T-cells. In addition, its specific mode of action on T-cells and NK cells fostered studies in a wide range of conditions, such as autoimmunity and transplantation [44]. In 2011, production of alefacept was halted based on business needs, not clinical or safety issues.

Expected impact on the infection risk

Clinical efficacy and duration of treatment response to alefacept in psoriasis correlates with the reduction in peripheral blood CD4+ and CD8+ memory T-cell counts from baseline [45],

Author Manuscript Author Manuscript Author Manuscript Author Manuscript

whereas the *naïve* T-cell populations appear to remain unaffected [45]. No cases of sustained T-cell suppression were noted in RCTs [46].

Available clinical data

In pivotal RCTs, treatment with alefacept was not associated with the occurrence of opportunistic infections [47]. Long-term studies on the safety of alefacept reported a cumulative rate of infection of approximately 3%, most of them respiratory tract infections and cellulitis. There were no cases of tuberculosis, disseminated viral infections or opportunistic infections, or infection-related mortality [46].

Conclusions and suggested prevention strategies

- Alefacept is a fusion protein mainly targeting CD4+ and CD8+ effector memory T-cells. However, the induced decrease in CD4+ T-cell counts is transient and does not affect *in vitro* antigenic response.
- Although alefacept has not been associated with the occurrence of opportunistic infections or tuberculosis, monitoring for peripheral blood CD4+ T-cell counts is recommended.

α4-integrins (and other cell adhesion molecules)-targeted agents: natalizumab, vedolizumab and efalizumab

Mechanism of action, approved indications and off-label uses

Natalizumab (Tysabri®, Biogen Idec and Elan Corporation) was the first agent available in the selective adhesion molecule inhibitors class. This humanized IgG4 monoclonal antibody is targeted against the α4-integrin chain, which dimerizes with either the β1 chain or the β7 chain to form two different integrins: α4β1 (also known as very late antigen-4 [VLA-4]) and α4β7 [48]. Integrins are a family of transmembrane heterodimers that, upon interaction with endothelial ligands/counter-receptors, plays a crucial role in the leukocyte adhesion cascade. Vascular cell adhesion molecule-1 (VCAM-1) is an integrin receptor located on endothelial cells that binds to VLA-4, which is expressed on the surface of practically all leukocytes (except mature granulocytes), to promote firm leukocyte adhesion and crawling. This molecular interaction is required for lymphocytes to enter the central nervous system (CNS). Natalizumab blocks the translocation of activated VLA-4-expressing leukocytes across the blood-brain barrier (BBB) [49] and is currently approved for the treatment of relapsing-remitting multiple sclerosis (MS). Vedolizumab (Entyvio®, Millennium Pharmaceuticals) selectively targets the α4β7 integrin [49], which binds to mucosal addressin-cell adhesion molecule-1 (MAdCAM-1) to mediate T-cells homing to the lamina propria of the small intestine. Vedolizumab is approved for the treatment of moderately to severely active ulcerative colitis and Crohn's disease in adults who have failed at least one conventional therapy. Efalizumab (Raptiva®, Genentech) is a recombinant humanized monoclonal antibody targeted against CD11a, one of the two subunits of the αLβ2 integrin (also known as leukocyte function antigen-1 [LFA-1]). Efalizumab prevents binding of T-cells to the intercellular adhesion molecule-1 (ICAM-1), found on antigen-presenting cells, endothelial cells and keratinocytes, thus inhibiting the immunological process involved in the formation

Author Manuscript Author Manuscript Author Manuscript Author Manuscript

of the psoriatic plaque. Efalizumab was approved for the treatment of adult patients with moderate to severe chronic plaque psoriasis, although it was later withdrawn from the market due to the unacceptably high risk of progressive multifocal leukoencephalopathy (PML).

Expected impact on the infection risk

The only impact on infection susceptibility described in patients receiving natalizumab and efalizumab is the development of PML. Several subtypes of mononuclear cells (central memory T-cells, effector memory T-cells and activated monocytes) express α4β1 and α4β7 on their surface, and therefore their migration into the CNS is inhibited by natalizumab [48]. This leads to a decrease in the CD4+/CD8+ T-cell ratio and B-cell and CD138+ plasma cell counts in the cerebrospinal fluid (CSF) [50,51] and in the number of dendritic cells and CD4+ T-cells in cerebral perivascular spaces [52], among other effects. Due to its more selective mode of action on the α4β7 integrin, no alterations in the number and distribution of lymphocytes in the CSF have been described with vedolizumab [53]. On the other hand, efalizumab has been shown *in vitro* to impair peripheral T-cell migration across the BBB, intrathecal lymphocyte restimulation and target cell lysis, overall predisposing to the development of PML [54].

PML is the result of the infection (and subsequent degeneration) of oligodendrocytes in the white matter due to the John Cunningham (JC) polyomavirus (JCV), a non-enveloped double-stranded DNA virus [55]. JCV infection is highly prevalent worldwide, although rates vary across countries. The prevalence of infection increases with age, reaching 50-70% in the range of 50-70 years [56]. Primary infection is subclinical and mainly occurs during childhood, being the tonsils the suspected site of entry [57]. Following primary infection, the virus remains in latency in the kidneys, tonsils, peripheral blood leukocytes (predominantly B-cells) and brain [56, 58]. Viral DNA can be detected in these compartments by highly sensitive PCR techniques, although the expression of viral proteins is absent [56, 59]. While the archetypal form of JCV is the responsible for primary infection and latency, most cases of natalizumab-induced PML are associated with the so-called prototypical form (or PML-type) of the virus, characterized by rearrangements in the noncoding control region (NCCR) of the genome [60]. The ability of natalizumab to induce rearrangements in the NCCR sequences can be explained by the fact that this agent allows asymptomatic reactivation of JCV in plasma and urine in parallel with a decrease in JCV-specific cellular immune responses [61].

The clinical presentation of natalizumab-induced PML includes motor weakness, cognitive deficits, dysarthria and ataxia [62]. Cranial magnetic resonance imaging (MRI) typically shows T2-weighted hyperintense lesions in subcortical white matter without gadolinium enhancement [63]. Differential diagnosis should include an acute flare of relapsing-remitting MS itself (usually with complete recovery of neurological deficits after the attack and gadolinium-enhanced lesions with periventricular distribution in the MRI), acute disseminated encephalomyelitis, mitochondrial encephalopathies, or vasculitic disorders with potential brain involvement (such as systemic lupus erythematosus, systemic granulomatosis with polyangiitis [formerly known as Wegener granulomatosis], Behçet

Author Manuscript Author Manuscript Author Manuscript Author Manuscript

syndrome or isolated CNS vasculitis) [64]. The detection of viral DNA in the CSF or brain biopsy is required for the definitive diagnosis [63]. JCV PCR on CSF has a high sensitivity and even higher specificity, but a negative result does not rule out the diagnosis of PML and testing should be repeated in case of high clinical suspicion. Early discontinuation of natalizumab is the first step in the management of PML [65], whereas antiviral therapy has not shown clear benefit. Early removal of natalizumab from the bloodstream via plasma exchange or immunoadsorption is also indicated [63, 66]. In an open-label longitudinal study with 12 MS patients, serum natalizumab concentrations were reduced by a mean of 92% from baseline to 1 week after three plasma exchange sessions. Chemokine-induced leukocyte transmigration across the BBB increased in parallel, with no MS relapses or other disease activity [19188571]. However, this approach has been also associated with the subsequent development of IRIS-like phenomena [67].

Natalizumab was first approved in 2004 by the FDA for the treatment of relapsing-remitting MS. Following the first reports of PML in MS patients also receiving INF-β-1a [68, 69], the manufacturer announced on February 2005 a voluntary temporary suspension of the marketing of natalizumab. It was returned again to the US market in 2006, but only available through a specific risk-minimization program (Tysabri Outreach Unified Commitment to Health [TOUCH™] Prescribing Program). Natalizumab is currently approved as monotherapy for patients with relapsing-remitting MS both in the US and Europe (only for highly active or rapidly evolving forms of disease in the latter). In addition, it is FDA-approved since 2008 for moderate-to-severe Crohn's disease in patients with inadequate response to conventional therapies and TNF-α-targeted agents. The EMA has not approved this indication due to concerns on the benefit/risk balance.

Available clinical data

Some major risk factors have been identified to stratify the risk of PML in patients receiving natalizumab. The risk of early natalizumab-induced PML seems to be negligible if pre-treatment JCV-specific IgG antibodies are negative [70]. A useful approach to risk stratification among seropositive patients lies in the anti-JCV serum antibody index. This value (not to be confounded with the CSF/serum antibody index) is the normalized ratio between the signal (measured in optical densities) derived from IgG antibodies in the serum of the patient and the signal from an anti-JCV-positive cutoff calibrator sample. This assay optimizes the differentiation between negative and positive specimens and offers better reliability than those providing only absolute cut-off values. An index value <0.20 is regarded as seronegative, between 0.20 and 0.40 as indeterminate, and >0.40 as evidence for anti-JCV seropositivity. A second-generation enzyme-linked immunosorbent assay (ELISA) is commercially available (STRATIFY JCV® DxSelect; Focus Diagnostics, Cypress, CA), although usually restricted to reference centers [71]. For JCV-seropositive subjects, those with an IgG index ≤1.5 have a lower incidence of PML compared to the overall population of anti-JCV antibody-positive patients [72]. Therefore, it is recommended to test for anti-JCV IgG antibodies before starting treatment in natalizumab-*naïve* MS patients [72]. The annualized seroconversion rate among JCV-seronegative patients exposed to natalizumab has been estimated in 7.1% [73]. Therefore, testing for anti-JCV antibodies and for IgG index should be repeated every 6 months beyond the first year of treatment among seronegative

Author Manuscript Author Manuscript Author Manuscript Author Manuscript

patients and seropositive patients with a baseline index ≤1.5, respectively [72]. It is also recommended to perform MRI-scanning every 6 months as the risk of PML increases, or even every 3-4 months in patients at high risk of PML choosing to remain on therapy [72]. Previous immunosuppressive treatment double the incidence of PML among natalizumab-exposed patients [70], an observation likely explained by the higher risk of having latent infection due to the prototype form of JCV at therapy initiation. Finally, the risk increases with the duration of treatment with natalizumab, reaching an incidence of 2 cases per 1,000 treated patients beyond 48 months of therapy. However, although the incidence increases abruptly after 72 months, more information is needed to delineate the risk of PML after prolonged treatment courses [70, 74]. Other biomarkers that are being evaluated to stratify the risk of PML include CD62L and lipid-specific immunoglobulin M bands [75].

Unlike natalizumab, vedolizumab does not affect CNS immunosurveillance (since lymphocyte migration across the BBB does not depend on α4β7 integrin) and no cases of vedolizumab-induced PML have been reported to date [76, 77]. Efalizumab increases the risk of PML. Until 2009, four cases had been described within a cohort of 6,000 patients with psoriasis treated with this agent [49].

No major infections other than PML have been described with the use of natalizumab. Compared to placebo, MS patients receiving natalizumab have a mild increase of herpesvirus infections [78], although no specific prophylactic measures are usually considered. In a recent pooled analysis of clinical trials and post-marketing cohort studies, vedolizumab-treated patients suffered a moderate increase in the incidence of serious infectious complications (mostly enteric and surgical site infections) compared to placebo (4.3 versus 3.8 events per 100 patient-years) [79]. Although vedolizumab seems to be safe in terms of infection risk, more data is needed to address this issue, especially for long-term treatments.

Conclusions and suggested prevention strategies

- In view of available data, therapy with natalizumab or efalizumab is associated with a major increase in the risk of PML. No cases have been described so far in patients receiving vedolizumab.
- Risk factors for natalizumab-induced PML include pre-treatment JCV serostatus (and anti-JCV IgG antibody index), history of prior immunosuppression, and duration of treatment with natalizumab.
- It is recommended to test for anti-JCV IgG antibodies before starting treatment with natalizumab. JCV-seronegative patients should be retested every 6 months after the first year of treatment. JCV-seropositive patients with and IgG antibody index ≤1.5 should be also retested every 6 months.
- The decision of discontinuing therapy with natalizumab in patients at high-risk of PML (positive anti-JCV serology with an IgG antibody index >1.5 and therapy duration of 48 months or more) is difficult and should be shared by the MS specialist and the patient.

Author Manuscript Author Manuscript Author Manuscript Author Manuscript

- The new onset of neurological symptoms in natalizumab-treated patients at risk of PML should prompt suspicion of the disease and appropriate diagnostic work-up.
- Treatment of natalizumab-induced PML includes early drug discontinuation and clearance from the bloodstream via plasma exchange or immunoadsorption.

Sphingosine-1-phosphate (S1P) receptor modulators: fingolimod

Mechanism of action, approved indications and off-label uses

Fingolimod (Gilenya®, Novartis Pharmaceuticals) was the first oral disease-modifying drug approved for relapsing-remitting MS [80]. Fingolimod acts as an agonist of four out of the five sphingosine-1-phosphate (S1P) receptors ($S1PR_1$, $S1PR_3$, $S1PR_4$ and $S1PR_5$) present on the surface of lymphocytes, endothelial cells, oligodendrocytes and NK cells [81,82]. After binding, the receptor internalizes into the target T-cell and undergoes proteasomal degradation [83]. The phospholipid S1P plays an instrumental role in the release of lymphocytes from secondary lymphoid sites, particularly lymph nodes [84]. By down-regulation of the S1P receptor, oral administration of fingolimod results in an accumulation of lymphocytes in secondary lymph tissues and induces peripheral blood lymphopenia [85]. Although fingolimod can lead to a marked decrease of B-cell and a mild decrease of NK cell counts, the effect on T-cell populations is much more profound [85].

The trafficking effect of fingolimod is variable and depends on several T-cell attributes. CCR7 is a homing chemokine receptor that modulates lymphocyte migration and leads to T-cell retention within lymph nodes. Tissue CD4+ T-cells lacking CCR7 show diminished migration into afferent lymphatics [84]. Fingolimod has been found to prevent the egress of T-cells expressing CCR7 (*naïve* and central memory subsets) from the lymph nodes but to spare CCR7- effector memory T-cells, which are mainly involved in immunosurveillance and that maintain their ability to recirculate between the bloodstream and secondary lymph tissues [86].

In murine models, a marked decrease in peripheral blood CD4+ and CD8+ T-cell and, to a lesser degree, B-cell counts is noted from the first days after administration of fingolimod. Although there is a concurrent increase in the number of lymphocytes within lymph nodes, the eventual steady state (reached at 21 days of therapy) is associated with overall lymphocyte depletion, inducing a decrease of up to 80% in peripheral blood lymphocyte counts from baseline [85]. As outlined previously, *naïve* and central memory CD4+ and CD8+ T-cells are the subsets most profoundly affected, while the proportion of effector memory T-cells is concurrently increased [87]. In CSF, fingolimod induces a notable decrease of the percentage of CD4+ T-cells with a reversion in the CD4+/CD8+ T-cell ratio [87]. After treatment discontinuation, fingolimod-induced lymphocytopenia begins to recover within 48 hours and lymphocyte counts normalize in approximately 6 weeks [88].

Expected impact on the infection risk

Fingolimod alters the trafficking and distribution of T-cell subpopulations across different body compartments. Although the use of this agent results in sustained lymphocytopenia,

Author Manuscript Author Manuscript Author Manuscript Author Manuscript

the risk of infection in fingolmod-treated patients is not proportional to the peripheral blood counts, and the monitoring for T-cell subpopulations seems to lack clinical utility [89]. This may hypothetically be explained by two reasons: first, the depletion of peripheral blood lymphocytes is associated with a relative increase in lymphocyte counts within lymphoid tissues; and, second, the number of circulating effector memory T-cells, which provide immunosurveillance against pathogens, remains unaffected.

Fingolimod can impair the adaptive immune responses against novel and recall antigens. In a murine model, high doses of fingolimod impair the generation of lymphocytic choriomeningitis virus-specific CD4+ and CD8+ T-cells [90]. In humans, although an initial study suggested that fingolimod-treated individuals could mount adaptive responses to influenza vaccine antigens comparable to healthy controls [91], a more recently published placebo-controlled trial demonstrated lower rates of seroconversion with inactivated influenza vaccination or revaccination with tetanus toxoid [92].

Available clinical data

The most frequent infectious complication in patients receiving fingolimod is herpesvirus infection and reactivation, predominantly due to varicella-zoster (VZV) and herpes simplex virus (HSV) [93]. Treatment with fingolimod reduces the number of circulating VZV- and Epstein-Barr virus (EBV)-specific T-cells and leads to subclinical reactivation in the saliva of around 20% of patients [94]. Although initial trials found similar rates of VZV infection between placebo and treatment (fingolimod 0.5 mg/day or 1.25 mg/day) arms, a systematic review demonstrated an increased risk of VZV symptomatic infection (mostly in form of uncomplicated cutaneous HZ) among fingolimod-treated patients [78].

Although VZV and HSV infections are usually mild and limited to the skin or mucosa, severe forms have been also reported, including one case of lethal primary varicella infection, two cases of HSV encephalitis (one of them lethal) [95,96], and one case of VZV laryngitis [97]. On the basis of these findings, recommendations have been made to mitigate the risk of herpesvirus infection in patients receiving fingolimod [78]. First, VZV-seronegative patients without a clinical history of primary varicella infection should be vaccinated with one of the licensed live attenuated varicella vaccines before the initiation of therapy [78]. Data on the usefulness and safety of zoster vaccination among VZV-seropositive patients in this clinical setting is lacking. The higher content of the Oka strain in the live attenuated zoster vaccine compared to the varicella vaccine (>19,000 versus >1,300 plaque forming units, respectively) raises concerns on the risk of infection due to the vaccine strain [98, 99]. On the other hand, the recombinant subunit vaccine composed of the VZV glycoprotein E and the AS01B adjuvant system (HZ/su) exhibits a more favorable safety profile and has been FDA-approved for adults aged 50 years and older [100]. Nevertheless, no specific information is available for MS patients treated with fingolimod. Although the HZ/su vaccine poses no risk for vaccine-induced illness, it should be noted that patients under immunosuppressive therapy were excluded from pivotal RCTs [101,102]. Second, while no antiviral prophylaxis is recommended to prevent VZV reactivation in patients treated with fingolimod alone, antiviral prophylaxis should be considered for patients also requiring repeated high-dose corticosteroids. Finally, all patients should be educated about

Author Manuscript Author Manuscript Author Manuscript Author Manuscript

early symptoms and signs of VZV and HSV infection and the need to report them promptly [78].

Apart from herpesvirus infections, other infections typically associated with immunosuppression have been described in patients treated with fingolimod, including primary cutaneous cryptococcosis [103], cryptococcal meningitis [104,105], and visceral leishmaniasis [106]. A young MS patient developed extensive molluscum contagiosum infection (around 150 lesions) [107], a phenotype that resembles that observed among HIV-infected patients with very low CD4+ T-cell counts.

Given that fingolimod induces a decrease in CSF lymphocyte counts similar to that produced by natalizumab, studies have specifically looked at the risk of progressive multifocal leukoencephalopathy (PML) associated with the use of fingolimod. However, only anecdotal cases of PML have been reported [108,109]. Although the incidence of PML associated with fingolimod appears to be significantly lower than that associated with natalizumab, such risk should not be underestimated until more epidemiological data is available, particularly among patients receiving long-term therapy.

Conclusions and suggested prevention strategies

- In view of available data, therapy with fingolimod is associated with a mild increase in the risk of infection, mainly due to herpesviruses. Anecdotal cases of other opportunistic infections have been reported.
- Fingolimod induces profound and sustained, albeit reversible, peripheral blood lymphopenia (mostly affecting *naïve* and central memory CD4+ and CD8+ T-cell subsets).
- Monitoring for peripheral blood counts of total lymphocytes and CD4+ and CD8+ T-cell subpopulations is not recommended since these parameters do not appear to correlate with the risk of infection.
- No antiviral, antifungal or antibacterial prophylaxis is recommended for patients receiving fingolimod alone. However, prophylaxis with acyclovir or valacyclovir may be considered for patients treated with fingolimod in conjunction with other immunosuppressive agents (i.e., prolonged high-dose corticosteroid therapy).
- Before starting treatment with fingolimod, a prior clinical history of primary varicella infection or varicella vaccination should be obtained. Unvaccinated patients with inconclusive history of primary varicella infection should undergo serologic testing for VZV. VZV-seronegative patients without a prior history of primary varicella infection should receive live attenuated varicella vaccination at least on month before the initiation of fingolimod. The administration of the adjuvanted subunit zoster vaccine (HZ/su) may be considered for VZV-seropositive patients (particularly those aged 50 years and older), although specific information in this clinical setting is lacking.

Author Manuscript Author Manuscript Author Manuscript Author Manuscript

Proteasome inhibitors: bortezomib, carfilzomib and ixazomib

Mechanism of action, approved indications and off-label uses

Proteasome inhibitors (PIs) are part of the current armamentarium for treating multiple myeloma (MM) and an uncommon form of non-Hodgkin lymphoma (mantle cell lymphoma) [110]. Since the appearance of bortezomib (a first-generation PI), a continuous improvement in disease-free survival in patients with MM has been observed [111, 112]. Second-generation PIs, such as carfilzomib and ixazomib, were introduced with the aim of reducing the bortezomib-associated adverse events (mainly peripheral neuropathy) [113]. Novel PIs (orprozomib, marizomib, delanzomib) are now being tested in the setting of phase I/II trials [114].

Bortezomib (Velcade®, Janssen-Cilag) is indicated for front-line treatment of MM and relapsed or refractory mantle cell lymphoma. For MM, bortezomib is used as induction therapy in combination with melphalan and prednisone, or in combination with dexamethasone and one of the following: thalidomide, lenalidomide, or cyclophosphamide. In addition, bortezomib has been used in combination with other agents in solid organ tumors and other hematological malignancies, although the indication in such conditions has not been retained. Bortezomib has also occasionally been used in a growing number of non-neoplastic conditions, such as chronic humoral allograft rejection and recurrent membranous glomerulonephritis in kidney transplant recipients, lupus nephritis, thrombotic thrombocytopenic purpura, or anti-NMDA receptor encephalitis, among others [115, 116].

Carfilzomib (Kyprolis®, Amgen) and ixazomib (Ninlaro®, Takeda) have been approved in combination with dexamethasone or lenalidomide plus dexamethasone for the treatment of patients with relapsed or refractory MM who have received at least one line of therapy.

PIs act by inhibiting the ubiquitin proteasome pathway, an essential component of the protein degradation pathway. The inhibition of this pathway leads to the induction of apoptosis in cancer cell lines and to a selective T-cell depletion [114]. Second-generation PIs seem to irreversibly bind to the proteasome resulting in a longer inhibition effect as compared to bortezomib, although the clinical relevance of this observation in terms of infection risk has not been established.

Expected impact on the infection risk

Patients with MM are at higher risk of specific infectious complications, such as pneumococcal invasive infection, HZ and influenza [117]. Due to the depletion of T-cells and the subsequent impairment in viral antigen presentation, the use of PIs is associated with a higher risk for reactivation of viral infections, particularly VZV. PIs also impact on the net state of immunosuppression and, therefore, may increase the risk for opportunistic infections when used in combination with other immunosuppressive regimens [118].

Available clinical data

Data about the safety of bortezomib can be extracted from the results of phase III pivotal trials. The most common infection developed during bortezomib therapy was HZ. The two

Author Manuscript Author Manuscript Author Manuscript Author Manuscript

first phase III trials using bortezomib as rescue (n = 669) or front line therapy (n = 682) for MM showed an increase in the risk of HZ within the bortezomib group from 5% to 13% [111] and from 4% to 13% [112], respectively. In the first study, the rates of HZ categorized as serious adverse event were 1.5% and 0.9% in the bortezomib and control groups, respectively [111]. Others series have reported an increase in the incidence of HZ from 11% in the pre-bortezomib to 22.3% after the introduction of this agent [119]. In view of this preliminary evidence, most centers have adopted the use of prophylaxis with acyclovir or valacyclovir, resulting in a reduction in the incidence of HZ across subsequent trials (including those evaluating the safety of newer PIs such as carfilzomib or ixazomib) [113]. The risk of infection due to other herpesvirus (CMV, HSV) or hepatitis B virus reactivation in patients receiving PIs seems to be very low.

Although pneumonia is common among MM patients recruited in trials with PIs, such agents do not seem to increase the risk of most types of pneumonia beyond that associated with comparator therapies [112]. For example, in the ENDEAVOR trial, in which 929 patients with relapsed and/or refractory MM were randomized to receive carfilzomib or bortezomib (plus dexamethasone in both arms), the incidence of pneumonia was about 8% [113]. The occurrence of PCP has been occasionally reported in patients receiving bortezomib in conjunction with other immunosuppressive agents, but the overall incidence seems to be very low [118]. The use of PI was not associated with invasive fungal infection in a cohort of 372 patients [120], although the severity of respiratory virus infection may be increased. In an Australian series, influenza among patients receiving PIs leaded to high hospitalization (66.7%), ICU admission (41.6%) and mortality (33.3%) rates [121]. The few data available on the immunogenicity of seasonal trivalent inactivated influenza vaccine suggest that this strategy is effective in this population. However, no data about the impact of PIs on the immunogenicity of pneumococcal conjugate vaccine is available. Finally, uncommon opportunistic infections such as nocardiosis or protothecosis have been anecdotally reported in patients under PI therapy [122].

Conclusions and suggested prevention strategies

- In view of available data, therapy with PIs clearly increases the risk of HZ as compared to non-PI regimens. The occurrence of respiratory tract infections (including pneumonia) is also common among patients with MM, although this susceptibility seems to be influenced to a lesser extent by the use of PIs in the induction regimen. The risk of influenza-related complications seems to be also increased among MM patients receiving PIs.
- Antiviral prophylaxis with acyclovir or valacyclovir is recommended for VZV-seropositive patients during induction therapy with PIs and for at least 4 weeks after its discontinuation.
- The routine use of anti-*Pneumocystis* prophylaxis is not recommended, but it may be considered for selected MM patients with additional risk factors (i.e., prolonged high-dose corticosteroid therapy).
- Unvaccinated patients with inconclusive history of primary varicella infection should undergo serologic testing for VZV. VZV-seronegative patients without a

Author Manuscript Author Manuscript Author Manuscript Author Manuscript

prior history of primary varicella infection should receive live attenuated varicella vaccination at least on month before the initiation of PIs. The administration of the adjuvanted subunit zoster vaccine (HZ/su) may be considered for VZV-seropositive patients (particularly those aged 50 years and older), although specific information in this clinical setting is lacking.

- Seasonal trivalent inactivated influenza vaccination should be administered at least 2 weeks before initiating PIs, and annually thereafter throughout the entire course of therapy.
- Pneumococcal vaccination series (7-valente [PCV7] or 13-valent pneumococcal conjugate vaccine [PCV13] followed by a dose of 23-valent pneumococcal polysaccharide vaccine [PPV23] at least 8 weeks later) should be ideally completed 4 to 6 weeks (minimum 2 weeks) before initiating PIs. Revaccination with PPV23 should occur once 5 years after the initial dose.

Acknowledgments

Funding sources: This research was partially supported by Plan Nacional de I+D+I 2013-2016 and Instituto de Salud Carlos III, Subdirección General de Redes y Centros de Investigación Cooperativa, Spanish Ministry of Economy and Competitiveness, Spanish Network for Research in Infectious Diseases (REIPI RD16/0016/0002 and 0008) – co-financed by the European Development Regional Fund (EDRF) *"A way to achieve Europe"*. M.F.R. holds a clinical research contract "Juan Rodés" (JR14/00036) from the Instituto de Salud Carlos III, Spanish Ministry of Economy and Competitiveness.

References

1. Fernández-Ruiz MYM, Manuel O, Akan H, Carratalà J, Aguado JM, Delaloye J. ESCMID Study Group for Infections in Compromised Hosts (ESGICH) Consensus Document on the Safety of targeted and biological therapies: an Infectious Diseases perspective: Introduction. Clin Microbiol Infect. 2018
2. Brunet JF, Denizot F, Luciani MF, Roux-Dosseto M, Suzan M, Mattei MG, et al. A new member of the immunoglobulin superfamily–CTLA-4. Nature. 1987; 328:267–70. [PubMed: 3496540]
3. Krummel MF, Allison JP. CD28 and CTLA-4 have opposing effects on the response of T cells to stimulation. J Exp Med. 1995; 182:459–65. [PubMed: 7543139]
4. Akhtari M, Waller EK, Jaye DL, Lawson DH, Ibrahim R, Papadopoulos NE, et al. Neutropenia in a patient treated with ipilimumab (anti-CTLA-4 antibody). J Immunother. 2009; 32:322–4. [PubMed: 19242368]
5. Kyi C, Hellmann MD, Wolchok JD, Chapman PB, Postow MA. Opportunistic infections in patients treated with immunotherapy for cancer. J Immunother Cancer. 2014; 2:19. [PubMed: 24991413]
6. Hodi FS, O'Day SJ, McDermott DF, Weber RW, Sosman JA, Haanen JB, et al. Improved survival with ipilimumab in patients with metastatic melanoma. N Engl J Med. 2010; 363:711–23. [PubMed: 20525992]
7. O'Day SJ, Maio M, Chiarion-Sileni V, Gajewski TF, Pehamberger H, Bondarenko IN, et al. Efficacy and safety of ipilimumab monotherapy in patients with pretreated advanced melanoma: a multicenter single-arm phase II study. Ann Oncol. 2010; 21:1712–7. [PubMed: 20147741]
8. Wolchok JD, Neyns B, Linette G, Negrier S, Lutzky J, Thomas L, et al. Ipilimumab monotherapy in patients with pretreated advanced melanoma: a randomised, double-blind, multicentre, phase 2, dose-ranging study. Lancet Oncol. 2010; 11:155–64. [PubMed: 20004617]
9. Margolin K, Ernstoff MS, Hamid O, Lawrence D, McDermott D, Puzanov I, et al. Ipilimumab in patients with melanoma and brain metastases: an open-label, phase 2 trial. Lancet Oncol. 2012; 13:459–65. [PubMed: 22456429]

Author Manuscript Author Manuscript Author Manuscript Author Manuscript

10. Robert C, Thomas L, Bondarenko I, O'Day S, Weber J, Garbe C, et al. Ipilimumab plus dacarbazine for previously untreated metastatic melanoma. N Engl J Med. 2011; 364:2517–26. [PubMed: 21639810]
11. Camacho LH, Antonia S, Sosman J, Kirkwood JM, Gajewski TF, Redman B, et al. Phase I/II trial of tremelimumab in patients with metastatic melanoma. J Clin Oncol. 2009; 27:1075–81. [PubMed: 19139427]
12. Sangro B, Gomez-Martin C, de la Mata M, Inarrairaegui M, Garralda E, Barrera P, et al. A clinical trial of CTLA-4 blockade with tremelimumab in patients with hepatocellular carcinoma and chronic hepatitis C. J Hepatol. 2013; 59:81–8. [PubMed: 23466307]
13. Chung KY, Gore I, Fong L, Venook A, Beck SB, Dorazio P, et al. Phase II study of the anti-cytotoxic T-lymphocyte-associated antigen 4 monoclonal antibody, tremelimumab, in patients with refractory metastatic colorectal cancer. J Clin Oncol. 2010; 28:3485–90. [PubMed: 20498386]
14. Weber JS, Kahler KC, Hauschild A. Management of immune-related adverse events and kinetics of response with ipilimumab. J Clin Oncol. 2012; 30:2691–7. [PubMed: 22614989]
15. Johnson DB, Sullivan RJ, Ott PA, Carlino MS, Khushalani NI, Ye F, et al. Ipilimumab Therapy in Patients With Advanced Melanoma and Preexisting Autoimmune Disorders. JAMA Oncol. 2016; 2:234–40. [PubMed: 26633184]
16. De Felice KM, Gupta A, Rakshit S, Khanna S, Kottschade LA, Finnes HD, et al. Ipilimumab-induced colitis in patients with metastatic melanoma. Melanoma Res. 2015; 25:321–7. [PubMed: 25933207]
17. Horvat TZ, Adel NG, Dang TO, Momtaz P, Postow MA, Callahan MK, et al. Immune-Related Adverse Events, Need for Systemic Immunosuppression, and Effects on Survival and Time to Treatment Failure in Patients With Melanoma Treated With Ipilimumab at Memorial Sloan Kettering Cancer Center. J Clin Oncol. 2015; 33:3193–8. [PubMed: 26282644]
18. Postow MA. Managing immune checkpoint-blocking antibody side effects. Am Soc Clin Oncol Educ Book. 2015:76–83. [PubMed: 25993145]
19. Arriola E, Wheater M, Krishnan R, Smart J, Foria V, Ottensmeier C. Immunosuppression for ipilimumab-related toxicity can cause pneumocystis pneumonia but spare antitumor immune control. Oncoimmunology. 2015; 4:e1040218. [PubMed: 26451305]
20. Uslu U, Agaimy A, Hundorfean G, Harrer T, Schuler G, Heinzerling L. Autoimmune Colitis and Subsequent CMV-induced Hepatitis After Treatment With Ipilimumab. J Immunother. 2015; 38:212–5. [PubMed: 25962110]
21. Del Castillo M, Romero FA, Arguello E, Kyi C, Postow MA, Redelman-Sidi G. The Spectrum of Serious Infections Among Patients Receiving Immune Checkpoint Blockade for the Treatment of Melanoma. Clin Infect Dis. 2016; 63:1490–3. [PubMed: 27501841]
22. Maertens J, Cesaro S, Maschmeyer G, Einsele H, Donnelly JP, Alanio A, et al. ECIL guidelines for preventing Pneumocystis jirovecii pneumonia in patients with haematological malignancies and stem cell transplant recipients. J Antimicrob Chemother. 2016; 71:2397–404. [PubMed: 27550992]
23. Nishimura H, Nose M, Hiai H, Minato N, Honjo T. Development of lupus-like autoimmune diseases by disruption of the PD-1 gene encoding an ITIM motif-carrying immunoreceptor. Immunity. 1999; 11:141–51. [PubMed: 10485649]
24. Keir ME, Butte MJ, Freeman GJ, Sharpe AH. PD-1 and its ligands in tolerance and immunity. Annu Rev Immunol. 2008; 26:677–704. [PubMed: 18173375]
25. Garon EB, Rizvi NA, Hui R, Leighl N, Balmanoukian AS, Eder JP, et al. Pembrolizumab for the treatment of non-small-cell lung cancer. N Engl J Med. 2015; 372:2018–28. [PubMed: 25891174]
26. Larkin J, Chiarion-Sileni V, Gonzalez R, Grob JJ, Cowey CL, Lao CD, et al. Combined Nivolumab and Ipilimumab or Monotherapy in Untreated Melanoma. N Engl J Med. 2015; 373:23–34. [PubMed: 26027431]
27. Topalian SL, Hodi FS, Brahmer JR, Gettinger SN, Smith DC, McDermott DF, et al. Safety, activity, and immune correlates of anti-PD-1 antibody in cancer. N Engl J Med. 2012; 366:2443–54. [PubMed: 22658127]

Author Manuscript Author Manuscript Author Manuscript Author Manuscript

28. Brahmer JR, Tykodi SS, Chow LQ, Hwu WJ, Topalian SL, Hwu P, et al. Safety and activity of anti-PD-L1 antibody in patients with advanced cancer. N Engl J Med. 2012; 366:2455–65. [PubMed: 22658128]
29. Robert C, Ribas A, Wolchok JD, Hodi FS, Hamid O, Kefford R, et al. Anti-programmed-death-receptor-1 treatment with pembrolizumab in ipilimumab-refractory advanced melanoma: a randomised dose-comparison cohort of a phase 1 trial. Lancet. 2014; 384:1109–17. [PubMed: 25034862]
30. Powles T, Eder JP, Fine GD, Braiteh FS, Loriot Y, Cruz C, et al. MPDL3280A (anti-PD-L1) treatment leads to clinical activity in metastatic bladder cancer. Nature. 2014; 515:558–62. [PubMed: 25428503]
31. Balar AV, Galsky MD, Rosenberg JE, Powles T, Petrylak DP, Bellmunt J, et al. Atezolizumab as first-line treatment in cisplatin-ineligible patients with locally advanced and metastatic urothelial carcinoma: a single-arm, multicentre, phase 2 trial. Lancet. 2017; 389:67–76. [PubMed: 27939400]
32. Fehrenbacher L, Spira A, Ballinger M, Kowanetz M, Vansteenkiste J, Mazieres J, et al. Atezolizumab versus docetaxel for patients with previously treated non-small-cell lung cancer (POPLAR): a multicentre, open-label, phase 2 randomised controlled trial. Lancet. 2016; 387:1837–46. [PubMed: 26970723]
33. Eigentler TK, Hassel JC, Berking C, Aberle J, Bachmann O, Grunwald V, et al. Diagnosis, monitoring and management of immune-related adverse drug reactions of anti-PD-1 antibody therapy. Cancer Treat Rev. 2016; 45:7–18. [PubMed: 26922661]
34. Robert C, Schachter J, Long GV, Arance A, Grob JJ, Mortier L, et al. Pembrolizumab versus Ipilimumab in Advanced Melanoma. N Engl J Med. 2015; 372:2521–32. [PubMed: 25891173]
35. Postow MA, Chesney J, Pavlick AC, Robert C, Grossmann K, McDermott D, et al. Nivolumab and ipilimumab versus ipilimumab in untreated melanoma. N Engl J Med. 2015; 372:2006–17. [PubMed: 25891304]
36. Hodi FS, Chesney J, Pavlick AC, Robert C, Grossmann KF, McDermott DF, et al. Combined nivolumab and ipilimumab versus ipilimumab alone in patients with advanced melanoma: 2-year overall survival outcomes in a multicentre, randomised, controlled, phase 2 trial. Lancet Oncol. 2016; 17:1558–68. [PubMed: 27622997]
37. Lee JJ, Chan A, Tang T. Tuberculosis reactivation in a patient receiving anti-programmed death-1 (PD-1) inhibitor for relapsed Hodgkin's lymphoma. Acta Oncol. 2016; 55:519–20. [PubMed: 26754959]
38. Picchi H, Mateus C, Chouaid C, Besse B, Marabelle A, Michot JM, et al. Infectious complications associated with the use of immune checkpoint inhibitors in oncology: Reactivation of tuberculosis after anti PD-1 treatment. Clin Microbiol Infect. 2017
39. Chu YC, Fang KC, Chen HC, Yeh YC, Tseng CE, Chou TY, et al. Pericardial Tamponade Caused by a Hypersensitivity Response to Tuberculosis Reactivation after Anti-PD-1 Treatment in a Patient with Advanced Pulmonary Adenocarcinoma. J Thorac Oncol. 2017; 12:e111–e4. [PubMed: 28748816]
40. Uchida N, Fujita K, Nakatani K, Mio T. Acute progression of aspergillosis in a patient with lung cancer receiving nivolumab. Respirol Case Rep. 2018; 6:e00289. [PubMed: 29321933]
41. Daver N, Kontoyiannis DP. Checkpoint inhibitors and aspergillosis in AML: the double hit hypothesis. Lancet Oncol. 2017; 18:1571–3. [PubMed: 29208429]
42. Chang K, Svabek C, Vazquez-Guillamet C, Sato B, Rasche D, Wilson S, et al. Targeting the programmed cell death 1: programmed cell death ligand 1 pathway reverses T cell exhaustion in patients with sepsis. Crit Care. 2014; 18:R3. [PubMed: 24387680]
43. Grimaldi D, Pradier O, Hotchkiss RS, Vincent JL. Nivolumab plus interferon-gamma in the treatment of intractable mucormycosis. Lancet Infect Dis. 2017; 17:18.
44. Rigby MR, DiMeglio LA, Rendell MS, Felner EI, Dostou JM, Gitelman SE, et al. Targeting of memory T cells with alefacept in new-onset type 1 diabetes (T1DAL study): 12 month results of a randomised, double-blind, placebo-controlled phase 2 trial. Lancet Diabetes Endocrinol. 2013; 1:284–94. [PubMed: 24622414]

Author Manuscript Author Manuscript Author Manuscript Author Manuscript

45. Gordon KB, Vaishnaw AK, O'Gorman J, Haney J, Menter A, Alefacept Clinical Study G. Treatment of psoriasis with alefacept: correlation of clinical improvement with reductions of memory T-cell counts. Arch Dermatol. 2003; 139:1563–70. [PubMed: 14676071]
46. Wexler D, Searles G, Landells I, Shear NH, Bissonnette R, Papp K, et al. Update on alefacept safety. J Cutan Med Surg. 2009; 13(Suppl 3):S139–47. [PubMed: 20053326]
47. Jenneck C, Novak N. The safety and efficacy of alefacept in the treatment of chronic plaque psoriasis. Ther Clin Risk Manag. 2007; 3:411–20. [PubMed: 18488075]
48. Ransohoff RM. Natalizumab for multiple sclerosis. N Engl J Med. 2007; 356:2622–9. [PubMed: 17582072]
49. Ley K, Rivera-Nieves J, Sandborn WJ, Shattil S. Integrin-based therapeutics: biological basis, clinical use and new drugs. Nat Rev Drug Discov. 2016; 15:173–83. [PubMed: 26822833]
50. Stuve O, Marra CM, Bar-Or A, Niino M, Cravens PD, Cepok S, et al. Altered CD4+/CD8+ T-cell ratios in cerebrospinal fluid of natalizumab-treated patients with multiple sclerosis. Arch Neurol. 2006; 63:1383–7. [PubMed: 17030653]
51. Stuve O, Marra CM, Jerome KR, Cook L, Cravens PD, Cepok S, et al. Immune surveillance in multiple sclerosis patients treated with natalizumab. Ann Neurol. 2006; 59:743–7. [PubMed: 16634029]
52. del Pilar Martin M, Cravens PD, Winger R, Frohman EM, Racke MK, Eagar TN, et al. Decrease in the numbers of dendritic cells and CD4+ T cells in cerebral perivascular spaces due to natalizumab. Arch Neurol. 2008; 65:1596–603. [PubMed: 18852339]
53. Milch C, Wyant T, Xu J, Parikh A, Kent W, Fox I, et al. Vedolizumab, a monoclonal antibody to the gut homing alpha4beta7 integrin, does not affect cerebrospinal fluid T-lymphocyte immunophenotype. J Neuroimmunol. 2013; 264:123–6. [PubMed: 24067534]
54. Schwab N, Ulzheimer JC, Fox RJ, Schneider-Hohendorf T, Kieseier BC, Monoranu CM, et al. Fatal PML associated with efalizumab therapy: insights into integrin alphaLbeta2 in JC virus control. Neurology. 2012; 78:458–67. discussion 65. [PubMed: 22302546]
55. Ferenczy MW, Marshall LJ, Nelson CD, Atwood WJ, Nath A, Khalili K, et al. Molecular biology, epidemiology, and pathogenesis of progressive multifocal leukoencephalopathy, the JC virus-induced demyelinating disease of the human brain. Clin Microbiol Rev. 2012; 25:471–506. [PubMed: 22763635]
56. White MK, Khalili K. Pathogenesis of progressive multifocal leukoencephalopathy–revisited. J Infect Dis. 2011; 203:578–86. [PubMed: 21227915]
57. Monaco MC, Jensen PN, Hou J, Durham LC, Major EO. Detection of JC virus DNA in human tonsil tissue: evidence for site of initial viral infection. J Virol. 1998; 72:9918–23. [PubMed: 9811728]
58. Gallia GL, Houff SA, Major EO, Khalili K. Review: JC virus infection of lymphocytes–revisited. J Infect Dis. 1997; 176:1603–9. [PubMed: 9395374]
59. Del Valle L, White MK, Khalili K. Potential mechanisms of the human polyomavirus JC in neural oncogenesis. J Neuropathol Exp Neurol. 2008; 67:729–40. [PubMed: 18648329]
60. Reid CE, Li H, Sur G, Carmillo P, Bushnell S, Tizard R, et al. Sequencing and analysis of JC virus DNA from natalizumab-treated PML patients. J Infect Dis. 2011; 204:237–44. [PubMed: 21673034]
61. Chen Y, Bord E, Tompkins T, Miller J, Tan CS, Kinkel RP, et al. Asymptomatic reactivation of JC virus in patients treated with natalizumab. N Engl J Med. 2009; 361:1067–74. [PubMed: 19741227]
62. Maas RP, Muller-Hansma AH, Esselink RA, Murk JL, Warnke C, Killestein J, et al. Drug-associated progressive multifocal leukoencephalopathy: a clinical, radiological, and cerebrospinal fluid analysis of 326 cases. J Neurol. 2016; 263:2004–21. [PubMed: 27401179]
63. Hellwig K, Gold R. Progressive multifocal leukoencephalopathy and natalizumab. J Neurol. 2011; 258:1920–8. [PubMed: 21647730]
64. Sahraian MA, Radue EW, Eshaghi A, Besliu S, Minagar A. Progressive multifocal leukoencephalopathy: a review of the neuroimaging features and differential diagnosis. Eur J Neurol. 2012; 19:1060–9. [PubMed: 22136455]

Author Manuscript Author Manuscript Author Manuscript Author Manuscript

65. Warnke C, Menge T, Hartung HP, Racke MK, Cravens PD, Bennett JL, et al. Natalizumab and progressive multifocal leukoencephalopathy: what are the causal factors and can it be avoided? Arch Neurol. 2010; 67:923–30. [PubMed: 20697042]
66. Khatri BO, Man S, Giovannoni G, Koo AP, Lee JC, Tucky B, et al. Effect of plasma exchange in accelerating natalizumab clearance and restoring leukocyte function. Neurology. 2009; 72:402–9. [PubMed: 19188571]
67. Clifford DB, De Luca A, Simpson DM, Arendt G, Giovannoni G, Nath A. Natalizumab-associated progressive multifocal leukoencephalopathy in patients with multiple sclerosis: lessons from 28 cases. Lancet Neurol. 2010; 9:438–46. [PubMed: 20298967]
68. Langer-Gould A, Atlas SW, Green AJ, Bollen AW, Pelletier D. Progressive multifocal leukoencephalopathy in a patient treated with natalizumab. N Engl J Med. 2005; 353:375–81. [PubMed: 15947078]
69. Kleinschmidt-DeMasters BK, Tyler KL. Progressive multifocal leukoencephalopathy complicating treatment with natalizumab and interferon beta-1a for multiple sclerosis. N Engl J Med. 2005; 353:369–74. [PubMed: 15947079]
70. Bloomgren G, Richman S, Hotermans C, Subramanyam M, Goelz S, Natarajan A, et al. Risk of natalizumab-associated progressive multifocal leukoencephalopathy. N Engl J Med. 2012; 366:1870–80. [PubMed: 22591293]
71. Lee P, Plavina T, Castro A, Berman M, Jaiswal D, Rivas S, et al. A second-generation ELISA (STRATIFY JCV DxSelect) for detection of JC virus antibodies in human serum and plasma to support progressive multifocal leukoencephalopathy risk stratification. J Clin Virol. 2013; 57:141–6. [PubMed: 23465394]
72. McGuigan C, Craner M, Guadagno J, Kapoor R, Mazibrada G, Molyneux P, et al. Stratification and monitoring of natalizumab-associated progressive multifocal leukoencephalopathy risk: recommendations from an expert group. J Neurol Neurosurg Psychiatry. 2016; 87:117–25. [PubMed: 26492930]
73. Vennegoor A, van Rossum JA, Leurs C, Wattjes MP, Rispens T, Murk JL, et al. High cumulative JC virus seroconversion rate during long-term use of natalizumab. Eur J Neurol. 2016; 23:1079–85. [PubMed: 27018481]
74. Cervera C. Natalizumab-associated progressive multifocal leukoencephalopathy. N Engl J Med. 2012; 367:871. author reply 2.
75. Schwab N, Schneider-Hohendorf T, Melzer N, Cutter G, Wiendl H. Natalizumab-associated PML: Challenges with incidence, resulting risk, and risk stratification. Neurology. 2017; 88:1197–205. [PubMed: 28228564]
76. Haanstra KG, Hofman SO, Lopes Estevao DM, Blezer EL, Bauer J, Yang LL, et al. Antagonizing the alpha4beta1 integrin, but not alpha4beta7, inhibits leukocytic infiltration of the central nervous system in rhesus monkey experimental autoimmune encephalomyelitis. J Immunol. 2013; 190:1961–73. [PubMed: 23365083]
77. Wyant T, Fedyk E, Abhyankar B. An Overview of the Mechanism of Action of the Monoclonal Antibody Vedolizumab. J Crohns Colitis. 2016; 10:1437–44. [PubMed: 27252400]
78. Arvin AM, Wolinsky JS, Kappos L, Morris MI, Reder AT, Tornatore C, et al. Varicella-zoster virus infections in patients treated with fingolimod: risk assessment and consensus recommendations for management. JAMA Neurol. 2015; 72:31–9. [PubMed: 25419615]
79. Bye WA, Jairath V, Travis SPL. Systematic review: the safety of vedolizumab for the treatment of inflammatory bowel disease. Aliment Pharmacol Ther. 2017
80. Sorensen PS. Effects of fingolimod in relapsing-remitting multiple sclerosis. Lancet Neurol. 2014; 13:526–7. [PubMed: 24685277]
81. Brinkmann V, Davis MD, Heise CE, Albert R, Cottens S, Hof R, et al. The immune modulator FTY720 targets sphingosine 1-phosphate receptors. J Biol Chem. 2002; 277:21453–7. [PubMed: 11967257]
82. Mandala S, Hajdu R, Bergstrom J, Quackenbush E, Xie J, Milligan J, et al. Alteration of lymphocyte trafficking by sphingosine-1-phosphate receptor agonists. Science. 2002; 296:346–9. [PubMed: 11923495]

Author Manuscript Author Manuscript Author Manuscript Author Manuscript

83. Oo ML, Thangada S, Wu MT, Liu CH, Macdonald TL, Lynch KR, et al. Immunosuppressive and anti-angiogenic sphingosine 1-phosphate receptor-1 agonists induce ubiquitinylation and proteasomal degradation of the receptor. J Biol Chem. 2007; 282:9082–9. [PubMed: 17237497]
84. Ledgerwood LG, Lal G, Zhang N, Garin A, Esses SJ, Ginhoux F, et al. The sphingosine 1-phosphate receptor 1 causes tissue retention by inhibiting the entry of peripheral tissue T lymphocytes into afferent lymphatics. Nat Immunol. 2008; 9:42–53. [PubMed: 18037890]
85. Morris MA, Gibb DR, Picard F, Brinkmann V, Straume M, Ley K. Transient T cell accumulation in lymph nodes and sustained lymphopenia in mice treated with FTY720. Eur J Immunol. 2005; 35:3570–80. [PubMed: 16285007]
86. Pham TH, Okada T, Matloubian M, Lo CG, Cyster JG. S1P1 receptor signaling overrides retention mediated by G alpha i-coupled receptors to promote T cell egress. Immunity. 2008; 28:122–33. [PubMed: 18164221]
87. Mehling M, Brinkmann V, Antel J, Bar-Or A, Goebels N, Vedrine C, et al. FTY720 therapy exerts differential effects on T cell subsets in multiple sclerosis. Neurology. 2008; 71:1261–7. [PubMed: 18852441]
88. Kovarik JM, Schmouder R, Barilla D, Riviere GJ, Wang Y, Hunt T. Multiple-dose FTY720: tolerability, pharmacokinetics, and lymphocyte responses in healthy subjects. J Clin Pharmacol. 2004; 44:532–7. [PubMed: 15102874]
89. Francis G, Kappos L, O'Connor P, Collins W, Tang D, Mercier F, et al. Temporal profile of lymphocyte counts and relationship with infections with fingolimod therapy. Mult Scler. 2014; 20:471–80. [PubMed: 23950550]
90. Walsh KB, Marsolais D, Welch MJ, Rosen H, Oldstone MB. Treatment with a sphingosine analog does not alter the outcome of a persistent virus infection. Virology. 397:260–9.
91. Mehling M, Hilbert P, Fritz S, Durovic B, Eichin D, Gasser O, et al. Antigen-specific adaptive immune responses in fingolimod-treated multiple sclerosis patients. Ann Neurol. 2011; 69:408–13. [PubMed: 21387383]
92. Kappos L, Mehling M, Arroyo R, Izquierdo G, Selmaj K, Curovic-Perisic V, et al. Randomized trial of vaccination in fingolimod-treated patients with multiple sclerosis. Neurology. 2015; 84:872–9. [PubMed: 25636714]
93. Cervera C. Infections and fingolimod. Rev Neurol. 2012; 55:227–37. [PubMed: 22829086]
94. Ricklin ME, Lorscheider J, Waschbisch A, Paroz C, Mehta SK, Pierson DL, et al. T-cell response against varicella-zoster virus in fingolimod-treated MS patients. Neurology. 2013; 81:174–81. [PubMed: 23700335]
95. Cohen JA, Barkhof F, Comi G, Hartung HP, Khatri BO, Montalban X, et al. Oral fingolimod or intramuscular interferon for relapsing multiple sclerosis. N Engl J Med. 2010; 362:402–15. [PubMed: 20089954]
96. Pfender N, Jelcic I, Linnebank M, Schwarz U, Martin R. Reactivation of herpesvirus under fingolimod: A case of severe herpes simplex encephalitis. Neurology. 2015; 84:2377–8. [PubMed: 25957334]
97. Hagiya H, Yoshida H, Shimizu M, Motooka D, Nakamura S, Iida T, et al. Herpes zoster laryngitis in a patient treated with fingolimod. J Infect Chemother. 2016; 22:830–2. [PubMed: 27553068]
98. Tseng HF, Schmid DS, Harpaz R, LaRussa P, Jensen NJ, Rivailler P, et al. Herpes zoster caused by vaccine-strain varicella zoster virus in an immunocompetent recipient of zoster vaccine. Clin Infect Dis. 2014; 58:1125–8. [PubMed: 24470276]
99. Costa E, Buxton J, Brown J, Templeton KE, Breuer J, Johannessen I. Fatal disseminated varicella zoster infection following zoster vaccination in an immunocompromised patient. BMJ. 2016 Case Rep 2016.
100. Cunningham AL. The herpes zoster subunit vaccine. Expert Opin Biol Ther. 2016; 16:265–71. [PubMed: 26865048]
101. Lal H, Cunningham AL, Godeaux O, Chlibek R, Diez-Domingo J, Hwang SJ, et al. Efficacy of an adjuvanted herpes zoster subunit vaccine in older adults. N Engl J Med. 2015; 372:2087–96. [PubMed: 25916341]

Author Manuscript Author Manuscript Author Manuscript Author Manuscript

102. Cunningham AL, Lal H, Kovac M, Chlibek R, Hwang SJ, Diez-Domingo J, et al. Efficacy of the Herpes Zoster Subunit Vaccine in Adults 70 Years of Age or Older. N Engl J Med. 2016; 375:1019–32. [PubMed: 27626517]
103. Forrestel AK, Modi BG, Longworth S, Wilck MB, Micheletti RG. Primary Cutaneous Cryptococcus in a Patient With Multiple Sclerosis Treated With Fingolimod. JAMA Neurol. 2016; 73:355–6. [PubMed: 26751160]
104. Seto H, Nishimura M, Minamiji K, Miyoshi S, Mori H, Kanazawa K, et al. Disseminated Cryptococcosis in a 63-year-old Patient with Multiple Sclerosis Treated with Fingolimod. Intern Med. 2016; 55:3383–6. [PubMed: 27853088]
105. Ward MD, Jones DE, Goldman MD. Cryptococcal meningitis after fingolimod discontinuation in a patient with multiple sclerosis. Mult Scler Relat Disord. 2016; 9:47–9. [PubMed: 27645342]
106. Artemiadis AK, Nikolaou G, Kolokythopoulos D, Tegos N, Terentiou A, Triantafyllou N, et al. Visceral leishmaniasis infection in a fingolimod-treated multiple sclerosis patient. Mult Scler. 2015; 21:795–6. [PubMed: 25432949]
107. Behle V, Wobser M, Goebeler M, Stoevesandt J. Extensive molluscum contagiosum virus infection in a young adult receiving fingolimod. Mult Scler. 2016; 22:969–71. [PubMed: 26860987]
108. Gyang TV, Hamel J, Goodman AD, Gross RA, Samkoff L. Fingolimod-associated PML in a patient with prior immunosuppression. Neurology. 2016; 86:1843–5. [PubMed: 27164718]
109. Faulkner M. Risk of progressive multifocal leukoencephalopathy in patients with multiple sclerosis. Expert Opin Drug Saf. 2015; 14:1737–48. [PubMed: 26394704]
110. Manasanch EE, Orlowski RZ. Proteasome inhibitors in cancer therapy. Nat Rev Clin Oncol. 2017; 14:417–33. [PubMed: 28117417]
111. Richardson PG, Sonneveld P, Schuster MW, Irwin D, Stadtmauer EA, Facon T, et al. Bortezomib or high-dose dexamethasone for relapsed multiple myeloma. N Engl J Med. 2005; 352:2487–98. [PubMed: 15958804]
112. San Miguel JF, Schlag R, Khuageva NK, Dimopoulos MA, Shpilberg O, Kropff M, et al. Bortezomib plus melphalan and prednisone for initial treatment of multiple myeloma. N Engl J Med. 2008; 359:906–17. [PubMed: 18753647]
113. Dimopoulos MA, Moreau P, Palumbo A, Joshua D, Pour L, Hajek R, et al. Carfilzomib and dexamethasone versus bortezomib and dexamethasone for patients with relapsed or refractory multiple myeloma (ENDEAVOR): a randomised, phase 3, open-label, multicentre study. Lancet Oncol. 2016; 17:27–38. [PubMed: 26671818]
114. Manasanch EE, Orlowski RZ. Proteasome inhibitors in cancer therapy. Nat Rev Clin Oncol. 2017
115. Behrendt V, Krogias C, Reinacher-Schick A, Gold R, Kleiter I. Bortezomib Treatment for Patients With Anti-N-Methyl-d-Aspartate Receptor Encephalitis. JAMA Neurol. 2016; 73:1251–3. [PubMed: 27533122]
116. Sadaka B, Ejaz NS, Shields AR, Cardi MA, Wadih G, Witte D, et al. A Banff Component Scoring-based Histologic Assessment of Bortezomib-based Antibody-mediated Rejection Therapy. Transplantation. 2015; 99:1691–9. [PubMed: 25803498]
117. Blimark C, Holmberg E, Mellqvist UH, Landgren O, Bjorkholm M, Hultcrantz M, et al. Multiple myeloma and infections: a population-based study on 9253 multiple myeloma patients. Haematologica. 2015; 100:107–13. [PubMed: 25344526]
118. Wondergem MJ, Grunberg K, Wittgen BP, Sonneveld P, Zweegman S. Interstitial pneumonitis caused by Pneumocystis jirovecii pneumonia (PCP) during bortezomib treatment. Histopathology. 2009; 54:631–3. [PubMed: 19302537]
119. Kim SJ, Kim K, Kim BS, Lee HJ, Kim H, Lee NR, et al. Bortezomib and the increased incidence of herpes zoster in patients with multiple myeloma. Clin Lymphoma Myeloma. 2008; 8:237–40. [PubMed: 18765311]
120. Teh BW, Teng JC, Urbancic K, Grigg A, Harrison SJ, Worth LJ, et al. Invasive fungal infections in patients with multiple myeloma: a multi-center study in the era of novel myeloma therapies. Haematologica. 2015; 100:e28–31. [PubMed: 25304609]
121. Teh BW, Worth LJ, Harrison SJ, Thursky KA, Slavin MA. Risks and burden of viral respiratory tract infections in patients with multiple myeloma in the era of immunomodulatory drugs and

Author Manuscript Author Manuscript Author Manuscript Author Manuscript

bortezomib: experience at an Australian Cancer Hospital. Support Care Cancer. 2015; 23:1901–6. [PubMed: 25487843]

122. Figueroa CJ, Camp BJ, Varghese GI, Miranda E, Querfeld C, Hassoun H, et al. A case of protothecosis in a patient with multiple myeloma. J Cutan Pathol. 2014; 41:409–13. [PubMed: 24758253]

Author Manuscript Author Manuscript Author Manuscript Author Manuscript

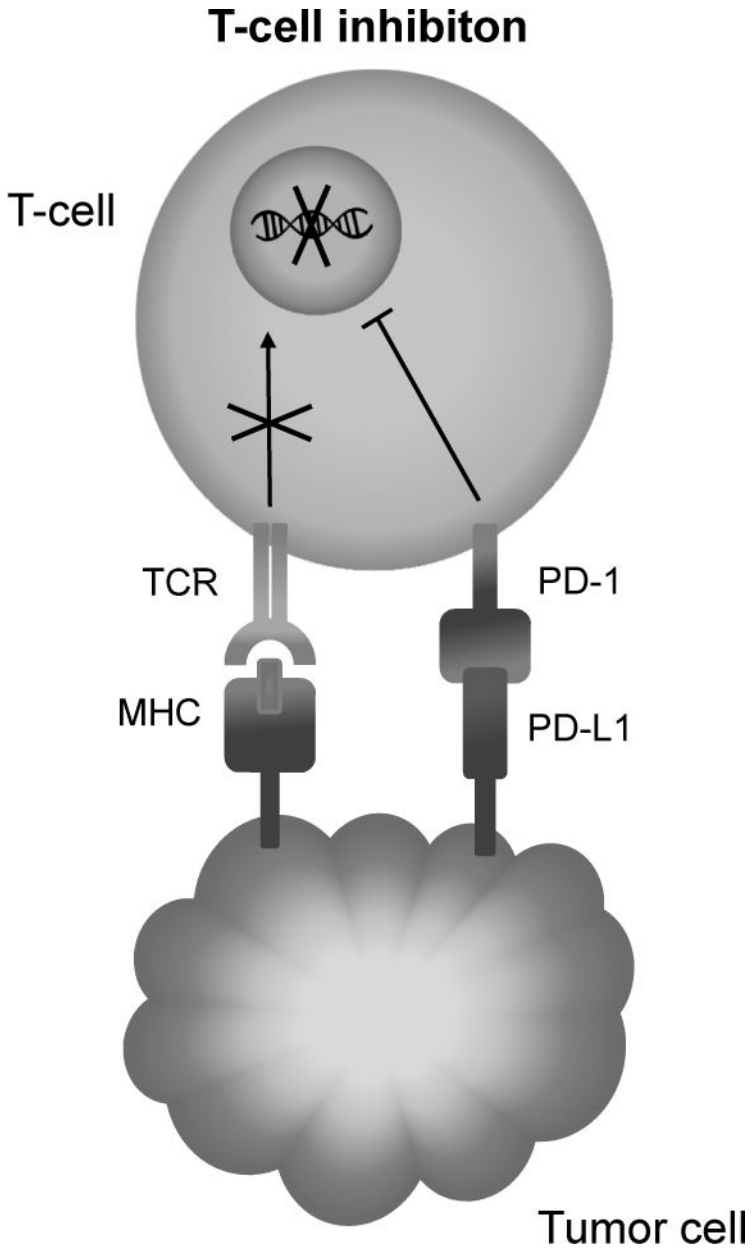

Figure 1.

Mode of action of CTLA-4-targeted agents: Ipilimumab and tremelimumab are monoclonal antibodies that binds CTLA-4, thus preventing engagement by agonist ligands like B7-1 (CD80) and B7-2 (CD86) and blocking its inhibitory effect on T-cell priming.

Author Manuscript Author Manuscript Author Manuscript Author Manuscript

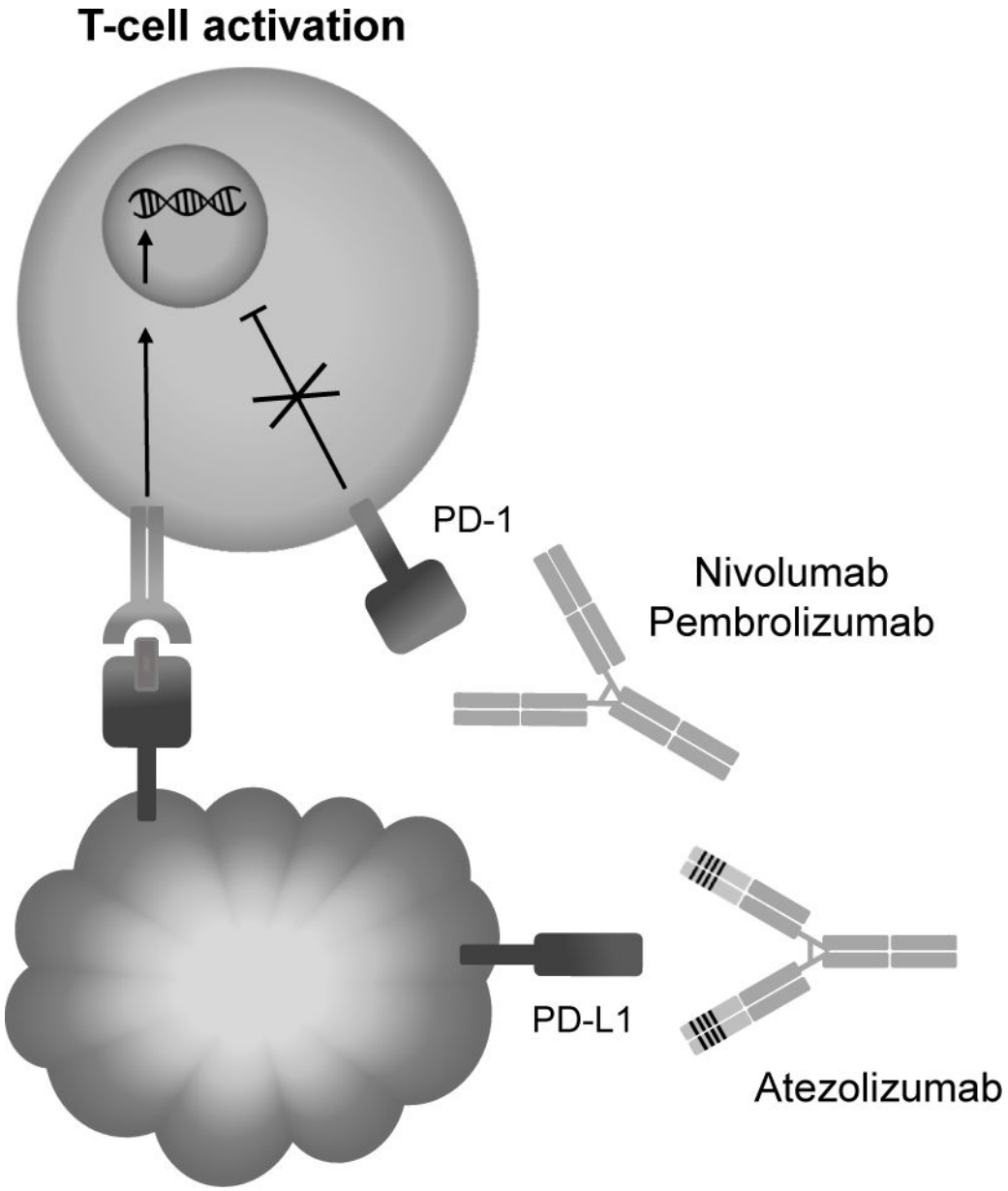

Figure 2.

Mode of action of PD-1 and PD-L1-targeted agents: Nivolumab and pembrolizumab are monoclonal antibodies targeting PD-1, whereas atezolizumab targets PD-L1. PD-1 inhibitory action on T-cells is mediated by its engagement by PD-L1, whose expression is induced by INF-γ secreted by T-cells infiltrating tumor tissues. PD-1 blockade allows to cut such negative loops and restore anti-tumor immunity.

Author Manuscript Author Manuscript Author Manuscript Author Manuscript

Table 1

Summary of infection risks associated with the use of reviewed targeted agents.

Agents	Pathway affected	Current indications	Increased risk of infection	Observations
Ipilimumab, tremelimumab	CTLA-4	Melanoma	Variable	• No intrinsic increase in the risk of infection • Increased risk of infection in patients developing irAEs and treated with additional immunosuppressive (i.e., corticosteroids and/or TNF-α-targeted agents)
Nivolumab, pembrolizumab, atezolizumab	PD-1 or PD-L1	Melanoma, NSCLC, HNSCC, Hodgkin lymphoma, urothelial carcinoma, bladder carcinoma, metastatic RCC, tumor with microsatellite instability	Variable	• No intrinsic increase in the risk of infection • Increased risk of infection in patients developing irAEs and treated with additional immunosuppressive (i.e., corticosteroids and/or TNF-α-targeted agents)
Alefacept	LFA-3/CD2 interaction	Plaque psoriasis (currently withdrawn)	Minor	• No apparent increase in the risk of infection (currently halted for economic reasons, not safety issues) • Transient peripheral blood CD4+ T-cell lymphopenia
Natalizumab, vedolizumab, efalizumab	α4β1, α4β7 and αLβ2 (CD11a subunit) integrins	MS, Crohn's disease, plaque psoriasis (currently withdrawn)	Major	• Increased risk of PML associated with the use of natalizumab and efalizumab (no cases described so far with vedolizumab) • Risk factors for natalizumab-induced PML include pre-treatment JCV serostatus, anti-JCV IgG antibody index, prior immunosuppression, and duration of treatment
Fingolimod	Sphingosine-1-phosphate receptor	Relapsing-remitting MS	Mild	• Increase in the risk of opportunistic infections, mainly due to herpesviruses (VZV) • Sustained, albeit reversible, peripheral blood lymphopenia (mostly affecting

Author Manuscript Author Manuscript Author Manuscript Author Manuscript

Agents	Pathway affected	Current indications	Increased risk of infection	Observations
				naïve and central memory CD4+ and CD8+ T-cell subsets)
Bortezomib, carfilzomib, ixazomib	Ubiquitin proteasome pathway	MM, relapsed or refractory mantle cell lymphoma	Major	• Increased risk of HZ and respiratory tract infections (including pneumonia) • Likely increased risk of influenza-related complications

CTLA-4: cytotoxic T-lymphocyte-associated antigen 4; HNSCC: head and neck squamous-cell carcinoma; HZ: herpes zoster; irAE: immune-related adverse effect; JCV: John Cunningham polyomavirus; LFA: lymphocyte function-associated antigen; MS; multiple sclerosis; NSCLC: non-small cell lung carcinoma; PD: programed death; PML: progressive multifocal leukoencephalopathy; RCC: renal cell carcinoma; TNF: tumour necrosis factor.

Author Manuscript Author Manuscript Author Manuscript Author Manuscript

Table 2

Summary of suggested recommendations and management strategies.

Agents	Increased risk of PCP	*Anti-Pneumocystis* prophylaxis	Increased risk of VZV or HSV infection	Vaccinations	Other prophylaxis or recommendations
Ipilimumab, tremelimumab	Increased risk in patients developing irAEs and receiving corticosteroids	Patients with irAEs expected to receive 20 mg of prednisone daily (or equivalent) for ≥4 weeks	No	As per standard practice	Potential risk of IRIS with unmasking of latent (dormant) infections (i.e., LTBI)
Nivolumab, pembrolizumab, atezolizumab	Increased risk in patients developing irAEs and receiving corticosteroids	Patients with irAEs expected to receive 20 mg of prednisone daily (or equivalent) for ≥4 weeks	No	As per standard practice	Potential risk of IRIS with unmasking of latent (dormant) infections (i.e., LTBI)
Alefacept	No increased risk observed (theoretical risk if persistent decrease of CD4+ T-cell counts)	No	No	As per standard practice	Monitor for CD4+ T-cells, with drug discontinuation if counts <250 cells/μL
Natalizumab, vedolizumab, efalizumab	No	No	No	As per standard practice	• Test for anti-JCV IgG antibodies before starting treatment with natalizumab • Retest every 6 months after the first year of treatment in JCV-seronegative patients and JCV-seropositive patients with an IgG antibody index ≤1.5 • Consider discontinuing natalizumab therapy in patients at high-risk of PML (positive anti-JCV serology with an IgG antibody index >1.5, ≥48 months of therapy) • Early drug discontinuation and plasma exchange or immunoadsorption in case of natalizumab-induced PML
Fingolimod	No increased risk observed (theoretical risk if persistent decrease of CD4+ T-cell counts)	No increased risk observed (theoretical risk if persistent decrease of CD4+ T-cell counts)	Yes	•·Live attenuated varicella vaccination for VZV-seronegative patients without history of varicella (at least 1 month before starting therapy) • HZ/su may be considered for VZV-seropositive patients aged ≥50 years	Antiviral prophylaxis for herpesviruses with (val)acyclovir may be considered for selected patients with additional risk factors (i.e., prolonged high-dose corticosteroid therapy)
Bortezomib, carfilzomib, ixazomib	No	May be considered for selected MM patients with additional risk factors (i.e., prolonged high-dose corticosteroid therapy)	Yes	• Live attenuated varicella vaccination for VZV-seronegative patients without history of varicella (at least 1	Antiviral prophylaxis with (val)acyclovir for VZV-seropositive patients during induction therapy and

Author Manuscript Author Manuscript Author Manuscript Author Manuscript

Agents	Increased risk of PCP	*Anti-Pneumocystis* prophylaxis	Increased risk of VZV or HSV infection	Vaccinations	Other prophylaxis or recommendations
				month before starting therapy) • HZ/su may be considered for VZV-seropositive patients aged ≥50 years • Seasonal TIV (at least 2 weeks before starting therapy and annually thereafter) • Completed pneumococcal vaccination series (PCN7 or PCN13 followed by PPV23) (at least 2 weeks before starting therapy) with revaccination 5 years latter with PPV23	for at least 4 weeks after its discontinuation

HSV: herpes simplex virus; HZ/su: adjuvanted subunit zoster vaccine; irAE: immune-related adverse effect; JCV: John Cunningham polyomavirus; PCP: *Pneumocystis jirovecii* pneumonia; PCV7/13: 7-valent/13-valent pneumococcal conjugate vaccine; PML: progressive multifocal leukoencephalopathy; PPV23: 23-valent pneumococcal polysaccharide vaccine; TIV: seasonal trivalent inactivated influenza vaccine; VZV: varicella-zoster virus.