

A Rare Case Report of Angiolymphoid Hyperplasia with Eosinophilia Arising in a Lipoma

DURGA ANURADHA AGASTYARAJU, ANITA SHOBHA FLYNN, ANITHA RAMAKRISHNA, SUNITHA N, BS GIRIDHAR

ABSTRACT

Angiolymphoid Hyperplasia with Eosinophilia (ALHE) is a rare vascular disorder of controversial etiology, as to whether it is reactive or neoplastic. The usual site of occurrence is the head and neck area and sometimes in trunk and extremities. It is more commonly seen in women and in Asian population. We present a case of a 65 years old man who presented with a painless gradually increasing swelling in the interscapular region of the

back which was diagnosed both clinically and on FNAC as a lipoma. Excision biopsy done subsequently revealed a benign lipomatous mass with variably sized firm grey white nodules showing histopathological features of ALHE in a lipoma. To the best of our knowledge, this is the first such case in literature of ALHE occurring in a lipoma which we are publishing for its unique presentation and morphology. Informed consent was taken from the patient prior to the procedure.

Keywords: Lymphovascular proliferation, Eosinophils, Endothelial cells

CASE REPORT

A 65-year-old male patient presented with a swelling over the back for the last 15 years. It was painless and gradually increasing in size. There was no history of previous trauma or allergies or infection. No relevant family history of such a lesion was reported by the patients. No other co-morbidities were present.

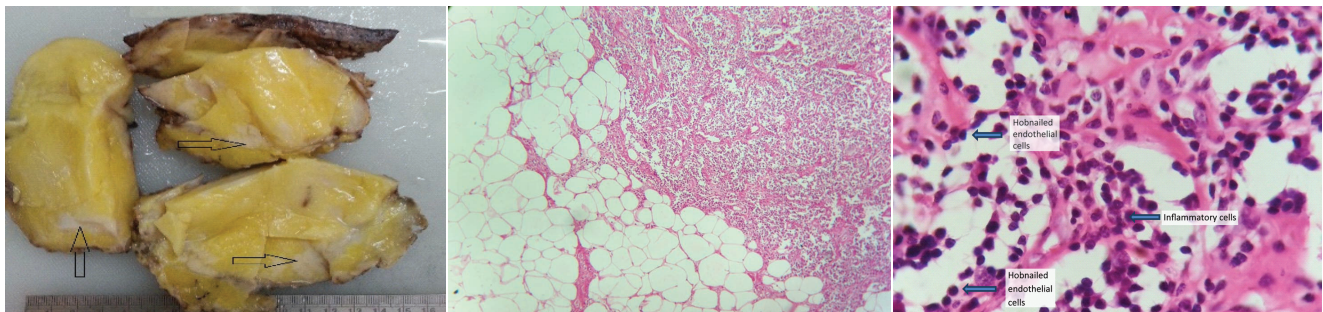
On examination, a swelling measuring 12x10 cm over the back was seen 3 cm below the nape of neck. Slip sign was positive. The swelling was soft, non-fluctuant and non-transilluminant. Skin over the swelling was normal in appearance. A clinical diagnosis of lipoma was made.

Fine Needle Aspiration Cytology (FNAC) findings showed a lipomatous lesion. Other investigations including eosinophil count were normal. An excision biopsy of the mass was performed and the swelling was excised in toto and sent for

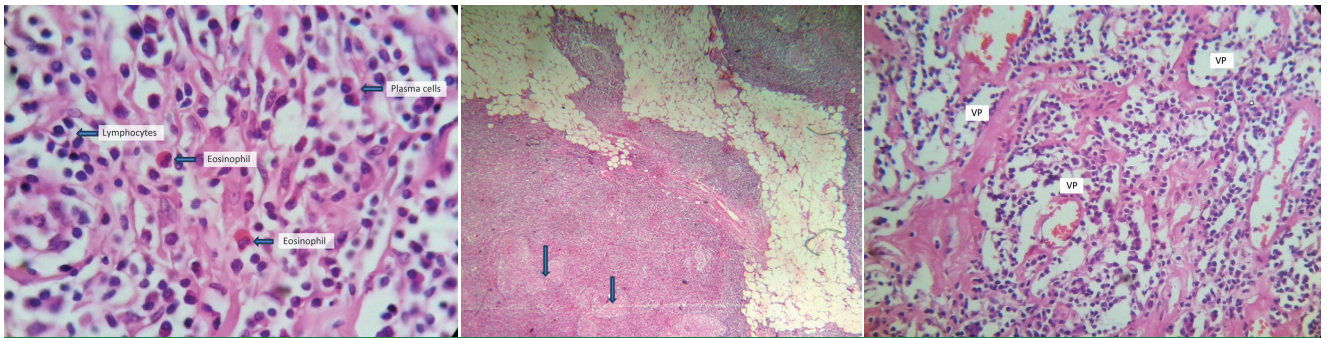
histopathological examination.

The biopsy was an oval encapsulated yellow soft tissue mass measuring 12x11x5 cm. An ellipse of skin measuring 11x8 cm was present on one aspect. Cut section showed yellow fatty areas with scattered irregular firm grey white areas [Table/Fig-1]. Multiple representative sections were taken.

Microscopy showed a benign encapsulated lipomatous tumor composed of lobules of mature fibro-adipose tissue intersected by delicate fibro-vascular septae. Interspersed amongst these lobules were seen discrete islands of nodular lympho-vascular proliferation comprising of a haphazard arrangement of blood vessels surrounded by a variably dense lymphoid infiltrate [Table/Fig-2]. The blood vessels varied from irregular, poorly canalized, thin walled spaces to rounded well-formed vessels with thickened walls. Vascular channels were lined by endothelial cells showing cobble-



[Table/Fig-1]: Gross picture of encapsulated lipoma with scattered irregular firm grey white areas of ALHE (arrows). **[Table/Fig-2]:** 40X, H & E. Lobules of mature adipose tissue with adjacent nodular lymphovascular proliferation. **[Table/Fig-3]:** 100X, H & E. Hobnail appearance of vascular channels with interspersed lymphocytes and plasma cells.



[Table/Fig-4]: 100X, H & E. Lymphoplasmacytic infiltrate with interspersed eosinophils. **[Table/Fig-5]:** 40X, H & E. Lymphoid follicles with ill-formed germinal centres (arrows). **[Table/Fig-6]:** 40X, H & E. Vascular proliferation (VP) with inflammatory infiltrate. All the vascular channels are lined by epithelioid endothelial cells presenting a hobnail appearance.

stoned or hobnail appearance [Table/Fig-3]. The inflammatory component surrounding the vascular channels comprised of an admixture of lymphocytes, plasma cells and few scattered mast cells and eosinophils [Table/Fig-4]. At places, lymphoid follicles with ill - formed germinal centers were also noted [Table/Fig-5,6]. There was no atypia seen.

The differential diagnosis of Kimura's disease and lymphoma were considered. The former was ruled out due to the paucity of eosinophils, presence of marked vascular proliferation, superficial location and no lymph node involvement in our lesion. The possibility of lymphoma was ruled out because of absence of atypical cells, presence of mature lymphocytes and prominent vascular channels lined by epithelioid endothelial cells. The final diagnosis of lipoma with an incidental finding of angiolymphoid hyperplasia with eosinophilia was made.

The patient was asymptomatic on follow-up.

DISCUSSION

ALHE is a benign vasoproliferative disease, the etiology of which is debatable [1]. A history of preceding trauma or infection is found in 9% of the cases [2]. Median age of involvement is between second and 4th decade [1,3]. Females are more often affected [3]. It is more commonly seen in the Asian population [1].

The lesions may be solitary or multiple and are characterized by smooth surfaced, red to brown papules or nodules with diameters between 0.5 – 3.0 cm [1,4]. These lesions at times may be multilobated and poorly delineated [5,6]. Our case is a rare presentation of ALHE occurring as multiple nodules within a lipoma over the upper back. Microscopy showed nodular lymphovascular lesion comprising of a proliferation of blood vessels with thickened walls. The vessels were lined by plump (epithelioid) endothelial cells exhibiting a "cobblestone" appearance. A characteristic chronic inflammatory infiltrate comprising of lymphocytes, plasma cells, histiocytes and eosinophils was seen in the perivascular and interstitial tissues. Eosinophils account for 5-15% of the infiltrate but rarely, may be seen up to 50%. Focal lymphoid follicle formation is also noted [3,7,8].

ALHE has been a controversial lesion with regard to its classification and its relationship to Kimura's disease. However, recent studies have shown that clinical and histologic differences between the two entities support their existence as two distinct clinicopathologic entities [8,9]. Kimura's disease is seen more in males and in Asians. It is often associated with regional lymphadenopathy and peripheral eosinophilia and characterized by larger nodules located more deeply, extending to subcutaneous fat, fascia and skeletal muscle [4,8]. Histologically, the vascular component is sparse with minimal epithelioid endothelial changes. The inflammatory component is chiefly lymphoid with eosinophils and eosinophilic microabscesses [4,8]. ALHE, on the other hand, does not, or rarely, affects lymph nodes. Peripheral eosinophilia is not common and the lesions are more superficially situated in the dermis or subcutis [8]. The vascular proliferation is prominent with epithelioid endothelial cells and a variable admixture of inflammatory cells [8].

Treatment options range from intra-lesional injections of isotretinoin, glucocorticoids, interferon-2 α , cytotoxic agents to irradiation. However, surgical excision remains the treatment of choice with follow-up as recurrence rate up to 33% is seen due to the multilobation and poor delineation of the lesions [5].

CONCLUSION

This is a rare occurrence of angiolymphoid hyperplasia with eosinophilia occurring in a lipoma. The entity was masked as it occurred multifocal in a lipomatous tumour. The surgeon and the pathologist did not anticipate this entity on clinical or FNAC examination as in both, the lesion had presented as a lipoma. Therefore, this is an interesting case which brings to our knowledge another unusual site in which ALHE can occur.

REFERENCES

- [1] Zaraa I, Milka M, Chouk S, Chelly I, Mokni M, Zitouna M, et al. Angiolymphoid hyperplasia with eosinophilia: A study of 7 cases. *Dermatol Online J.* 2011;17(2):1.

- [2] Adler BL, Krausz AE, Minuti A, Silverberg JI, Lev-Toh H. Epidemiology and treatment of angiolymphoid hyperplasia with eosinophilia (ALHE): A systematic review. *J Am Acad Dermatol*. 2016;74(3):506-12.e11.
- [3] Weiss SW, Goldblum JR. Benign tumours and tumour – like lesions of blood vessels. In: Enzinger FM, Weiss SW, eds. *Soft Tissue Tumours*. 4th ed. Philadelphia, PA: The CV Mosby Co. 2001:856 -64.
- [4] Kukreja N, Koslowski M, Insall R. Angiolymphoid hyperplasia with eosinophilia presenting as an axillary artery aneurysm. *BMJ Case Reports*. 2011; doi:10.1136/bcr.02.2011.3836.
- [5] Al-Muharraqi MA, Faqi MK, Uddin F, Ladak K, Darwish A. Angiolymphoid hyperplasia with eosinophilia (epithelioid hemangioma) of the face: An unusual presentation. *Int J Surg Case Rep*. 2011;2(8):258-60.
- [6] Tchernev G, Taneva T, Ananiev J, Cardoso JC, Gulubova M, Velez V, et al. Angiolymphoid hyperplasia with eosinophilia - an incidental finding after surgical excision. *Wien Med Wochenschr*. 2012;162(19-20):448-51.
- [7] Meyerle J, Glusac E. Angiolymphoid hyperplasia with eosinophilia, 2005. www.emedicine.com/derm/topic30.htm [last accessed January 2006].
- [8] Wenig BM. Acquired Non-neoplastic Lesions of the External and Middle Ear. In: Mills SE, Carter D et al, eds. *Sternberg's Diagnostic Surgical Pathology*. Fourth Edition. Philadelphia, PA: Lippincott William & Wilkins. 2004:1043-45.
- [9] Buder K, Ruppert S, Trautmann A, Bröcker EB, Goebeler M, Kerstan A. Angiolymphoid hyperplasia with eosinophilia and Kimura's disease – a clinical and histopathological comparison. *J Dtsch Dermatol Ges*. 2014;12(3):224-28.

AUTHOR(S):

1. Dr. Durga Anuradha Agastyaraju
2. Dr. Anita Shobha Flynn
3. Dr. Anitha Ramakrishna
4. Dr. Sunitha N
5. Dr. BS Giridhar

PARTICULARS OF CONTRIBUTORS:

1. Junior Consultant, Department of Pathology, St. Martha's Hospital, Bengaluru, Karnataka, India.
2. Senior Consultant and Head, Department of Pathology, St. Martha's Hospital, Bengaluru, Karnataka, India.
3. Clinical Pathologist, Department of Pathology, St. Martha's Hospital, Bengaluru, Karnataka, India.

4. Senior Registrar, Department of Pathology, St. Martha's Hospital, Bengaluru, Karnataka, India.
5. Senior Consultant, Department of Surgery, St. Martha's Hospital, Bengaluru, Karnataka, India.

NAME, ADDRESS, E-MAIL ID OF THE CORRESPONDING AUTHOR:

Dr. Anita Shobha Flynn,
Central Laboratory, St. Martha's Hospital,
No.5 Nrupathunga Road,
Bengaluru-560001, Karnataka, India.
E-mail: atflynn@gmail.com

FINANCIAL OR OTHER COMPETING INTERESTS:

None.

Date of Publishing: **Apr 01, 2017**