

Histological Structure of the Placenta and Umbilical Cord in Sudanese and Correlation with Neonatal Outcome

Motaz Nuggedalla*

Assistant Professor, Department of Anatomy at University of Albutana, Sudan

***Corresponding Author:** Motaz Nuggedalla, Assistant Professor, Department of Anatomy at University of Albutana, Sudan.

Received: August 19, 2022

Published: August 29, 2022

© All rights are reserved by **Motaz Nuggedalla.**

Abstract

Background: This study described the common histological structure of the placenta and umbilical cord completely on singleton pregnancies delivered at term, as defined by pathologists who did not fully know all the clinical information; Abnormalities were reported based on predefined criteria. The histological structure of the placenta and umbilical cord has been studied and correlated with neonatal outcomes.

Methods: A hospital - based prospective study done in Wad Madani Maternity Teaching Hospital Department of Obstetrics and Gynecology between July 2014 and March 2018.

Results: There was a significant positive correlation (r) between histological indices of Placentae, Normal histology (357) 96.2%, Chronioamnionitis (8) 2.2%, Intervillous thrombus (4) 1.1% and Fetal Thrombotic Vasculopathy (2) 0.5% with weight of placenta ($M = 515.5$ SD = 65 gms), ($r = 0.16$, $p = 0.002$), Diameter of Placenta ($M = 18.8$ SD = 1.5 cm), ($r = 0.10$, $p = 0.05$), Thickness of Placenta ($M = 2.42$ SD = .4 cm), ($r = 0.10$, $p = 0.04$) and weight of neonates ($M = 2.9$ SD = .5 kg), ($r = 0.20$, $p = 0.000$) and significant negative correlation with length of neonates ($M = 44.4$ SD = 7 cm), ($r = - 0.10$, $p = 0.05$). But there were not any correlations between histological variables and gross morphometric of umbilical cord variables.

Conclusion: There was a significantly positive correlation between histological indices of Placentae there were not any correlations between histological variables and gross morphometric of umbilical cord variables.

Keywords: Umbilical Cord; Histological; Neonate; Placenta; Outcome; Chronioamnionitis

Introduction

There is little or no attention among clinicians and pathologists regarding the relationship of neonatal outcome with some placental and umbilical cord histological features, specific placental histological features with umbilical cord and placental morphology and placental umbilical cord morphology with neonatal outcome, especially in the low-risk groups [1,2].

Recently study has highlighted the methodological difficulties in deriving and reproducing umbilical cord coiling index [3]. However, the abnormal coiling of the cord has been reported in

association with adverse neonatal outcomes such as preterm delivery, fetal death, low APGAR score and IUGR [4-6].

Villitis of unknown etiology is one of the more commonly found placental abnormalities and has been reported in association with recurrent reproductive failure [7-10], neonatal asphyxia [11] and adverse fetal neurological outcomes [12]. However, there are no previous data suggesting an association of Villitis of unknown etiology and placentae and umbilical cord and their significance; if any, it is uncertain.

A real weakness is that a relationship between morphology and histological structure of the placenta and umbilical cord was

exist where there were not any correlations between histological variables and gross morphometric of umbilical cord variables and reported generally exceed those of previous studies.

Materials and Methods

Study design

This is a hospital - based prospective study done in Wad Madani Maternity Teaching Hospital Gezira State. It aimed to assess the histological study on umbilical cord & placenta and its impact to the neonatal outcomes.

Sample size and study population

This study on the placenta and umbilical cord of 371 neonates born in the Wad Madani Maternity Teaching Hospital during the period of the study during the period (between July 2014 and March 2018), all these were included criteria. Sample size was calculated according to the following equation formula [13]:

$$n = \frac{c^2 N p(1-p)}{(A^2 N) + (c^2 p[1-p])}$$

n = is the sample size required

N = is the whole target population in question

P = is the average proportion of records expected to meet the various criteria (1-p) is the average proportion of records not expected to meet the criteria

A = is the margin of error deemed to be acceptable

c = is a mathematical constant defined by the Confidence Interval chosen

Data collection

Data has been classified into following three categories:

- Maternal
- Umbilical cord and placenta
- Neonate details

Maternal details

Maternal details obtained from the case sheets of enrolled subjects, are as follows. Name (for file only), Hospital number, Age, LMP, EDD and term of gestation and Obstetric history.

Umbilical cord and placenta: collected as below:

Umbilical cord and placenta fixed in 10% formalin and processed for routine paraffin embedment. Tissue pieces measuring 2x2cm from standard area, i.e., 2cm from edge and 2cm from the attachment of umbilical cord were taken. Four-micron thick sections cut on rotary microtome from the middle of each specimen and mounted on clean gelatinized slides, stained with H and E.

Neonate details

The neonate details include date of delivery (DOD), gender, APGAR Score at 1 minute and 5 minutes, total length (Height), head circumference in centimeters, weight in Kilograms and anomalies if present were recorded from neonate’s file immediately followed by the delivery. All the neonates followed up for their hospital stay to rule out anomalies. Newborn’s birth weight < 2.5 Kg, 2.5 to 3.8 Kg and > 3.8 Kg has been considered as low birth weight, normal birth weight and large for gestational age (LGA) respectively. On the other hand, gestational age (GA) less than 37 weeks has been considered as preterm, 37 to 42 weeks as term and more than 42 weeks was post term.

Data analysis: Data was analyzed by statistical package for social science (SPSS). Data was displayed by tables and histogram.

Results

Histology analysis was performed in 371 cases. Normal histology (357) 96.2%, Chronioamnionitis (8) 2.2%, Intervillous thrombus (4) 1.1% and Fetal Thrombotic Vasculopathy (2) 0.5% as table 1.

Predefined histological features	Frequency	Percent
Normal histology	357	96.2
Chorioamnionitis	8	2.2
Intervillous thrombus	4	1.1
Fetal Thrombotic Vasculopathy	2	.5
TOTAL	371	100

Table 1: Incidence of predefined histological lesions.

Histological indices relation with neonatal outcome

The histology of Placentae and umbilical cord parameters and neonatal outcomes were analyzed with Pearson’s correlation to find out the association between them, There was a significant

positive correlation (r) between histological indices of Placentae and umbilical cord (Normal histology (357) 96.2%as figure 1, Chronioamnionitis (8) 2.2%, Intervillous thrombus (4) 1.1% as figure 2 and Fetal Thrombotic Vasculopathy (2) 0.5%) with weight of neonates (M = 2.9 SD = .5 kg),(r = 0.20, p = 0.000 and significant negative correlation with length of neonates (M = 44.4 SD = 7cm), (r = - 0.10, p = 0.05). As show in table 2.




Figure 1: Microscope images showing normal histology appearance with H and E stain.

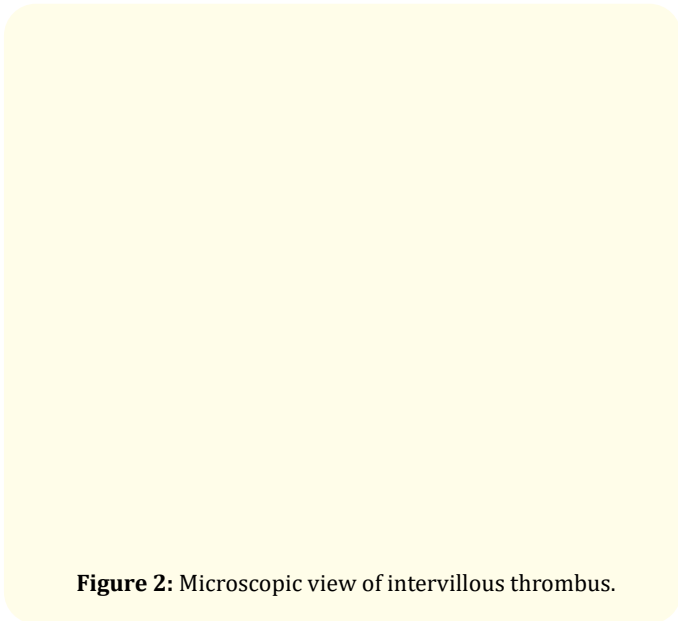


Figure 2: Microscopic view of intervillous thrombus.




Figure 3: Microscopic view of chorioamnionitis.

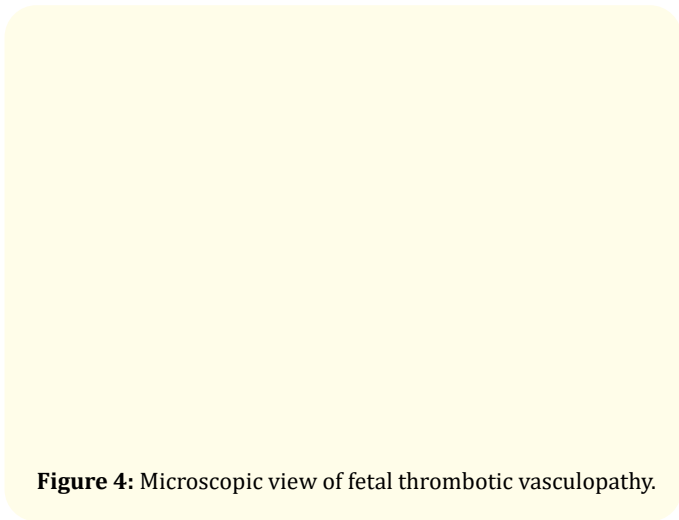


Figure 4: Microscopic view of fetal thrombotic vasculopathy.

		AS	WN	HC	LN
Histological indices of Placentae and umbilical cord	Pearson Correlation	.077	.200**	.003	-.104*
	Sig. (2-tailed)	.140	.000	.954	.045
	N	371	371	371	371

Table 2: Correlation between histological indices with neonatal outcome.

AS = APGAR Score , WN = Weight of Neonates , HC = Head Circumference , LN = Length of Neonates.

** . Correlation is significant at the 0.01 level (2-tailed).

* . Correlation is significant at the 0.05 level (2-tailed).

The normal histology is associated with normal fetal weight, while it is also associated with decreased fetal length. As show in table 3.

		AS	WN	HC	LN
Length of UC	Pearson Correlation	.027	-.012	.044	.724**
	Sig. (2-tailed)	.600	.815	.398	.000
Diameter of UC	Pearson Correlation	-.146**	-.319**	-.008	.453**
	Sig. (2-tailed)	.005	.000	.877	.000

Table 3: Correlation between umbilical cord variables and neonatal outcome.

AS = APGAR score, WN = Weight of Neonates, HC = Head Circumference, LN = Length of Neonates, UC = Umbilical cord.

** . Correlation is significant at the 0.01 level (2-tailed).

* . Correlation is significant at the 0.05 level (2-tailed).

Discussion

The placental pathology has been correlated with untoward neonatal outcome particularly central nervous system developmental outcome, even in normally mature term infants [12,14]. For example; chorioamnionitis associated to the cerebral palsy as its one of the major risk factors, only about 10% cases of cerebral palsy have been linked to intrapartum-related events, the majority of the cases thought to be related to events earlier on in the pregnancy [14].

Conclusion

There was a significant positive correlation between histological indices of Placentae there were not any correlations between histological variables and gross morphometric of umbilical cord variables.

According to my knowledge no similar study has been done in the Sudan before probably that the results may help in reducing the mortality and morbidity of newborns.

Bibliography

1. Khong TY and Gordijn SJ. "Quality of placental pathology reports". *Pediatric and Developmental Pathology* 6 (2003): 54-58.
2. Sun CC., et al. "Discrepancy in pathologic diagnosis of placental lesions". *Archives of Pathology and Laboratory Medicine* 126 (2002): 706-709.
3. Khong TY. "Evidence-based pathology: umbilical cord coiling". *Pathology* 42 (2010): 618-622.

4. Sebire NJ. "Pathophysiological significance of abnormal umbilical cord coiling index". *Ultrasound in Obstetrics and Gynecology* 30 (2007): 804-806.
5. De Laat MW., et al. "Prenatal ultrasonographic prediction of the umbilical coiling index at birth and adverse pregnancy outcome". *Ultrasound in Obstetrics and Gynecology* 28 (2006): 704-709.
6. Strong TH Jr., et al. "Antepartum diagnosis of noncoiled umbilical cords". *American Journal of Obstetrics and Gynecology* 170 (1994): 1729-1731, Discussion, 1731-1733.
7. Becroft DM., et al. "Placental villitis of unknown origin: epidemiologic associations". *American Journal of Obstetrics and Gynecology* 192 (2005): 264-271.
8. Russell P., et al. "Recurrent reproductive failure due to severe placental villitis of unknown etiology". *Journal of Reproductive Medicine* 24 (1980): 93-98.
9. Redline RW., et al. "Patterns of placental injury. Correlations with gestational age, placental weight, and clinical diagnoses". *Archives of Pathology and Laboratory Medicine* 118 (1994): 698-701.
10. Oliveira LH., et al. "Changes in placental morphology of small for gestational age newborns". *Journal of Pediatrics (Rio J)* 78 (2002): 397-402.
11. Salafia CM., et al. "Relationship between placental histologic features and umbilical cord blood gases in preterm gestations". *American Journal of Obstetrics and Gynecology* 173 (1995): 1058-1064.

12. Redline RW and O'riordan MA. "Placental lesions associated with cerebral palsy and neurologic impairment following term birth". *Archives of Pathology and Laboratory Medicine* 124 (2000): 1785-1791.
13. Offredy M and Vickers P. "Developing a Healthcare Research Proposal 2010 (1st ed.)". Oxford: Wiley-Blackwell 131.
14. Redline RW. "Severe fetal placental vascular lesions in term infants with neurologic impairment". *American Journal of Obstetrics and Gynecology* 192.2 (2005): 452-457.