

# INTESTINAL ANASTOMOSIS

Neil J. Mortensen, MD, FRCS, and Shazad Ashraf, DPhil, FRCS

The creation of a join between two bowel ends is an operative procedure that is of central importance in the practice of a general surgeon [see *Sidebar* Intestinal Anastomosis: Historical Perspective]. Leakage from an intestinal anastomosis can be disastrous. However, with proper appreciation of certain principles, there is little difference in the outcomes of operations performed by trainees and established surgeons.<sup>1</sup> To minimize the risk of potential complications, it is imperative to adhere to several well-established principles [see *Table 1*]. The main ones relate to the creation of a tension-free join with good apposition of the bowel edges in the presence of an excellent blood supply.<sup>2</sup> The importance of surgical technique is exemplified by the large range of anastomotic leak rates between surgeons.<sup>3</sup>

The frequency of anastomotic leakage ranges from 1 to 24%.<sup>4-6</sup> The rate of leakage is higher after elective rectal anastomoses when compared with colonic anastomoses (12 to 19% versus 11%, respectively).<sup>7-9</sup> The consequences of postoperative dehiscence are dire [see *Table 2*]. A threefold rise in mortality was seen (from 7 to 22%) in the St. Mary's Large Bowel Cancer Project, when anastomotic leakage occurred.<sup>7</sup> Moreover, there is an accompanying significant increase in hospital stay, and, distressingly, a number of patients never have their stomas reversed.<sup>4</sup>

This review is divided into three broad sections. First, factors that influence intestinal anastomotic healing are discussed. The different technical options for creating anastomoses are then analyzed. The final section concentrates on the operative techniques that are currently used in constructing anastomoses.

## Intestinal Healing

The process of intestinal anastomotic healing mimics that of wound healing elsewhere in the body in that it can be arbitrarily divided into an acute inflammatory (lag) phase, a proliferative phase, and, finally, a remodeling or maturation phase [see *Figure 1*]. Collagen is the single most important molecule for determining intestinal wall strength, which makes its metabolism of particular interest for understanding anastomotic healing. During the proliferative stage, fibroblasts become the predominant cell type, playing an important role in laying down collagen in the extracellular space. At the epithelial level, the crypts undergo division to cover the defect on the luminal surface of the bowel. The density of collagen synthesis is in a constant state of dynamic equilibrium, which is dependent on the balance between rates of synthesis and collagenolysis. After surgery, degradation of mature collagen begins in the first 24 hours and predominates for the first 4 days. This is caused by the upregulation of matrix metalloproteinases (MMPs), which are an important class of enzymes involved in collagen metabolism, which include collagenase (MMP-1).<sup>10</sup> This

family includes 20 zinc-dependent endopeptidases.<sup>10</sup> In vivo use of MMP inhibitors has been found to increase the strength of intestinal anastomoses by up to 48% at postoperative day 3, which suggests that these enzymes may be important in determining the risk of leakage.<sup>11</sup> Sepsis is thought to increase the level of transcription and activity of this enzyme, which may potentially lead to problems in the early postoperative period. In an animal model where bacterial peritonitis was induced, increased levels of MMP were seen on the third postoperative day, which coincided with a fall in the bursting pressure.<sup>10</sup> However, no increase in anastomotic dehiscence was found over the control group. Seven days after surgery, collagen synthesis becomes the dominant force, particularly proximal to the anastomosis. After 5 to 6 weeks, there is no significant increase in the amount of collagen in a healing wound or anastomosis, although turnover and thus synthesis are extensive. The strength of the scar continues to increase for many months after injury.

Cross-linking between collagen fibers and their orientation are the major factors that determine the tensile strength of tissues. The term *bursting pressure* of anastomoses is used as a quantitative measure to grade the strength of an anastomosis in vivo. This pressure has been found to increase rapidly in the early postoperative period, reaching 60% of the strength of the surrounding bowel by 3 to 4 days and 100% by 1 week.<sup>12,13</sup> The submucosal layer is, in fact, where the tensile strength of the bowel lies due to its high content of collagen fibers. Therefore, in constructing a hand-sewn intestinal anastomosis, it is imperative that this layer is included when taking extramucosal bites. Collagen synthetic capacity is relatively uniform throughout the large bowel but less so in the small intestine: synthesis is significantly higher in the proximal and distal small intestine than in the midjejunum. Overall collagen synthetic capacity is somewhat less in the small intestine. Although no significant difference has been found between the strength of ileal anastomoses and that of colonic anastomoses at 4 days, colonic collagen formation is much greater in the first 48 hours.<sup>14</sup> It is noteworthy that the synthetic response is not restricted to the anastomotic site but appears to be generalized to a significant extent.<sup>15</sup> The presence of the visceral peritoneum on the bowel wall also has an influence on the ease with which two bowel ends can be joined. This is highlighted by the increased technical difficulty of joining extraperitoneal bowel ends, for example, the thoracic esophagus and the rectum [see *Figure 2*].

## SYSTEMIC FACTORS

Dehiscence has been linked adversely with increasing age.<sup>16,17</sup> This may be secondary to a number of factors, which include the presence of comorbid diseases, malnutrition, or vitamin deficiency [see *Table 3*]. An in vivo model of severe protein malnutrition, which can occur in advanced cancer,

## Intestinal Anastomosis: Historical Perspective

Intestinal anastomosis has a long history. Hippocrates is known to have referred to intestinal suturing as early as 460 BC, and Celsus is reported to have written about using the glover's stitch to suture colonic perforations and close intestinal fistulae between 30 BC and 30 AD.<sup>85</sup> In the second century, Galen, probably the most influential physician of the time, took a different view, opposing intestinal anastomosis because of the significant risks of stricture and subsequent obstruction. Unfortunately, this view prevailed throughout most of Europe during the Dark Ages. Toward the end of the first millennium, Abulkasim of the Muslim school was experimenting with the so-called ant closure, in which the pincers of ants were allowed to grasp the two intestinal edges to be joined and bring the edges together; the bodies of the ants were then pinched off, and the subsequent spasm of the pincers kept the edges apposed. This closure is considered by many to be the forerunner of the Michel clip, which was developed later in France. Abulkasim also experimented with the glover's stitch for closing enterotomies using sheep-gut filaments as sutures.

In the 11th century, the School of Salerno was founded by the so-called Four Masters. These physicians reviewed the principles of Hippocrates and Celsus regarding closure of intestinal injuries, maintenance of aseptic technique, and wound closure. They devised a method of closure that made use of a variety of stents to prevent the stricture so feared by Galen. These stents were made of a number of different materials, including elder wood and goose trachea. The Four Masters were also the first to use interrupted sutures as opposed to the glover's stitch. This new practice reduced the incidence of stricture further and, coupled with the use of stents, caused less narrowing of the intestinal lumen. The sutures themselves were not tied; in fact, they were brought out through the skin to be removed once healing had been achieved.

The Four Masters greatly influenced a contemporary group of Benedictine monks, who used dried animal intestine as the stent of choice along with removable sutures. The Four Monks closure, as it became known, was practiced throughout many parts of Europe for nearly a century. In the 12th century, however, papal ordinances forbade members of the clergy to perform surgical procedures on the grounds that doing so distracted them from ministering to the souls of their flocks. As a result, the somewhat less well-educated barbers became the practitioners of surgery. This development was accompanied by a return to Galenic principles, including the use of the running glover's stitch. The high incidence of leakage and obstruction that resulted soon led the barbers to abandon intestinal procedures, except for repair of partial transverse or colonic wounds. Attempts were made to close bowel injuries and to approximate the repaired area to the abdominal wall or to other organs with the goal of imitating natural adhesion formation. In the 1700s, Palfyn and Peyronie brought the closed intestinal injury out into the wound so that if primary healing failed to occur, an enterocutaneous fistula would develop; this was the first description of a rudimentary stoma. Verduc and von de Wyl carried this principle to its logical conclusion and developed the so-called artificial anus for use in cases of complete transection. In 1730, Ramdohr intussuscepted one segment of bowel into another, fixing it in place with a single transfixing suture. The resultant mucosa-to-serosa coaptation healed poorly and exhibited a high leakage rate.

Stoma formation and stenting with removable sutures followed by approximation to the abdominal wound remained the standards of care until as recently as the 19th century, when Larrey first described his attempts at a two-layer anastomosis. These attempts were followed closely by Travers's description in 1812 of an agglutination substance that was necessary to approximate the wounded intestinal edges. Meanwhile, Bell was experimenting with the baseball stitch and a tallow plug stent that was ultimately melted by body heat, and Lembert at the Hopital de la Charite, Paris, was describing the use of interrupted inverting sutures to obtain serosa-to-serosa apposition. Lembert used fine-caliber silk sutures that incorporated all layers except the mucosa and were left in situ. An interesting historical note is that another French surgeon, Jobert, had described a full-thickness interrupted inverting stitch for intestinal anastomoses 2 years earlier, but he was not nearly as vocal a proponent of his approach as Lembert was of his. Many other surgeons were experimenting with different methods of closure throughout the 19th century. For example, Henroz described a self-securing system of metallic rings that was the precursor of the modern Murphy button or Valtrac system, and Wolfer described a secure two-layer interrupted method of anastomosis.

demonstrated a reduction in tissue collagen and bursting pressure of colonic anastomoses.<sup>18</sup> However, the introduction of parenteral nutrition has not been shown to have any benefit in aiding anastomotic healing.<sup>18</sup> Several factors, such as vitamin C deficiency, zinc deficiency, jaundice, and uremia, which are known to inhibit collagen synthesis, have a detrimental effect on tissue healing.<sup>16</sup> A critical stage in collagen formation is the hydroxylation of proline to produce hydroxyproline; this process is believed to be important for maintaining the three-dimensional triple-helix conformation of mature collagen, which gives the molecule its structural

strength. The amount of collagen found in a tissue is indirectly determined by measuring the amount of hydroxyproline, although no significant statistical correlation between hydroxyproline content and objective measurements of anastomotic strength has ever been demonstrated.<sup>19</sup> Vitamin C deficiency results in impaired hydroxylation of proline and the accumulation of proline-rich, hydroxyproline-poor molecules in intracellular vacuoles.

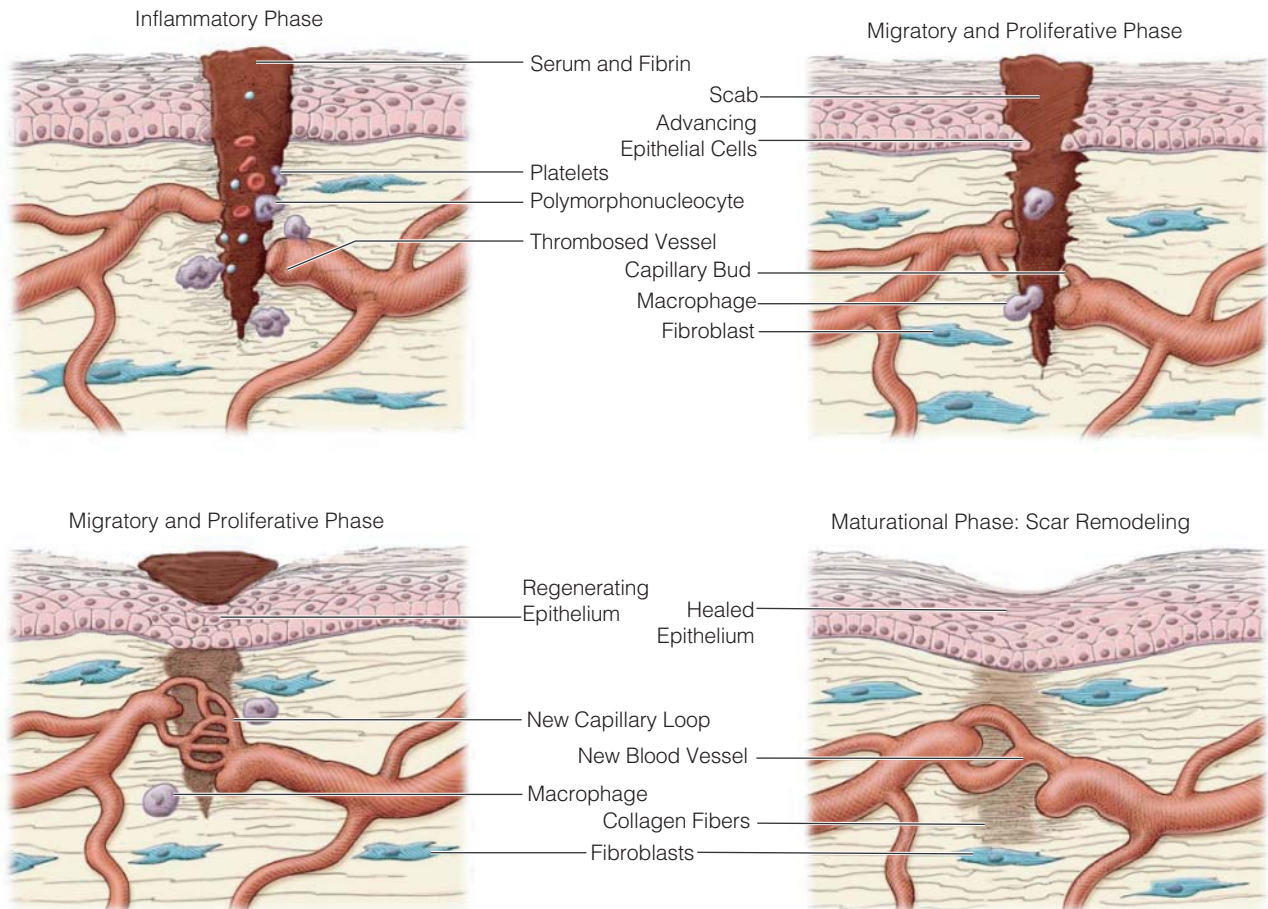
In high doses, corticosteroids have been associated with poor healing. However, at therapeutic doses, no difference in leak rates was found between controls and those treated with steroids.<sup>17</sup>

**Table 1 Principles of Successful Intestinal Anastomosis**

Well-nourished patient with no systemic illness
No fecal contamination, either within gut or in surrounding peritoneal cavity
Adequate exposure and access
Well-vascularized tissues
Absence of tension at anastomosis
Meticulous technique

**Table 2 Consequences of Postoperative Dehiscence**

Peritonitis
Septicemia
Further surgery
Creation of a defunctioning stoma
Death



**Figure 1** The phases of wound healing. In the inflammatory phase (*top, left*), platelets adhere to collagen exposed by damage to blood vessels to form a plug. The intrinsic and extrinsic pathways of the coagulation cascade generate fibrin, which combines with platelets to form a clot in the injured area. Initial local vasoconstriction is followed by vasodilatation mediated by histamine, prostaglandins, serotonin, and kinins. Neutrophils are the predominant inflammatory cells (a polymorphonucleocyte is shown here). In the migratory and proliferative phase (*top, right; bottom, left*), fibrin and fibronectin are the primary components of the provisional extracellular matrix. Macrophages, fibroblasts, and other mesenchymal cells migrate into the wound area. Gradually, macrophages replace neutrophils as the predominant inflammatory cells. Angiogenic factors induce the development of new blood vessels as capillaries. Epithelial cells advance across the wound bed. Wound tensile strength increases as collagen produced by fibroblasts replaces fibrin. Myofibroblasts induce wound contraction. In the maturational phase (*bottom, right*), scar remodeling occurs. The overall level of collagen in the wound plateaus; old collagen is broken down as new collagen is produced. The number of cross-links between collagen molecules increases, and the new collagen fibers are aligned so as to yield an increase in wound tensile strength.

#### LOCAL FACTORS

Blood flow is critical for healing. The increased vascularity of the bowel wall is the reason why gastric and small bowel anastomoses heal more rapidly in comparison with those involving the esophagus and large bowel. In preparation of the bowel ends for anastomosis, it is imperative that mesentery is handled carefully and not dissected too far from the bowel edge. Mesenteric compromise, secondary to overenthusiastic dissection or inappropriate suture, may result in a reduction of perianastomotic blood flow. Tension at the anastomosis is also critical, and this is prevented by appropriate mobilization of the splenic flexure. Other factors that influence blood flow at the site of anastomoses include hypovolemia and blood viscosity.<sup>20</sup> Radiation may damage the microcirculation, which predisposes to poor healing.<sup>17</sup>

#### Technical Options for Fashioning Anastomoses

A number of materials have been used in the past 160 years to join one bowel end to another. These have included substances such as catgut and stainless steel. The newer generation of materials includes monofilaments and absorbable sutures. More recent technological advances have led to the introduction of stapling devices over the last three decades, which have been embraced enthusiastically by the surgical community. The main attraction lies in their ability to create a robust anastomosis in a relatively short space of time. In the depths of the pelvis, this is particularly advantageous. The main drawback, as for any technologically advanced device, is the cost and risk of mechanical failure. However, more importantly, there continues to be a controversy regarding whether stapling anastomoses lead to better clinical

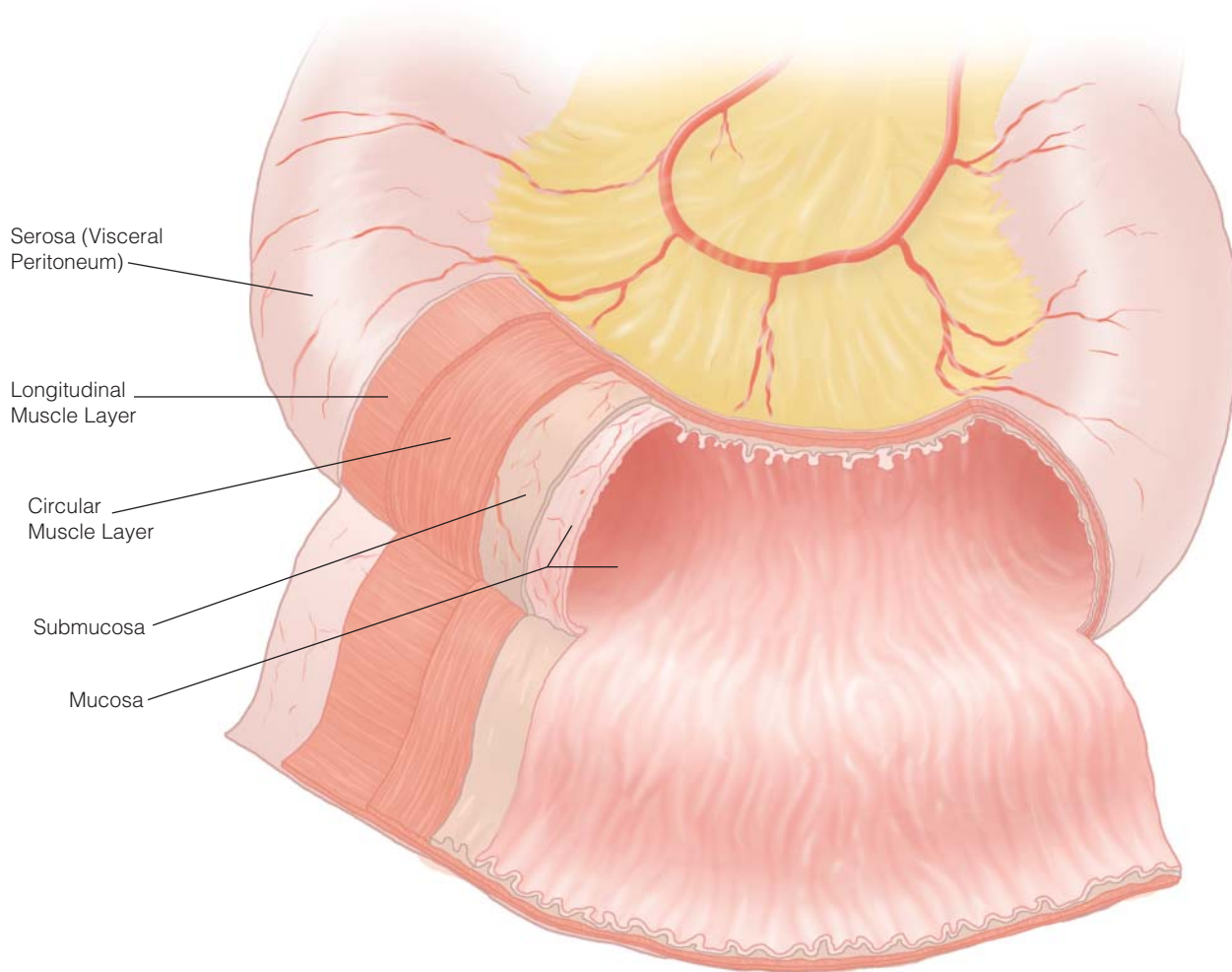


Figure 2 The tissue layers of the jejunum. Most of the bowel wall's strength is provided by the submucosa.

outcome over hand-suturing.<sup>21</sup> The following sections discuss the relative merits of hand versus mechanical anastomosis.

#### SUTURING: TECHNICAL ISSUES

##### *Choice of Suture Material*

Apart from inert substances, most foreign materials will evoke an inflammatory reaction in the human body. Surgical sutures are no exception. Studies have looked at the relative ability of different suture materials to elicit such a reaction. It has been found that silk has a potent ability to

cause a cellular infiltrate at the site of the anastomosis that persists up to 6 weeks after implantation.<sup>22</sup> Substances such as polypropylene (Prolene), catgut, and polyglycolic acid (Dexon) evoked a milder response.<sup>22,23</sup> There is little difference between absorbable and nonabsorbable sutures and the strength of the anastomosis.

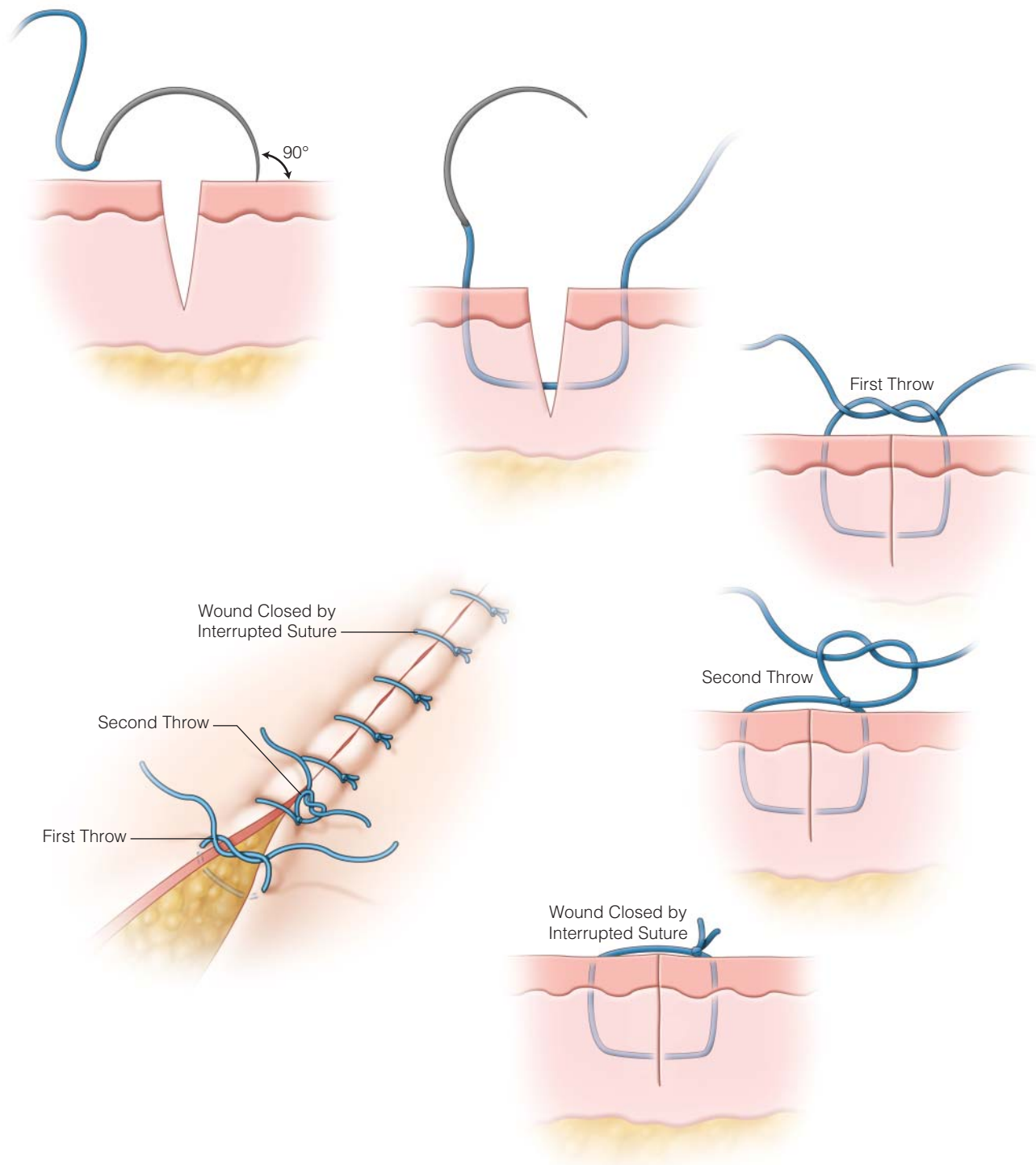
The ideal suture material is one that is able to elicit little or no inflammation while maintaining the strength of the anastomosis during the lag phase of healing. This has yet to be discovered, but the newer generation of sutures, which include monofilament and coated braided sutures, represent an advance beyond silk and other multifilament materials.

##### *Continuous versus Interrupted Sutures*

Both interrupted [see Figure 3] and continuous sutures [see Figure 4] are commonly used in fashioning intestinal anastomoses [see Figure 5]. Retrospective reviews have not revealed any advantage of interrupted sutures over continuous sutures in a single-layer anastomosis.<sup>24–26</sup> Oxygen tension and blood flow, as discussed previously, are critical factors involved in anastomotic healing. Animal studies have indicated that para-anastomotic tissue oxygen tension is

**Table 3 Factors Linked with Dehiscence**

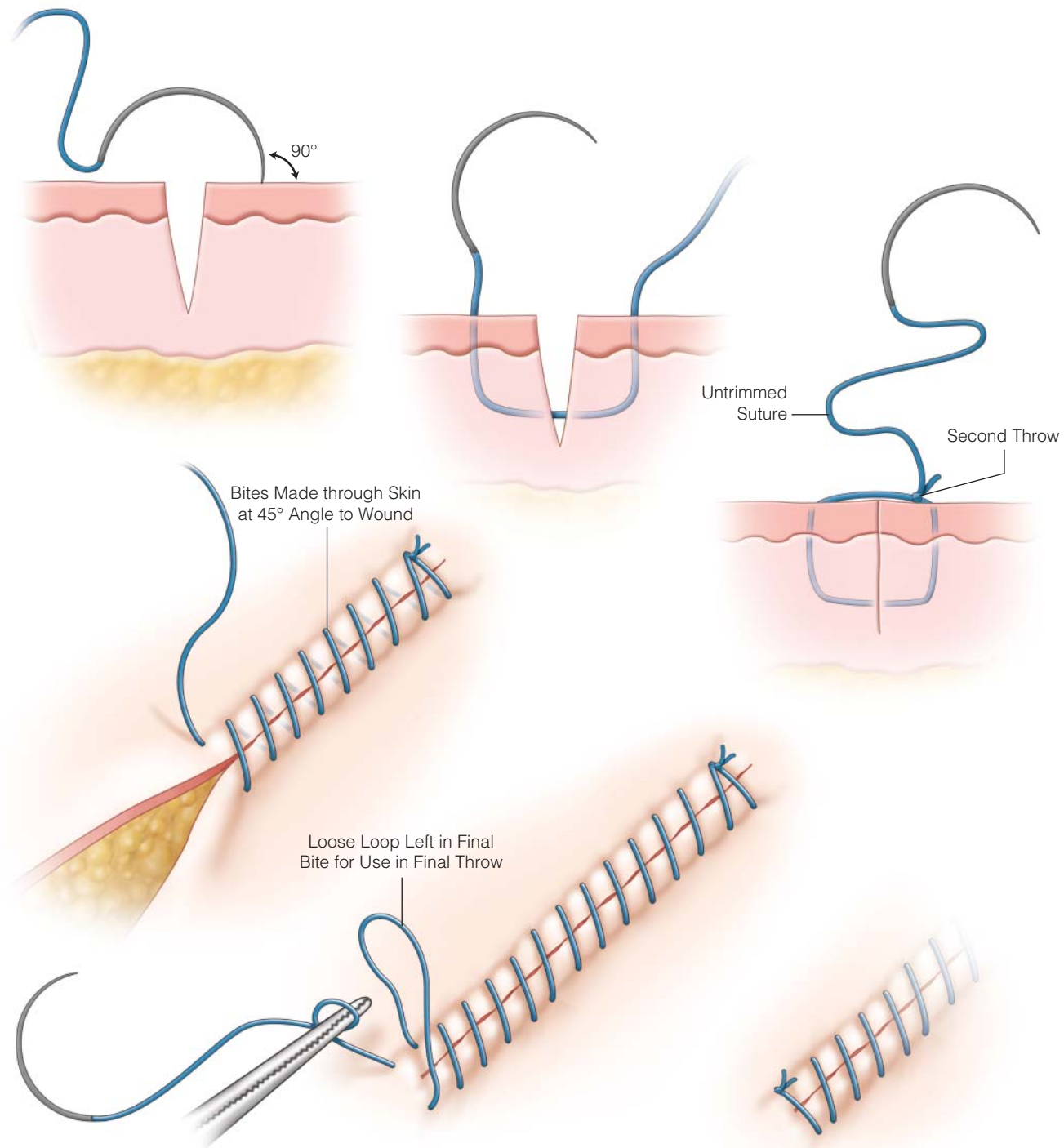
Increasing age
Presence of comorbid diseases
Malnutrition
Vitamin deficiency
Diabetes
Obesity
Poor knotting
Trauma to the wound after surgery



**Figure 3** A simple interrupted suture technique is useful for easy closure of traumatic and surgical wounds. Begin by entering the skin with the needle at a 90° angle to the skin. Full-thickness tissue bites encompass the epidermis and dermis. The first throw of the knot is a surgeon's knot, and all subsequent knots should lie squarely on the previous knot. The sutures should be spaced close enough to coapt the tissues but not cause ischemia.

significantly less with continuous sutures than with interrupted sutures.<sup>27</sup> This finding was correlated with an increased anastomotic complication rate and impaired collagen synthesis and healing with continuous sutures in a rat model.<sup>28</sup> A prospective randomized trial compared the

continuous single-layer technique for intestinal anastomosis (in small bowel and colon) with the two-layer interrupted technique. No significant difference was seen in the leak rate (3.1% [2 of 65] and 1.5% [1 of 67], respectively). The added advantages of reduced operating times and cost were

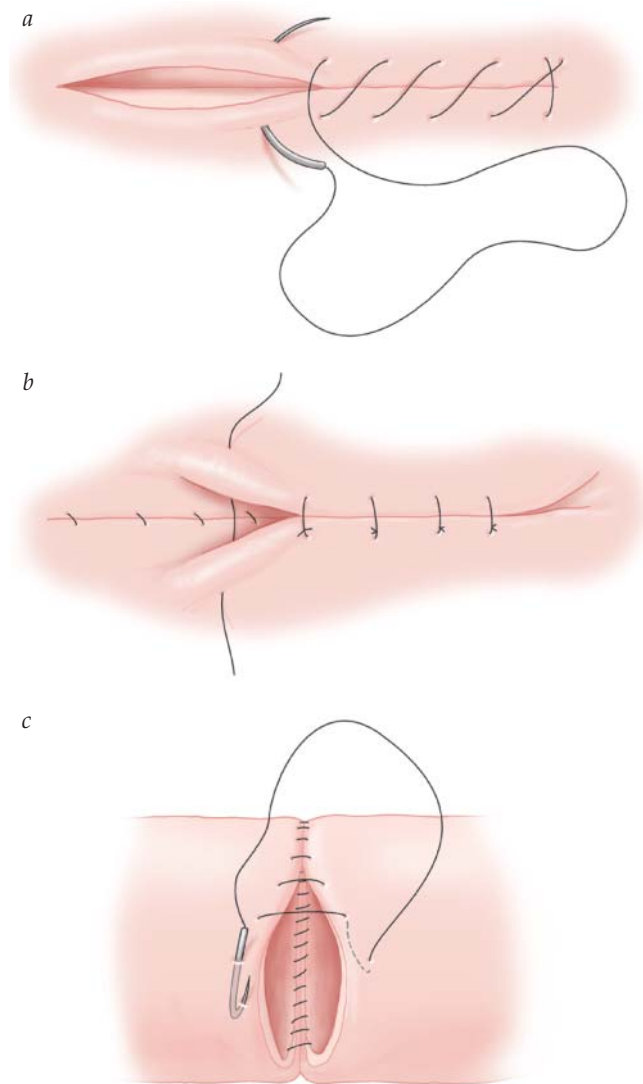


**Figure 4** A simple continuous suture technique is a faster alternative to the interrupted suture technique described in Figure 3 [see Figure 3]. The first bite is secured with knots, and the remaining bites continue in a repetitive fashion at equal distances, close enough to coapt tissues without inducing ischemia. In the final bite of tissue, a loose loop is left to use as one of the suture ends for the final knot to secure the suture.

observed. A case series review of single-layer continuous sutures for anastomoses demonstrated fistula rates from 0 to 6.8% (total number 3,027 patients in the series, with a mean fistula rate of 1.7%), which demonstrates that this suture technique can be safely performed.<sup>29</sup>

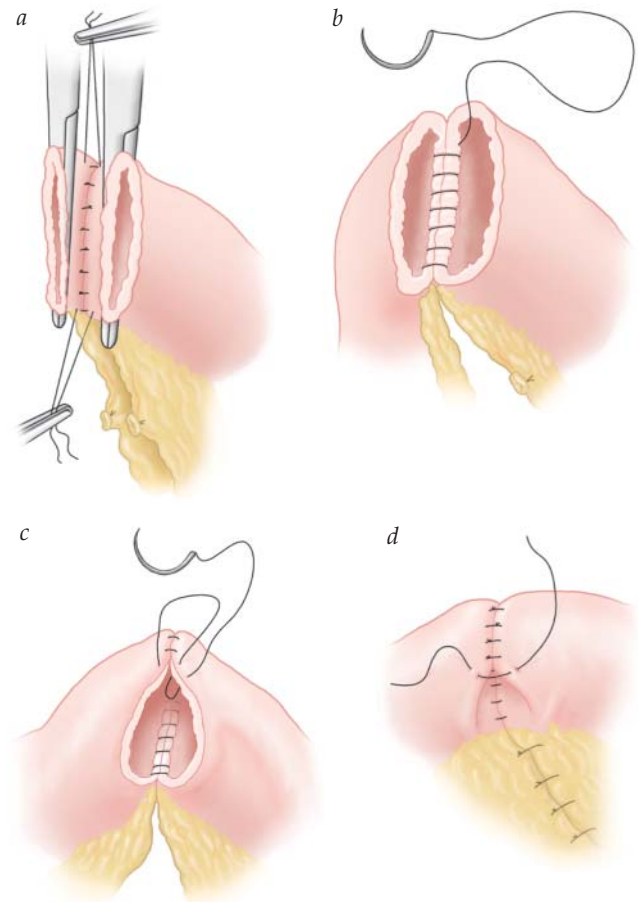
#### *Single-Layer versus Double-Layer Anastomoses*

The technique of double-layer anastomosis has been used traditionally for more than 100 years. This originated from work done by Travers and Lembert.<sup>29</sup> A double anastomosis consists of an inner layer of continuous or interrupted



**Figure 5** Stitches commonly used in fashioning intestinal anastomoses: (a) the continuous over-and-over suture, (b) the interrupted Lembert suture, and (c) the Connell suture.

absorbable suture and outer layer of interrupted absorbable or nonabsorbable suture [see Figure 6]. The technique of single-layer anastomosis was championed because of potential advantages such as reduced operating times and cost. However, the main issue to consider is safety. A randomized trial comparing the single and double techniques for anastomosis found no evidence that there was an increased risk of leak.<sup>29</sup> However, the sample size (65 versus 67) was too small to detect a significant difference; the authors stated that a multicenter trial with 1,500 patients would be required to address this. Furthermore, a recently published meta-analysis studied this problem and analyzed six trials with data from 670 patients (299 in the single-layer group, 371 in the double-layer group). They concluded that there was no evidence that the creation of two-layer anastomoses reduced the rate of postoperative leaks when compared with single-layer anastomoses.<sup>30</sup> However, adding a second layer runs the risk of narrowing the anastomoses, resulting in a mechanical holdup.



**Figure 6** Double-layer end-to-end anastomosis. (a) Interrupted Lembert stitches are used to form the posterior outer layer. (b) A full-thickness continuous over-and-over stitch is used to form the posterior inner layer. (c) A Connell stitch is used to form the anterior inner layer. (d) Interrupted Lembert stitches are used to form the anterior outer layer.

#### STAPLING: TECHNICAL ISSUES

##### *Choice of Stapler*

Hüttl first introduced surgical stapling devices in 1908; however, they did not gain popularity at that time and for some time afterward because the early instruments were cumbersome and unreliable. The development of reliable, disposable instruments over the past 25 years has changed surgical practice dramatically. With modern devices, technical failures are rare, the staple lines are of more consistent quality, and anastomoses in difficult locations are easier to construct. Three different types of stapler are commonly used for fashioning intestinal anastomoses. The transverse anastomosis (TA) stapler is the simplest of these. This device places two staggered rows of B-shaped staples across the bowel but does not cut it: the bowel must then be divided in a separate step. The gastrointestinal anastomosis (GIA) stapler places two double staggered rows of staples and simultaneously cuts between the double rows. The circular, or end-to-end anastomosis (EEA), stapler places a double row of staples in a circle and then cuts out the tissue within

the circle of staples with a built-in cylindrical knife. All of these staplers are available in a range of lengths or diameters. Staplers may be used to create functional or true anatomic EEAs as well as side-to-side anastomoses. The original staplers were all designed for use in open procedures, but now a number of instruments (mostly of the GIA type) are available for use in laparoscopic procedures. The staples themselves are all made of titanium, which causes little tissue reaction. They are not magnetic and do not cause subsequent difficulties with magnetic resonance imaging (MRI).

In a functional EEA, two cut ends of bowel (either open or stapled closed) are placed side by side with their blind ends beside each other. If the bowel ends are closed, an enterotomy must be made in each loop of bowel to allow insertion of the stapler. A cutting linear (GIA) stapler is then used to fuse the two bowel walls into a single septum with two double staggered rows of staples and to create a lumen between the two bowel segments by dividing this septum between the rows. A noncutting linear (TA) stapler is then used to close the defect at the apex of the anastomosis where the GIA stapler was inserted. An alternative, and cheaper, method of closing the defect is to use a continuous suture. The cut and stapled edges of the bowel should be inspected for adequacy of hemostasis before the apex is closed. Some authors suggest cauterizing these edges to ensure hemostasis<sup>31</sup>; however, given that electric current may be conducted along the metallic staple line to the rest of the bowel, it is probably easier and safer simply to underpin bleeding vessels with a fine absorbable suture. It is also important to offset the two inverted staple lines before closing the apex.<sup>32</sup> True anatomic end-to-end stapled anastomoses may be fashioned with a linear stapler by triangulating the two cut ends and then firing the stapler three times in intersecting vectors to achieve complete closure [see Figure 7]. The potential drawback of this approach is that the staple lines are all everted. It is often easier to join two cut ends of bowel with an EEA stapler, which creates a directly apposed, inverted, stapled EEA. However, circular staplers can be more difficult to use at times because of the need to invert a complete circle of full-thickness bowel wall. In addition—at least at locations other than the anus—they typically require closure of an adjacent enterotomy.

#### *Staple Height*

TA and GIA staplers are available with a variety of inserts containing several different types of staples. These inserts vary with respect to the width, the height (or depth) of the closed staple, and the distance between the staples in the rows. They are designed for use in specific tissues, and it is important to choose the correct stapler insert for a given application. In particular, inserts designed for closing blood vessels should not be used on the bowel, and vice versa. With TA and EEA staplers, it is possible to vary the depth of the closed staples by altering the distance between the staples and the anvil as the instrument is closed. The safe range of closure is usually indicated by a colored or shaded area on the shaft of the instrument. Thus, if full closure would cause excessive crushing of the intervening tissues, the stapler need not be closed to its maximum extent. A 1987 comparison of anastomotic techniques that used blood flow to the divided tissues as a measure of outcome found that

the best blood flow to the healing site was provided by stapled anastomoses in which the staple height was adjusted to the thickness of the bowel wall [see Table 4].<sup>33</sup>

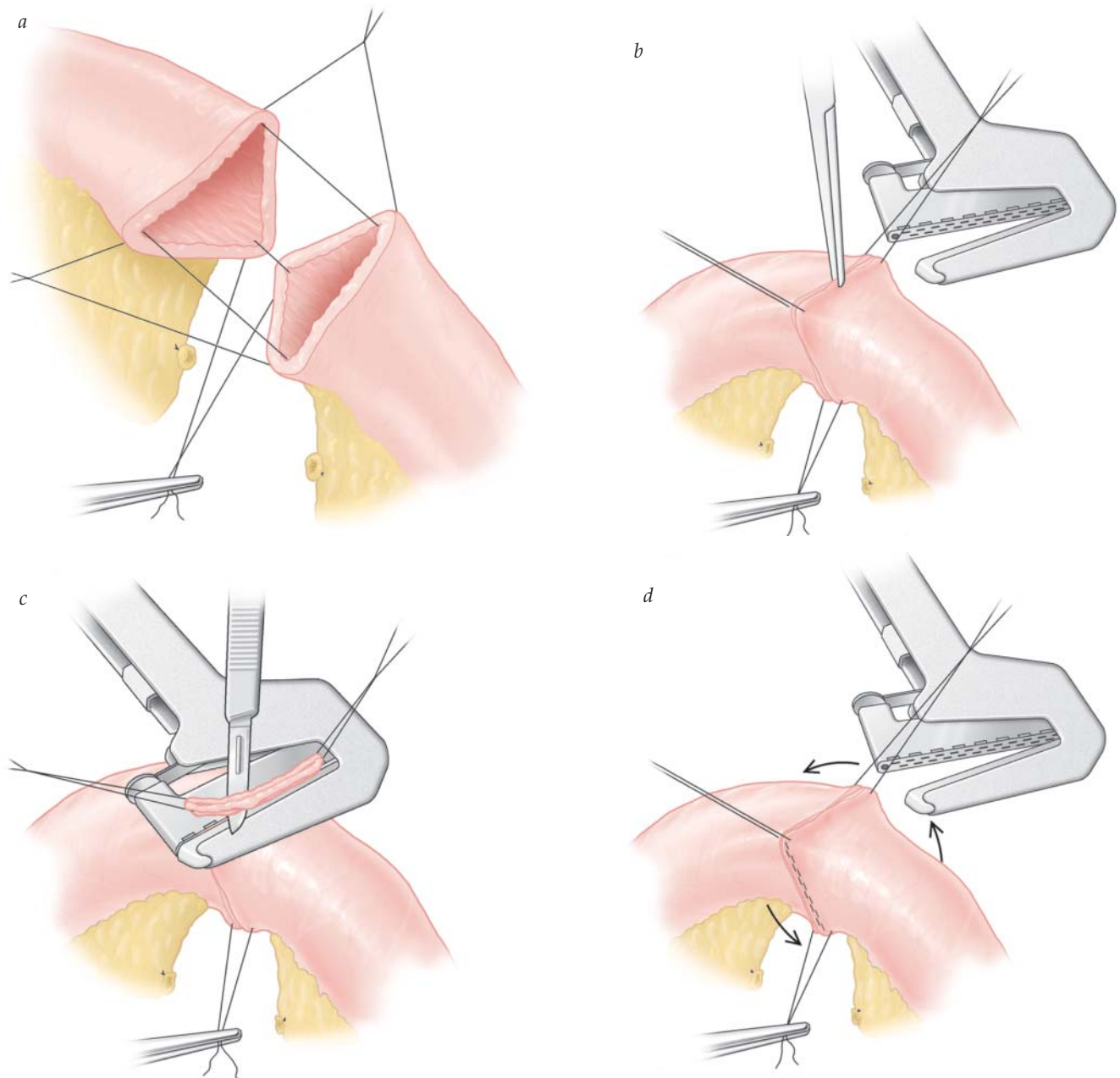
#### *Single-Stapled versus Double-Stapled Anastomoses*

To accomplish many of these anastomoses, intersecting staple lines are created. Initially, some concern was expressed about the security of these areas and about the ability of the blade in the cutting staplers to divide a double staggered row of staples. Animal studies, however, demonstrated that even though nearly all (> 90%) of the staple lines that were subsequently transected by a second staple line contained bent or cut staples, the integrity of the anastomosis was not compromised in any way, nor was healing adversely affected.<sup>34,35</sup>

#### HAND-SEWN VERSUS STAPLED ANASTOMOSES

Titanium staples are ideal for tissue apposition at anastomotic sites because they provoke only a minimal inflammatory response and provide immediate strength to the cut surfaces during the weakest phase of healing. Initially, tissue eversion at the stapled anastomosis was a major concern given that everted hand-sewn anastomoses had previously been shown to be inferior to inverted ones; however, the greater support and improved blood supply to the healing tissues associated with stapling tend to counteract the negative effects of eversion. In fact, one study found that bursting strength for canine colonic EEAs was six times greater when the procedure was performed with an EEA stapler than when it was done with interrupted Dacron sutures.<sup>36</sup> In 1993, a randomized multicenter trial studied 440 patients who underwent either hand-sutured or stapled ileocolic resection for cancer.<sup>37</sup> Patients were assessed both clinically and by imaging for the presence of a leak, which consisted of a contrast enema at about 10 days after the operation. The overall leak rate in the hand-sutured group was found to be 8.3%, which compared unfavorably with the stapled group (leak rate 2.8%). A possible explanation for the higher rate in the former group was the possibility of surgical inexperience with the variety of suture techniques used in the study (end to end and end to side with either continuous or interrupted sutures). Docherty and colleagues, on behalf of the West of Scotland and Highland Anastomosis Study Group, published data from 732 patients from five centers.<sup>38</sup> Radiologically proven leaks were significantly higher in the sutured group (14.4% versus 5.2%). However, no difference was seen for clinical leaks, morbidity, or postoperative mortality. Two meta-analyses have been published comparing the hand and stapled techniques of intestinal anastomoses. MacRae and McLeod studied 13 trials published from 1980 to 1995.<sup>39</sup> For colorectal anastomoses, no significant difference was seen for outcomes such as mortality (odds ratio < 1 favoring stapled anastomoses), total leak rate, clinical leak rate, radiologic leak rate, tumor recurrence, or wound sepsis. Interestingly, strictures and technical problems were higher in the stapled group [see Table 5]. A more recent meta-analysis (2007), which reviewed data from patients with ileocolic anastomoses, demonstrated that there was a significant reduction in the overall leak rate and the clinical leak rate in the 955 patients (825 cases of cancer and 120 cases of Crohn disease).<sup>40</sup>





**Figure 7** (a) The bowel ends are triangulated with three traction sutures. (b) A noncutting linear stapler (transverse anastomosis) is placed between two of the sutures. (c) The stapler is closed, and the excess tissue is excised. (d) The bowel is rotated, and steps b and c are repeated twice more to close the remaining two sides of the triangle.

Even when the anastomosis had to heal under adverse conditions (e.g., carcinomatosis, malnutrition, previous chemotherapy or radiation therapy, bowel obstruction, anemia, or leukopenia), no significant differences were apparent

#### Table 4 Anastomotic Techniques Ranked by Best Blood Flow to the Healing Site<sup>33</sup>

1. Stapled anastomoses in which the staple height was adjusted to the thickness of the bowel wall
2. Double-layer stapled and sutured anastomoses
3. Double-layer sutured anastomoses
4. Tightly stapled anastomoses

between stapled and hand-sewn anastomoses. Stapling did, however, shorten operating time, especially for low pelvic anastomoses. Cancer recurrence rates at the site of the anastomosis have been reported to be higher or lower depending on the technique used. Certainly, suture materials engender a more pronounced cellular proliferative response than titanium staples do, particularly with full-thickness sutures as opposed to seromuscular ones, and malignant cells have been shown to adhere to suture materials.<sup>41,42</sup>

#### UNUSUAL TECHNIQUES

In 1892, Murphy introduced his button, which consisted of a two-part metal stud that was designed to hold the

**Table 5 Comparison of Hand and Stapled Techniques by MacRae and McLeod<sup>39</sup>**

Outcome	OR	95% CI
Mortality	1.27	0.55–2.93
Total leak rate	1.09	0.78–1.52
Clinical leak rate	0.79	0.47–1.34
Radiologic leak rate	1.4	0.74–1.76
Tumor recurrence	1.30	0.57–3.04
Wound sepsis	1.02	0.53–1.98
Strictures	3.12	1.28–7.56
Technical problems	14.97	4.56–49.14

bowel edges in apposition without suturing until adhesion had occurred.<sup>43</sup> Thereafter, the stud was voided via the rectum. Several modifications of this technique have been described since then, primarily focusing on the composition of the rings or stents. In particular, dissolvable polyglycolic acid systems have been developed. These so-called biofragmentable anastomotic rings leave a gap of 1.5, 2.0, or 2.5 mm between the bowel ends to prevent ischemia of the anastomotic line. The use of adhesive agents such as methyl-2-cyanoacrylate to approximate the divided ends of intestinal segments has been studied as well.<sup>44</sup> There was only a moderate inflammatory response at the wound, which persisted for 2 to 3 weeks. Leakage rates were high, however, and many technical problems remained (e.g., how to stabilize the bowel edges while they underwent adhesion). Fibrin glues have also been employed in this setting. Although these substances are not strong enough to hold two pieces of bowel in apposition, they have been used to coat a sutured bowel anastomosis in an effort to reduce the risk of anastomotic failure. So far, no controlled clinical trials have confirmed that this approach is worthwhile.

#### FACTORS CONTRIBUTING TO FAILURE OF ANASTOMOSES

##### *Type and Location of Anastomosis*

Since the introduction of stapling, there has been an increase in the number of extremely low anterior resections being performed routinely. The literature seems to suggest that rectal anastomoses are more prone to leakages when compared with more proximal joins.<sup>7–9</sup> A retrospective review of risk factors in patients undergoing rectal resection for cancer found that a low anastomosis, defined as being 5 cm or less from the anal verge, was associated with a 6.5-fold increased risk of leakage when compared with anastomoses that were more than 5 cm from the anal verge.<sup>45</sup> Factors that may contribute to this include inadequate splenic flexure mobilization or suboptimal vascularity of the colonic conduit and rectal stump.

Dehni and colleagues also showed that there was an increased leak rate in patients undergoing low colorectal anterior resection in the absence of a proximal stoma (the leak rate was 17%, which fell to 6% when a stoma was present).<sup>46</sup> The technique of total mesorectal excision (TME), which is now standard technique for rectal cancer operations, has

reduced local recurrence to 5% at 5 years.<sup>47</sup> However, the incidence of anastomotic leakage in patients undergoing TME for low anterior resection is higher in the absence of defunctioning stomas (25% versus 8%).<sup>48</sup> The Rectal Cancer Trial on Defunctioning Stoma (a randomized multicenter trial) studied the outcomes of a defunctioning stoma in low anterior resection.<sup>4</sup> A total of 234 patients were recruited. The overall leak rate was 19.2% (45 of 235), whereas the group that had a stoma had a leak rate of 10.3% versus 28.0% in those without (odds ratio = 3.4, 95% CI = 1.6 to 6.9,  $p < .001$ ) [see Table 6]. Therefore, it is safe practice to cover a low anterior resection with a defunctioning stoma. However, it is more likely that the formation of stomas reduces the septic complications that arise from anastomotic leakages rather than reducing the leakage rate.

##### *Patient Preparation*

Patients who present in the emergency setting are usually compromised in terms of hydration status. This may be secondary to sepsis, obstruction, or a combination of these. Prior to any surgical procedure, fluid optimization is necessary and may require the aid of intensivists. Prior to elective surgery, patients are assessed with regard to systemic diseases (cardiovascular, respiratory, and diabetes), and anemia is corrected. Adequate preoperative antibiotic prophylaxis has been shown to reduce the risk of postoperative infection in all types of bowel surgery and must be given at the start of the operation. Some patients require additional steroids perioperatively.

Mechanical bowel preparation (MBP) has been thought to be an essential component of colorectal surgery for over 100 years.<sup>49,50</sup> For elective operations on the colon, it was traditional up until 5 years ago to empty the bowel before surgery and, indeed, was recommended by the Association of Surgeons of Great Britain and Ireland (ASGBI) until relatively recently.<sup>51,52</sup> The evidence for this practice was based on observational studies that showed that the mechanical clearance of feces from the bowel was associated with decreased morbidity and mortality in colonic surgery.<sup>53</sup> There has, however, been a recent relaxation in the practice of using of MBP. Proponents of MBP list several advantages, including reduction in intraluminal bacterial load, prevention of potential anastomotic disruption by fecal pellets, and easier handling of bowel.<sup>54</sup>

A Swiss randomized clinical trial, published in 2005, studied the effect of MBP on patients undergoing left-sided colorectal resection with primary anastomosis.<sup>54</sup> This trial demonstrated that the anastomotic leak rate was lower for the group that did not receive MBP compared with the group that did. Furthermore, there was a decrease in the length of time in hospital and extra-abdominal morbidity,

**Table 6 Leak Rates from the Rectal Cancer Trial on Defunctioning Stoma<sup>4</sup>**

Group	Leak Rate (%)
With stoma	10.3
Without stoma	28.0
Overall	19.2

such as pneumonia and cardiac-related problems. This seemed to agree with the finding of a Cochrane review.<sup>52</sup> Two large randomized trials have been published comparing the outcome of patients with and without MBP (either polyethylene glycol or sodium phosphate).<sup>55,56</sup> Contant and colleagues recruited 1,431 patients undergoing elective colorectal surgery from 13 centers.<sup>55</sup> Randomization was to either MBP or not. Leakage was defined by the onset of significant symptoms and corroborated using imaging. The rate of leakage in the MBP group did not significantly differ from the non-MBP group (the difference was 0.6%; 95% CI = -1.7 to 2.9,  $p = .69$ ) [see Table 7]. Jung and colleagues looked at 1,343 patients from 21 centers, randomized to those who had MBP (686 patients) versus those who had no MBP (657 patients).<sup>56</sup> No significant difference was found in outcomes (such as cardiovascular problems, general infections, and surgical site infections) between the two groups. In another meta-analysis, data from 10 randomized trials conducted over the last 24 years found that the anastomotic leak rate and wound infections were significantly higher in the MBP group [see Table 8].<sup>57</sup> Possible explanations of these findings may relate to immune changes in the colonic mucosa, which may impede wound repair.<sup>57</sup> Such evidence has resulted in some surgical institutions, including our own, adopting a policy of fluid restriction and enemas rather than MBP prior to elective colorectal surgery.<sup>58</sup>

Enemas are given to those undergoing anterior resections to prevent the risk of fecal matter impeding the use of stapling guns. It is advisable for patients to stop eating solid food 24 hours before the operation. Many trials have confirmed the benefits of intravenous antibiotics over the perioperative period.<sup>59</sup> However, there is some evidence that suggests that there is an increased risk of *Clostridium difficile*-associated diarrhea with the use of cephalosporin, penicillin, and clindamycin exposure.<sup>60-62</sup> Prophylaxis of thromboembolism is mandatory in all patients scheduled to undergo intestinal anastomosis. There is very little evidence in the literature that demonstrates any direct effect on anastomotic leak rates. However, mesenteric venous thrombosis (MVT) accounts for a tenth of acute mesenteric ischemic events.<sup>63</sup> The extent of thromboses is variable, with the worst outcome being mesenteric infarction requiring urgent relaparotomy. An absence of adequate prophylaxis may increase the risk of MVT occurring postoperatively, especially in those with other risk factors, such as a hypercoagulable state, previous thromboses, and smoking.

#### Associated Diseases and Systemic Factors

Diseases and systemic factors associated with poor anastomotic healing are listed here [see Table 9]. Some of these factors can be corrected preoperatively. Malnourished patients benefit from nutritional support delivered enterally

**Table 7** Leak Rates from the Contant and Colleagues Mechanical Bowel Obstruction Trial<sup>55</sup>

Group	Leak Rate (%)
MBP	4.8
Non-MBP	5.4

MBP = mechanical bowel preparation.

**Table 8** Leak and Wound Infection Rates from Mechanical Bowel Obstruction Meta-Analyses<sup>57</sup>

Group	Leak Rate (odds ratio 1.99 [95% CI 1.23–3.23]) (%)	Wound Infection Rate (odds ratio 1.54 [95% CI 1.08–2.2]) (%)
MBP	5.1	2.6
Non-MBP	8.2	5.5

MBP = mechanical bowel preparation.

or parenterally before and after operation. Well-nourished patients appear not to derive similar benefits from such support.<sup>64</sup> Resections for Crohn disease appear to carry a significant risk of anastomotic dehiscence (12% in one prospective study) even when macroscopically normal margins are obtained.<sup>65</sup> With the lifetime risk of repeated resections, strictureplasty has therefore become an attractive alternative to resectional management of Crohn disease even in the presence of moderately long strictures, diseased tissue, or sites of previous anastomoses. This allows for preservation of a length of small intestine. The glucocorticoid response to injury may attenuate physiologic responses to other mediators whose combined effects could be deleterious to the organism.<sup>66</sup> In animal experiments, wound healing, as measured by bursting pressure of an ileal anastomosis 1 week after operation, was optimal at a plasma corticosterone level that maintained maximal nitrogen balance and corresponded to the mean corticosterone level of normal animals.<sup>67</sup> Both supranormal and subnormal cortisol levels resulted in significantly impaired wound healing, probably through different mechanisms. It is believed that slow protein turnover is responsible for delayed anastomotic healing in adrenalectomized animals, whereas negative nitrogen metabolic balance is responsible for increased protein breakdown and delayed healing in animals with excess glucocorticoid activity.<sup>67,68</sup>

Lifestyle factors have also been associated with an increased risk of leakage. A Danish prospective study of 333 consecutive patients undergoing colorectal resection was performed and lifestyle information was collected by way of a questionnaire.<sup>69</sup> The overall leak rate was 15.9% (53 of 333) with smoking and alcohol consumption exceeding 35 units a week, increasing the risk of anastomotic leakage [see Table 10].

#### CONTROVERSIAL ISSUES IN INTESTINAL ANASTOMOSIS

##### Inversion versus Eversion

The question of the importance of inversion (as described by Lembert in the early 1800s) versus eversion of the anastomotic line has long been a controversial one. It has been

**Table 9** Diseases and Systemic Factors Associated with Poor Anastomotic Healing

Anemia
Diabetes mellitus
Previous irradiation
Previous chemotherapy
Malnutrition with hypoalbuminemia
Vitamin deficiencies

**Table 10 Lifestyle-Associated Leakage Risks from a Danish Prospective Study<sup>69</sup>**

Lifestyle Factor	Relative Risk (%)	95% CI
Smoking	3.18	1.44–7.00
Alcohol consumption exceeding 35 units a week	7.18	1.2–43.01

argued that the traditional inverting methods ignore the basic principle of accurately opposing clean-cut tissues. In the late 19th century, Halsted proposed an interrupted extramucosal technique, which has since been assessed in retrospective<sup>1</sup> and prospective<sup>3</sup> reviews and found to have a low leakage rate (1.3 to 6.0%) in a wide variety of circumstances. A 1969 study reported greater anastomotic strength, less luminal narrowing, and less edema and inflammation with everted small intestinal anastomoses in dogs.<sup>70</sup> Subsequent laboratory and clinical studies have not confirmed these findings and, in fact, have often yielded the opposite results: lower bursting pressure, slower healing, and more severe inflammation have all been associated with an everted suture line.<sup>71–73</sup> A trial by Goligher and colleagues, however, showed conclusively the importance of inverting the cut edges of bowel in colorectal surgery.<sup>74</sup> In this study, the group that had everting suture anastomoses had a far higher rate of fecal fistula formation when compared with the group with inverting suture anastomoses (43% versus 8%).

#### *Nasogastric Decompression*

Routine nasogastric decompression in patients undergoing a procedure involving an intestinal anastomosis remains controversial. In retrospective<sup>75</sup> and prospective,<sup>76</sup> randomized, controlled trials, routine use of a nasogastric tube conferred no significant advantage in terms of reducing the risk of anastomotic leak. In fact, there was a trend toward an increased incidence of respiratory tract infections after routine gastric decompression.<sup>77</sup> Nonetheless, one study found that nearly 20% of patients required insertion of a gastric tube in the early postoperative period.<sup>76</sup> If the choice is made not to place a nasogastric tube routinely, it is important to remain alert to the potential for gastric dilatation, which can develop suddenly and without warning.

#### *Abdominal Drains*

Fecal contamination from bowel surgery is a dreaded complication. Peritoneal drainage is linked with a significant amount of controversy, with two basic schools of thought.<sup>78</sup> The first accepts the possibility that drains may help with diagnosis by serving as an early warning system for either anastomotic leakage or bleeding. Another advantage includes the evacuation of blood and serous fluid, thus reducing the risk of abscesses. Others are skeptical about the benefits. Concerns center around the fact that drains may irritate the peritoneum, thus increasing the production of serous fluid. Also, they may act as potential routes for peritoneal infection. There is a potential risk of physical impedance of movement of omentum and adjacent organs, which may hinder the innate ability to wall off any possible infection. Also, it is thought that drains are at a high risk for

blockage. Even before World War I, the old dictum “when in doubt, drain” was called into question by Yates, who wrote that the peritoneal cavity could not be effectively drained because of adhesions and rapid sealing of the drain tract.<sup>79</sup> Six decades later, one study showed a dramatic increase in the incidence of anastomotic dehiscence (from 15 to 55%) after the placement of para-anastomotic drains in dogs.<sup>80</sup> This increase was associated with a significant increase in mortality. A 1999 study of pelvic drainage after a rectal or anal anastomosis showed that prophylactic drainage did not improve outcome or reduce complications.<sup>81</sup> Yet another study reported the severe inflammatory reaction caused by drains at anastomoses.<sup>82</sup> Despite these findings, many surgeons elect to place an intra-abdominal drain in the pelvis after an anterior resection or a coloanal anastomosis because of the higher than usual risk that a fluid collection will develop. Drainage is rarely helpful after a gastric or small bowel anastomosis. Drains are indicated, however, after emergency operations for peritonitis or trauma in which it was necessary to close or anastomose damaged or inflamed bowel.

#### **Operative Techniques for Selected Anastomoses**

The following section covers the essential preliminary steps before a bowel anastomosis and then describes three generic operations involving the small and large bowel. These procedures illustrate many of the general principles previously discussed (see above).

##### PATIENT POSITIONING AND INCISION

Patients must be positioned on the operating table in a manner that is appropriate for the planned operation. Most abdominal operations are now performed by laparoscopic means. For pelvic procedures, the patient is placed in the lithotomy position to allow access to the abdomen and the anus; care must be taken to position the legs and feet in the stirrups correctly, without excessive flexion or abduction and with sufficient padding to prevent pressure ulceration, thrombosis, and neurapraxia. For esophageal procedures, the patient is positioned lying on the appropriate side, and the incision of choice is a lateral thoracotomy. Occasionally, the patient must be shifted to a different position during the course of an operation. Gravity can be useful for moving structures out of the way. Accordingly, it is often helpful to alter the axis of the operating table. For example, a 30° head-down or Trendelenburg position facilitates pelvic operations.

##### EXPOSURE, MOBILIZATION, AND DISSECTION

The principles of laparoscopic surgery have now been widely accepted. A periumbilical port is placed for adequate visualization of the operating field. Operating ports are placed in the midclavicular line on the opposite side to the point of focus. The lateral aspects of the field can be controlled using a suitable laparoscopic retraction with conveniently placed additional ports. As for open surgery, it is important to compartmentalize the abdomen. This can be done in a number of ways. The small bowel can be extremely difficult to handle; therefore, the operating table can be moved in different directions to aid access to surgical planes.

The next stage involves mobilizing the bowel so that it can be brought easily out through a small abdominal wall incision. In the absence of adhesions or tethering caused by disease, the small bowel is usually sufficiently mobile to allow the relevant segment to be brought out of the abdomen easily. Sometimes the transverse colon and the sigmoid colon are mobile enough to be brought to the surface. More commonly, however, as with the other sections of the large bowel, the peritoneum must be divided along the lateral border of the colon and the retroperitoneal structures reflected posteriorly [see Figure 8]. Tension is rarely a problem during small bowel anastomosis, but for colonic or esophageal anastomoses, it is absolutely vital that the two ends of bowel to be joined lie together easily. For a large bowel anastomosis, this means that the splenic flexure or the hepatic flexure—or, sometimes, both—must be adequately mobilized. This can be done using hook diathermy (for the surgical purists) or commercially available handheld energy devices, such as ultrasonic scalpels that can coagulate small sections of tissue between the jaws of the instrument with simultaneous occlusion of all blood vessels up to a certain size. Consequently, bleeding is reduced, fewer (or no) ties

are needed, and only a small quantity of dead tissue results at each point. Becoming skilled in the use of these instruments often takes a little time, but the time is well spent in that it is now possible to perform an intestinal resection without resorting to a single tie.

#### BOWEL RESECTION

The precise techniques involved in resecting specific bowel segments are not discussed in great detail here. (Colonic resection, for example, is described elsewhere in the publication.) The following discussion outlines only the general principles.

##### *Preparation*

The segment of bowel to be removed must be isolated with an adequate resection margin. To this end, all surrounding adhesions are divided. Next, the mesentery is divided, and this can be done either intra- or extracorporeally. The key consideration in this step is to preserve the blood supply to the two remaining ends of bowel while still achieving adequate excision of the diseased bowel. This is more easily accomplished in the small bowel than in the

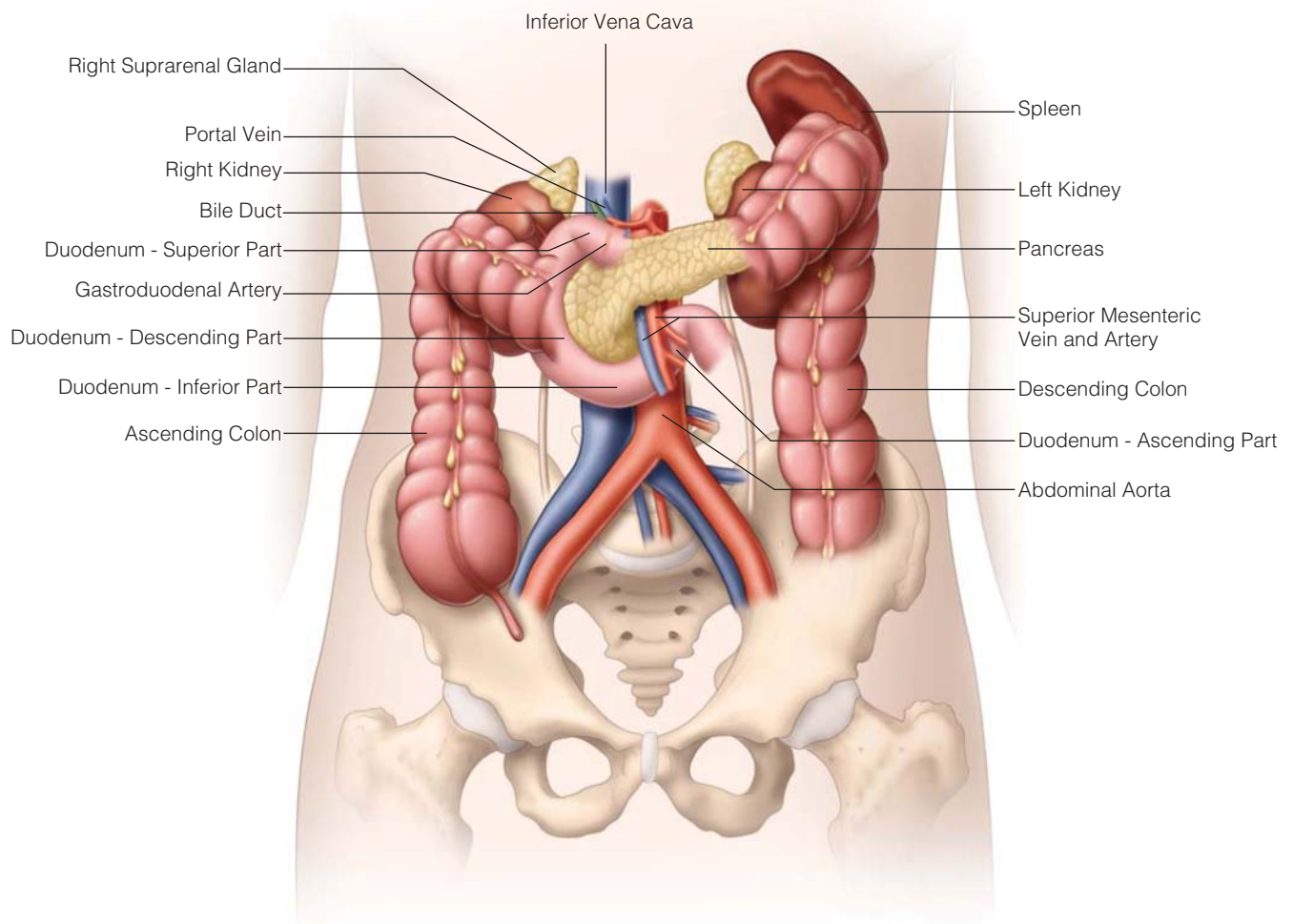


Figure 8 Anatomic relations between the colon and the retroperitoneal organs.

large bowel thanks to the ample blood supply of the former; even so, transillumination of the mesentery and careful division of the vascular arcade are vital. In the colon, the surrounding fat and the appendices epiploicae should be cleared from the remaining bowel ends so that subsequent suture placement is straightforward.

#### *Division of Bowel*

This can be achieved either intra- or extracorporeally. If staplers are not available, the bowel segment to be removed is isolated between noncrushing clamps placed across the intestinal lumen some distance away from the resection margin so as to limit the amount of bowel contents that can escape into the wound. Crushing clamps are then placed on the specimen side of the diseased segment at the point of the resection, and the bowel is divided with a knife just proximal and distal to the clamps. Thus, the lumen of the diseased segment is never open within the abdominal wound. Even so, the contents of the bowel between the open ends and the noncrushing clamps can leak into the wound. To minimize this problem, it is usual to isolate the working area with abdominal packs, which are sometimes soaked in an antiseptic (e.g., povidone-iodine).

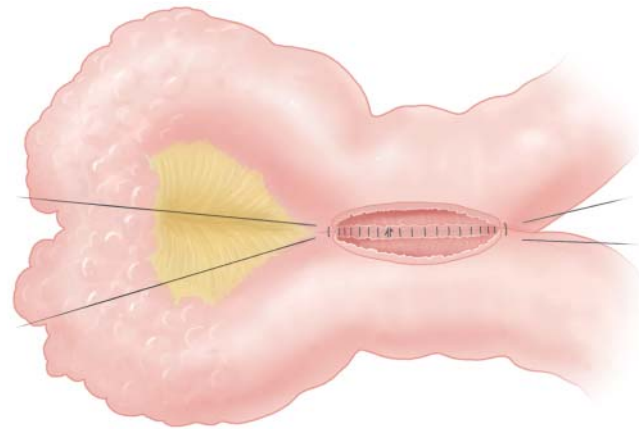
One advantage of using staplers for an anastomosis is that in most instances, division of the bowel can be accomplished without opening the lumen. A variety of laparoscopic staplers are now available for intracorporeal division. A linear cutting stapler (e.g., GIA) transects the bowel and seals the two cut ends simultaneously. In the pelvis, angulation using a special hinge on the linear stapler can be used to obtain as much length as possible distal to the lesion.

#### SIMPLE BOWEL CLOSURE

There are occasions when the bowel damage requires simple repair rather than a formal resection. This may happen in circumstances such as perforated duodenal ulcers or an iatrogenic injury during adhesiolysis. This may be closed in a number of ways, both laparoscopically or open. Most surgeons would repair such holes with absorbable sutures such as Vicryl. Special mention should be made of the technique of strictureplasty, which is used for a number of benign small bowel strictures (especially those resulting from Crohn disease) as a means of avoiding small bowel resection and anastomoses. In this procedure, the bowel is opened longitudinally and closed transversely with a single layer of 2-0 polyglycolic acid sutures in a Connell stitch. Excellent functional results have been achieved with this technique despite its reputation for fistula formation, which is associated with Crohn disease.

#### SINGLE-LAYER SUTURED EXTRAMUCOSAL SIDE-TO-SIDE ENTEROENTEROSTOMY

A side-to-side anastomosis [see Figure 9] may be performed when no resection is done, as a bypass procedure (e.g., a gastroenterostomy); after a small bowel resection; when there is a discrepancy in the diameter of the two ends to be anastomosed (e.g., an ileocolic anastomosis after a right hemicolectomy); or when the anatomy is such that the most tension-free position for the anastomosis is with the two bowel segments parallel (as in a Finney strictureplasty [see Figure 10]).

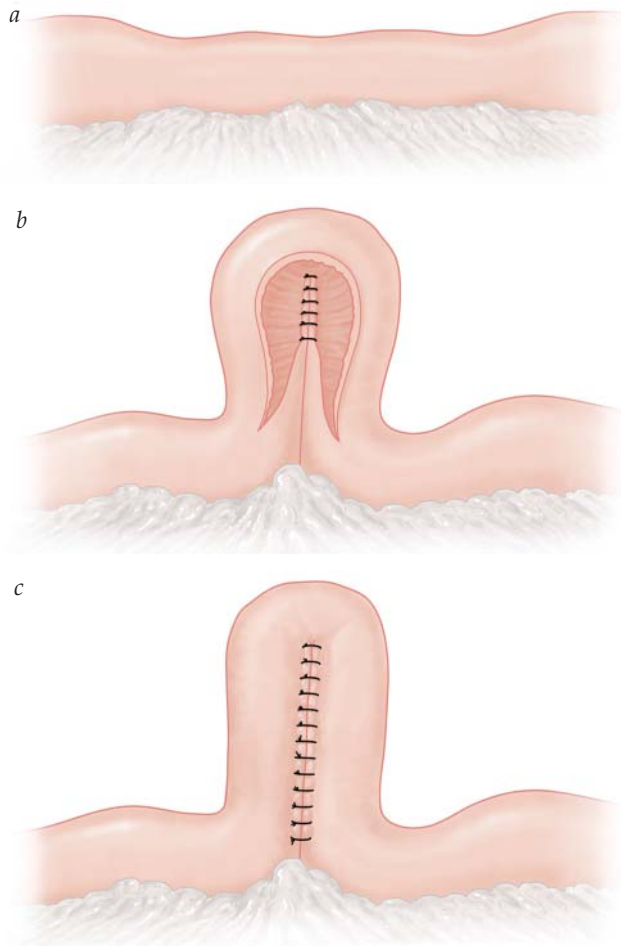


**Figure 9** Single-layer sutured extramucosal side-to-side enteroenterostomy. A full-length suture is started in the back wall and run through the seromuscular and submucosal layers in the direction of the surgeon; the corners of the enterotomy are approximated with a baseball stitch, and a single Connell stitch is used to invert the anterior layer. A second suture is started at the same spot on the posterior wall and run in the opposite direction, again through all layers except the mucosa; the corners of the enterotomies are approximated with a baseball stitch, and the suture is continued in either the Connell stitch or the over-and-over stitch to complete the anterior wall of the anastomosis.

Two stay sutures of 3-0 polyglycolic acid are placed approximately 8 cm apart on the inner aspect of the antimesenteric border. A 5 cm enterotomy is made on each loop with an electrocautery or a blade on the inner aspect of the antimesenteric border. If electrocautery is used, care must be taken not to injure the mucosa of the posterior wall during this maneuver; placement of a hemostat into the enterotomy to lift the anterior wall usually prevents this problem. Hemostasis of the cut edges is ensured, and the remaining enteric contents are gently suctioned out. A swab soaked in povidone-iodine may be used at this point to cleanse the lumen of the bowel in the para-anastomotic region.

A full-length seromuscular and submucosal stitch of 4-0 polyglycolic acid is placed and tied on the inside approximately 5 to 10 mm from the far end of the enterotomies. The stitch is not passed through the mucosa: to do so would add no strength to the anastomosis and would hinder epithelialization by rendering the tissue ischemic. A hemostat is placed on the short end of the tied suture, and the assistant applies continuous gentle tension to the long end of the suture. An over-and-over stitch is started in the direction of the surgeon; small bites are taken, and proper inversion of the suture line is ensured with each pass through tissue. When the proximal ends of the enterostomies are reached, this so-called baseball stitch is continued almost completely around to the anterior wall of the anastomosis. A single Connell stitch may be used to invert this anterior layer.

Another full-length seromuscular and submucosal suture of 4-0 polyglycolic acid is then inserted and tied at the same location in the posterior wall as the first. If the two sutures are placed close enough together, the short ends need not be tied together and may simply be cut off. The remainder of the posterior wall is sewn away from the surgeon in the same manner as the portion already sewn, and the corners

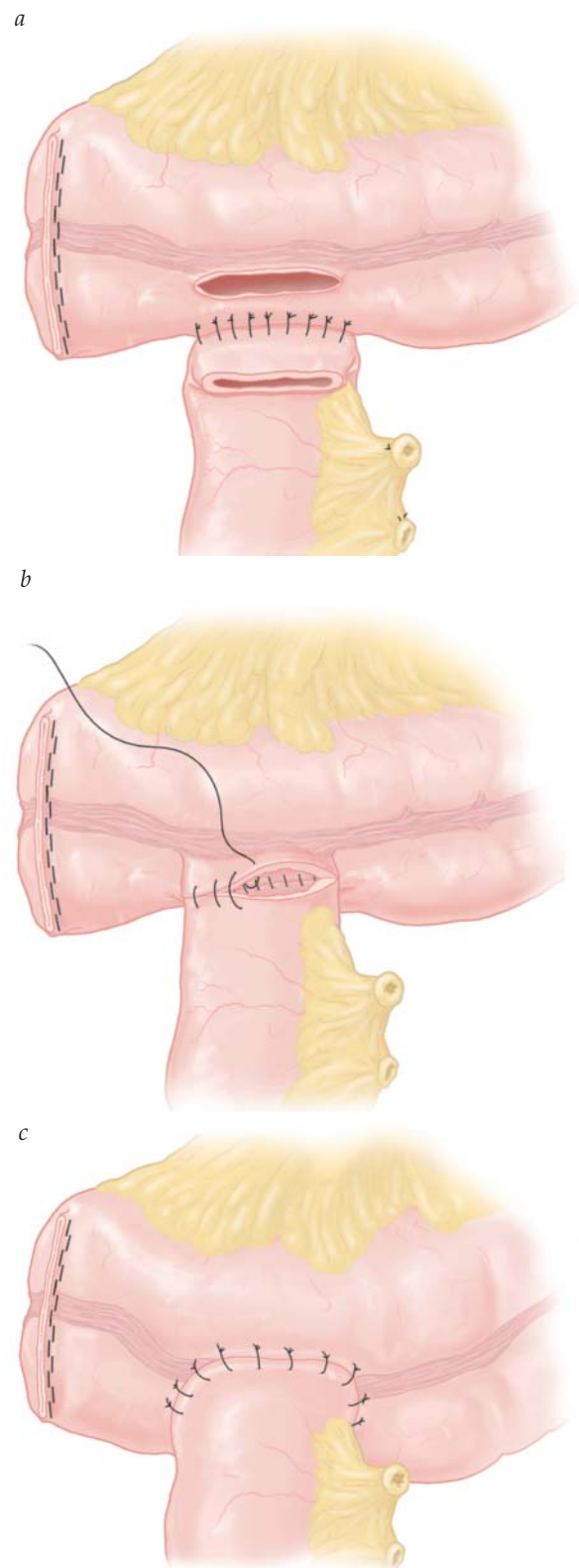


**Figure 10** Finney strictureplasty. (a) This procedure is suitable for longer areas of stricture (up to 10 to 15 cm). (b) The strictured bowel is bent into the shape of an inverted U. Stay sutures are placed at the apex of the U, which is at the midpoint of the stricture, and at the far ends, which lie 1 to 2 cm proximal and distal to the stricture. A longitudinal enterotomy is made on the antimesenteric border of the bowel with the electrocautery. A side-to-side anastomosis is then performed, with the posterior wall done first. (c) The completed anastomosis.

are approximated with the baseball stitch. The anterior wall is then completed with this second suture, either with the Connell stitch or with an over-and-over stitch, with the assistant inverting the edges before applying tension to the previous stitch. When the defect is completely closed, the two sutures are tied across the anastomotic line. The stay sutures are removed, and the anastomosis is carefully inspected. Often there is no mesenteric defect to close in a side-to-side anastomosis, but if there is one, it should be approximated at this point with continuous or interrupted absorbable sutures, with care taken not to injure the vascular supply to the anastomosis.

#### DOUBLE-LAYER SUTURED END-TO-SIDE ENTEROCOLOSTOMY

In this procedure, the end of the ileum is joined to the side of the transverse colon [see *Figure 11*]. The distal colon is divided with a cutting stapler so that a blind end is left.



**Figure 11** Double-layer sutured end-to-side enterocolostomy. (a) The proximal bowel end is stapled, interrupted Lembert stitches are used to form the posterior outer layer, and a colotomy is made. (b) Two continuous sutures are used to form the inner layer of the anastomosis; the posterior portion is done with the over-and-over stitch and the anterior with the Connell stitch. (c) Interrupted Lembert stitches are used to form the anterior outer layer.

Some surgeons underpin or bury this staple line, although this practice is probably unnecessary. The proximal cut end of the intestine is similarly closed either with staples after division with a cutting linear stapler or with a crushing bowel clamp. This proximal end is brought into apposition with the side of the distal bowel segment at a point no farther than 2.5 to 5 cm from the blind end of the distal segment; this proximity to the cut end is important for prevention of the blind loop syndrome. Stay sutures of 3-0 polyglycolic acid are placed between the serosa of the proximal limb, about 10 to 15 mm from the clamp, and the serosa of the distal limb. Interrupted seromuscular sutures of 3-0 polyglycolic acid are then placed between these stay sutures, spaced about three to six to the centimeter. These stitches may be tied sequentially or snapped and tied once they are all in place. It is crucial not to apply excessive tension, which could cut the seromuscular layer or render it ischemic. Suction is then readied. The staple line or crushed tissue on the proximal limb is cut off with a coagulating electrocautery or a knife; this maneuver opens the lumen of the proximal limb. All residual intestinal content is gently suctioned. An enterotomy or colotomy is created on the distal limb opposite the open lumen of the proximal bowel. A full-thickness suture of 3-0 polyglycolic acid is inserted in the posterior wall at a point close to the far end of the enterotomy and run in an over-and-over stitch back toward the surgeon. The corner is rounded with the baseball stitch, and when the anterior wall is reached, the Connell stitch is used. A second full-length 3-0 suture is started at the same point on the posterior wall as the first, and the short ends of the two sutures are tied together and cut. This second suture is then run away from the surgeon to complete the posterior wall, and the anterior wall is completed with the Connell stitch. The two sutures are then tied across the anastomotic line. A second series of interrupted seromuscular stitches is then placed anteriorly in the same fashion as the seromuscular stitches placed in the posterior wall. It is important not to narrow either lumen excessively by imbricating too much of the bowel wall into this second layer. The lumen of the anastomosis is palpated to confirm patency, and the mesenteric defect is closed if possible with either continuous or interrupted absorbable sutures. The integrity of the join can be tested by injecting 20 mL of saline into the lumen of the bowel, which is then placed under gentle pressure by simultaneously finger-clamping a couple of centimeters either side of the anastomosis.

#### DOUBLE-STAPLED END-TO-END COLOANAL ANASTOMOSIS

Resection of the distal sigmoid colon and the rectum is a common procedure. In the past, it often resulted in a permanent colostomy because of the technical difficulties associated with a hand-sewn anastomosis deep in the pelvis. The development of circular staplers reduced the technical difficulty of the operation [see Table 11] and made possible anastomoses as far down as the anus [see Figure 12].

Proper preparation of the patient and the bowel is essential before resection of the rectum. The patient is placed in the Lloyd-Davies position with the head tilted down, and the small bowel is packed away in the upper abdomen. This positioning gives the surgeon the best access to the pelvis. The splenic flexure and the distal large bowel are fully

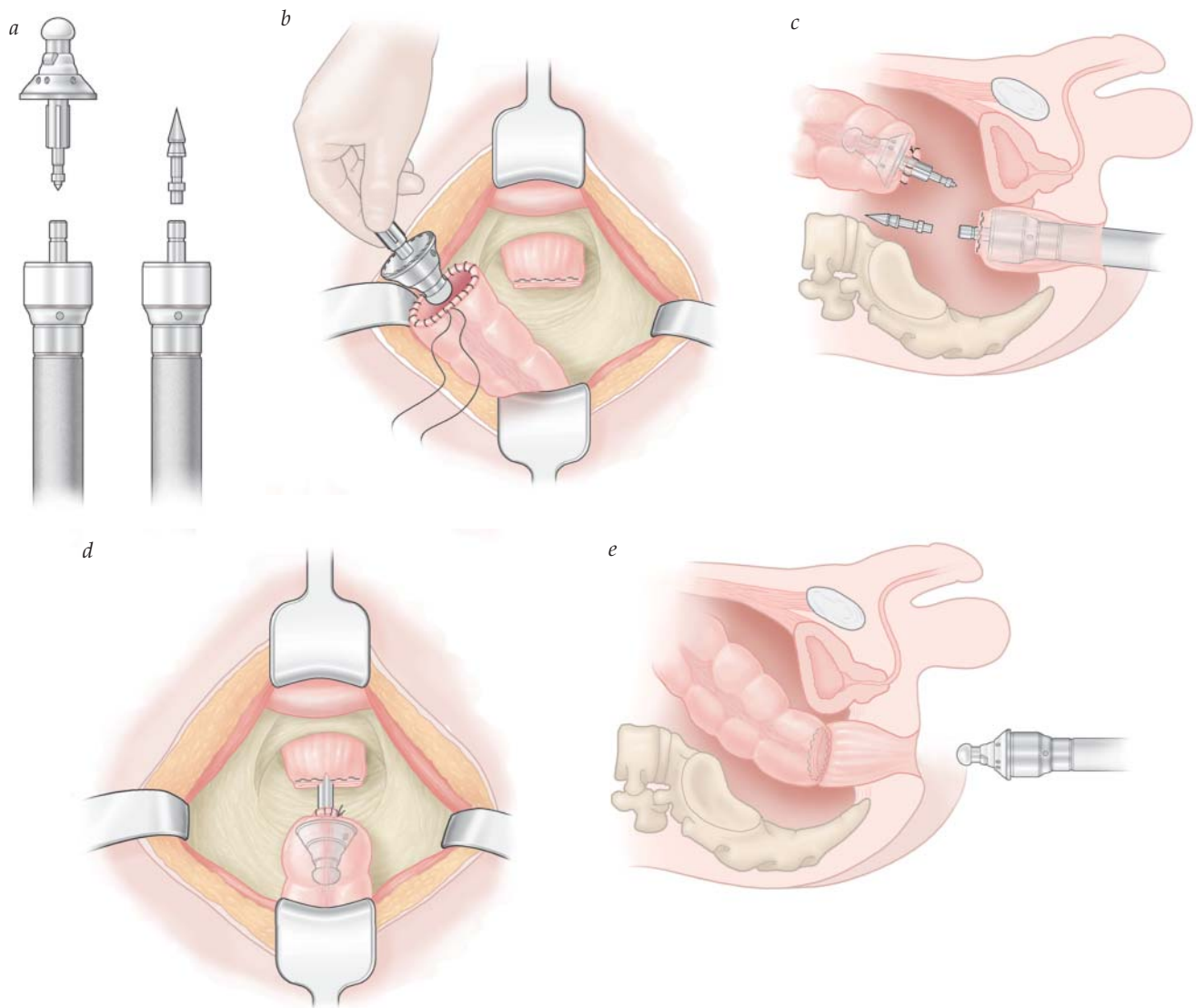
**Table 11 Salvage after Anastomotic Leakage**

Close monitoring
Daily blood tests, including CRP
Early investigations: CT (with rectal contrast for left-sided anastomoses)
Early reoperation if concern
Consider options:
Takedown of anastomoses and end stoma
Resuture small defect with abdominal drainage and upstream stoma
If low rectal anastomosis, then transanal assessment with use of VAC endosponge to manage pelvic sepsis

CRP = C-reactive protein; CT = computed tomography; VAC = vacuum-assisted closure.

mobilized along with the rectum. The distal resection margin is determined and cleared of mesorectal fat, and the bowel is divided using an endo-GIA device, taking care of the pelvic sidewall. The specimen can then be removed via a small incision made on the abdominal wall with added protection of a wound guard. Adequate pelvic hemostasis is ensured. Once the surgeon is satisfied that the bowel is sufficiently mobilized, the colonic specimen is brought through the abdominal wall incision and a noncrushing bowel clamp is placed on the colon 20 cm proximal to the margin. At this stage, an 8 to 10 cm colonic J pouch can be created; this measure typically yields a substantially improved functional outcome, especially in the early postoperative period in older patients.<sup>83</sup> A whip-stitch (or purse-string suture) of 2-0 polypropylene is placed around the colotomy, and the anvil from the appropriately sized curved EEA stapler is inserted into the open end and secured in place by tying the suture [see Figure 12]. The proximal bowel clamp is removed. The anastomosis can then be created by reintroduction of the colonic conduit into the abdomen and reinsufflation using a “glove port” [see Figure 13]. The assistant—who may also, if desired, gently wash out the rectal stump with a dilute povidone-iodine solution—performs a digital rectal examination. The stapler, with its trocar attachment in place, is then inserted into the anus under the careful guidance of the surgeon. The pointed shaft is brought out through or adjacent to the linear staple line, and the sharp point is removed. The peg from the anvil in the proximal colon is snapped into the protruding shaft of the stapler, and the two edges are slowly brought together. The colonic mesentery must not be twisted, and the ends must come together without any tension whatsoever. The stapler is fired. In some types of stapling guns, a crunching sound is heard. The anvil is then loosened the appropriate amount, and the entire mechanism is withdrawn through the anus. Finally, the proximal and distal rings of tissue, which remain on the stapler, are carefully inspected to confirm circumferential closure of the staple line. The pelvis is then filled with body-temperature saline, and a Toomey or bladder syringe is used to insufflate the neorectum with air. The surgeon watches for bubbling in the pelvis as a sign of leakage from the anastomosis. If there is a leak, additional soluble sutures must be placed to close the defect and another air test performed. A rectal tube may then be inserted by the assistant or may be placed at the end of the procedure. When the anastomosis is very low or





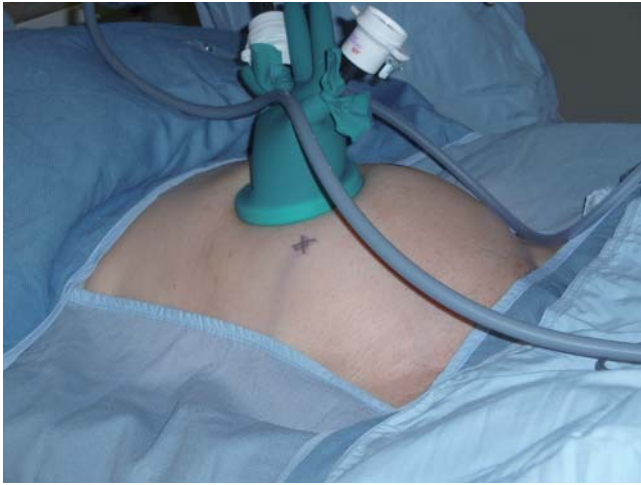**Figure 12** Double-stapled end-to-end coloanal anastomosis. (a) The circular-end-to-end anastomosis stapler comes with both a standard anvil (left) and a trocar attachment (right). A more recent version of these staplers comes with a trocar in the body rather than in the head of the device. (b) The rectal stump is closed with an angled linear noncutting stapler. A purse-string suture is placed around the colotomy, and the anvil of the stapler is placed in the open end and secured. (c) The stapler, with the sharp trocar attachment in place, is inserted into the anus, and the trocar is made to pierce the rectal stump at or near the staple line, after which the trocar is removed. (d) The anvil in the proximal colon is joined with the stapler in the rectal stump, and the two edges are slowly brought together. (e) The stapler is fired and then gently withdrawn.

there is some concern about healing, a drain may be placed in the pelvis behind the staple line; however, as noted [see Controversial Issues in Intestinal Anastomosis, *above*], this practice has not been shown to be beneficial and may impair healing.

As mentioned previously, a meta-analysis by MacRae and McLeod demonstrated an association between the use of staplers and colorectal anastomotic strictures when compared with hand-sewn anastomosis.<sup>39</sup> There is uncertainty regarding the cause of this. Most of these patients were found to be asymptomatic, and in those who required treatment, simple dilatation was sufficient to rectify the problem. A more recent Cochrane review in 2007 found no increased risk of anastomotic stricture in patients undergoing ileocolic resection with a linear cutter stapler.<sup>40</sup>

#### Techniques for Assessing Anastomoses Intraoperatively

Due to the risk of major consequences from anastomotic leakage, there is a need for robust mechanisms to test their integrity.<sup>84</sup> This includes the assessment of the “complete” doughnut after firing the EEA stapler, staple line visualization, and exclusion of “bubbling” after air insufflation of the distal rectum [see Table 12] (after anterior resection). Despite these techniques, leakage can still occur. This has led to the introduction of formal testing of anastomotic perfusion using specially designed laparoscopes that can detect intravenously administration of indocyanine green. Intraoperatively, this is seen as appearance of “green” segments of bowel that indicate adequate perfusion [see Figure 14]. Suboptimal perfusion would then lead to further resection and recreation of anastomosis. It remains to be seen whether



**Figure 13** Use of a “glove” port in laparoscopic surgery. A surgical glove can be used to reinsufflate the abdomen during laparoscopic colorectal resections. A seal is created by placing the glove over a laparoscopic wound protector. Each of the “fingers” can be used for insertion of ports.

**Table 12** Standard Checks for Creation of Anastomoses

Any tension?  
 Any rotation of the mesentery?  
 Vascularity?  
 Are the doughnuts complete (for circular stapling devices)?  
 Leak test?  
 Need for defunctioning?

this reduces the rate of leakage. It is vital that patients are closely monitored even after the construction of “good” anastomoses and salvaged early if they display evidence of subsequent leakage [see Table 13].

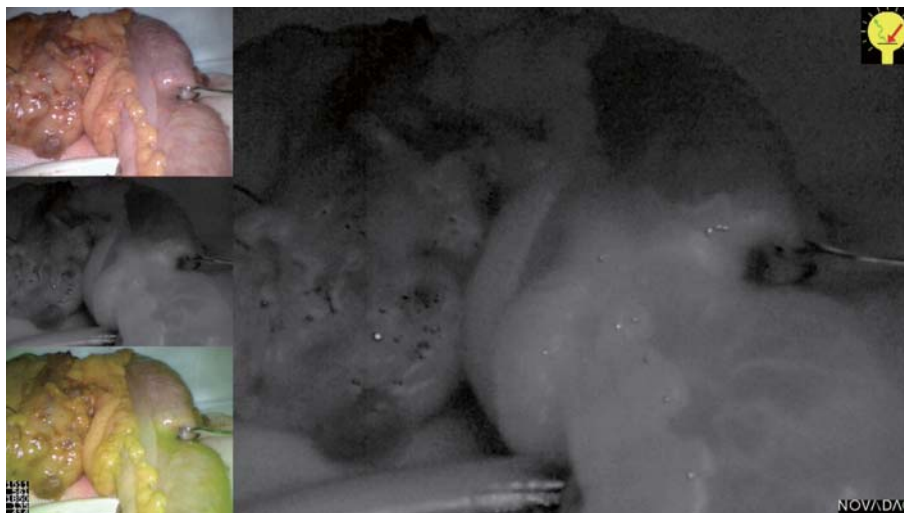
**Table 13** Steps for Left-Sided Stapled Colorectal Anastomoses for Cancer

1. Position patient in Lloyd-Davies position
2. Assess disease extent
3. Mobilize the splenic flexure and distal colon
4. Mobilize the rectum in the mesorectal fascial plane
5. Determine and transect the rectum at adequate distal margin point
6. Resect the specimen
7. Insert anvil of stapling gun into proximal colonic conduit using a purse-string
8. Insert stapling gun into rectum and attach the anvil to the trochar
9. Deploy the stapler and assess the anastomosis
10. Check “doughnuts”
11. Defunctioning stoma if necessary

### Conclusion

All anastomoses, no matter how technically sound on creation, can fail. The limiting factor may be the tissue or the resulting inflammatory sequelae that follow closure of the abdominal wall. It is important to monitor patients closely following surgery and undertake early salvage if leakage does occur. Even if fecal diversion has been carried out, it is important to keep a close observation for any signs of failure.

Anastomosis failure rates have improved over the last two centuries, with improvements in postoperative morbidity and mortality. This can be attributed to a combination of factors, such as better appreciation of the principles of healing, as well as improved anesthesia, antibiotic prophylaxis, and postoperative monitoring. Now, with the emergence of laparoscopic colorectal surgery, it is essential that the surgeon continues to practice the same principles of creating a join, with good apposition of the edges, that is tension free and has an optimal blood supply, just as for open surgery.



**Figure 14** Assessing perfusion at the time of anastomotic creation. Indocyanine green can be injected intravenously, and the take-up of dye within the proximal and distal ends of the anastomoses can be used to determine vascularization. The *top left* picture shows the normal image using a standard laparoscope; the *middle left* and *right* pictures show the same image using a near-infrared laparoscope; the *bottom left* picture shows the superimposed images.

*Financial Disclosures:* Neil J. Mortensen, MD, FRCS, and Shazad Ashraf, DPhil, FRCS, have no relevant financial relationships to disclose.

## References

- Singh KK, Aitken RJ. Outcome in patients with colorectal cancer managed by surgical trainees. *Br J Surg* 1999;86:1332–6.
- Gillespie IE. Intestinal anastomosis. *Br Med J (Clin Res Ed)* 1983;286:1002.
- Smith SR, Connolly JC, Crane PW, Gilmore OJ. The effect of surgical drainage materials on colonic healing. *Br J Surg* 1982;69:153.
- Matthiessen P, Hallbook O, Rutegard J, et al. Defunctioning stoma reduces symptomatic anastomotic leakage after low anterior resection of the rectum for cancer: a randomized multicenter trial. *Ann Surg* 2007;246:207–14.
- Enker WE, Merchant N, Cohen AM, et al. Safety and efficacy of low anterior resection for rectal cancer: 681 consecutive cases from a specialty service. *Ann Surg* 1999;230:544–52; discussion 52–4.
- Matthiessen P, Hallbook O, Andersson M, et al. Risk factors for anastomotic leakage after anterior resection of the rectum. *Colorectal Dis* 2004;6:462–9.
- Fielding LP, Stewart-Brown S, Blesovsky L, Kearney G. Anastomotic integrity after operations for large-bowel cancer: a multicentre study. *Br Med J* 1980;281:411–4.
- Karanjia ND, Corder AP, Bearn P, Heald RJ. Leakage from stapled low anastomosis after total mesorectal excision for carcinoma of the rectum. *Br J Surg* 1994;81:1224–6.
- Pakkastie TE, Luukkonen PE, Jarvinen HJ. Anastomotic leakage after anterior resection of the rectum. *Eur J Surg* 1994;160:293–7; discussion 9–300.
- de Hingh IH, de Man BM, Lomme RM, et al. Colonic anastomotic strength and matrix metalloproteinase activity in an experimental model of bacterial peritonitis. *Br J Surg* 2003;90:981–8.
- Syk I, Agren MS, Adawi D, Jeppsson B. Inhibition of matrix metalloproteinases enhances breaking strength of colonic anastomoses in an experimental model. *Br J Surg* 2001;88:228–34.
- Hesp F, Hendriks T, Lubbers E-J. Wound healing in the intestinal wall: a comparison between experimental ileal and colonic anastomoses. *Dis Colon Rectum* 1984;24:99.
- Wise L, McAlister W, Stein T. Studies on the healing of anastomoses of small and large intestines. *Surg Gynecol Obstet* 1975;141:190.
- Martens MF, Hendriks T. Postoperative changes in collagen synthesis in intestinal anastomoses of the rat: differences between small and large bowel. *Gut* 1991;32:1482–7.
- Martens MF, de Man BM, Hendriks T, Goris RJ. Collagen synthetic capacity throughout the uninjured and anastomosed intestinal wall. *Am J Surg* 1992;164:354–60.
- Khoury GA WB. Large bowel anastomosis: I. The healing process and sutured anastomoses: a review. *Br J Surg* 1983;70:61.
- Schrock TR, Deveney CW, Dunphy JE. Factors contributing to leakage of colonic anastomoses. *Ann Surg* 1973;177:513.
- Daly JM, Vars HM, Dudrick SJ. Effects of protein depletion on strength of colonic anastomoses. *Surg Gynecol Obstet* 1972;134:15–21.
- Hastings JC, Van Winkle W, Barker E. Effects of suture materials on healing of wounds of the stomach and colon. *Surg Gynecol Obstet* 1975;140:701.
- Tagart RE. Colorectal anastomosis: factors influencing success. *J R Soc Med* 1981;74:111–8.
- Bissett IP. Ileocolic anastomosis. *Br J Surg* 2007;94:1447–8.
- Munday C, McGinn FP. A comparison of polyglycolic acid and catgut sutures in rat colonic anastomoses. *Br J Surg* 1976;63:870–2.
- Koruda MJ, Rolandelli RH. Experimental studies on the healing of colonic anastomoses. *J Surg Res* 1990;48:504–15.
- Olsen GB, Letwin E, Williams HT. Clinical experience with the use of a single-layer intestinal anastomosis. *Can J Surg* 1968;11:97–100.
- Irvin TT, Goligher JC. Aetiology of disruption of intestinal anastomoses. *Br J Surg* 1973;60:461–4.
- Sarin S, Lightwood RG. Continuous single-layer gastrointestinal anastomosis: a prospective audit. *Br J Surg* 1989;76:493–5.
- Shandall A, Lowndes R, Young HL. Colonic anastomotic healing and oxygen tension. *Br J Surg* 1985;72:606–9.
- Jiborn H, Ahonen J, Zederfeldt B. Healing of experimental colonic anastomoses. III. Collagen metabolism in the colon after left colon resection. *Am J Surg* 1980;139:398–405.
- Burch JM, Franciose RJ, Moore EE, et al. Single-layer continuous versus two-layer interrupted intestinal anastomosis: a prospective randomized trial. *Ann Surg* 2000;231:832–7.
- Shikata S, Yamagishi H, Taji Y, et al. Single- versus two-layer intestinal anastomosis: a meta-analysis of randomized controlled trials. *BMC Surg* 2006;6:2.
- Chassin JL, Rifkind KM, Turner JW. Errors and pitfalls in stapling gastrointestinal tract anastomoses. *Surg Clin North Am* 1984;64:441–59.
- Ravitch MM. Intersecting staple lines in intestinal anastomoses. *Surgery* 1985;97:8–15.
- Chung RS. Blood flow in colonic anastomoses. Effect of stapling and suturing. *Ann Surg* 1987;206:335–9.
- Julian TB, Ravitch MM. Evaluation of the safety of end-to-end (EEA) stapling anastomoses across linear stapled closures. *Surg Clin North Am* 1984;64:567–77.
- Brennan SS, Pickford IR, Evans M, Pollock AV. Staples or sutures for colonic anastomoses—a controlled clinical trial. *Br J Surg* 1982;69:722–4.
- Greenstein A, Rogers P, Moss G. Doubled fourth-day colorectal anastomotic strength with complete retention of intestinal mature wound collagen and accelerated deposition following immediate full enteral nutrition. *Surg Forum* 1978;29:78–81.
- Kracht M, Hay JM, Fagniez PL, Fingerhut A. Ileocolic anastomosis after right hemicolectomy for carcinoma: stapled or hand-sewn? A prospective, multicenter, randomized trial. *Int J Colorectal Dis* 1993;8:29–33.
- Docherty JG, McGregor JR, Akyol AM, et al. Comparison of manually constructed and stapled anastomoses in colorectal surgery. West of Scotland and Highland Anastomosis Study Group. *Ann Surg* 1995;221:176–84.
- MacRae HM, McLeod RS. Handsewn vs. stapled anastomoses in colon and rectal surgery: a meta-analysis. *Dis Colon Rectum* 1998;41:180–9.

40. Choy PYG, Bissett IP, Docherty JG, et al. Stapled versus handsewn methods for ileocolic anastomoses. *Cochrane Database Syst Rev* 2007;3:CD004320.
41. Akyol AM, McGregor JR, Galloway DJ, et al. Recurrence of colorectal cancer after sutured and stapled large bowel anastomoses. *Br J Surg* 1991;78:1297–300.
42. O'Dwyer P, Ravikumar TS, Steele G Jr. Serum dependent variability in the adherence of tumour cells to surgical sutures. *Br J Surg* 1985;72:466–9.
43. Murphy JB. A contribution to abdominal surgery, ideal approximation of abdominal viscera without suture. *North American Practitioner* 1892;4:481.
44. Ballantyne GH. The experimental basis of intestinal suturing. Effect of surgical technique, inflammation, and infection on enteric wound healing. *Dis Colon Rectum* 1984;27:61–71.
45. Rullier E, Laurent C, Garrelon JL, et al. Risk factors for anastomotic leakage after resection of rectal cancer. *Br J Surg* 1998;85:355–8.
46. Dehni N, Schlegel RD, Cunningham C, et al. Influence of a defunctioning stoma on leakage rates after low colorectal anastomosis and colonic J pouch-anal anastomosis. *Br J Surg* 1998;85:1114–7.
47. Heald RJ, Husband EM, Ryall RD. The mesorectum in rectal cancer surgery—the clue to pelvic recurrence? *Br J Surg* 1982;69:613–6.
48. Carlsen E, Schlichting E, Guldvog I, et al. Effect of the introduction of total mesorectal excision for the treatment of rectal cancer. *Br J Surg* 1998;85:526–9.
49. Edwards DP. The history of colonic surgery in war. *J R Army Med Corps* 1999;145:107–8.
50. Halsted WS. Circular suture of the intestine: an experimental study. *Am J Med Sci* 1887;94:436–61.
51. The Association of Coloproctology of Great Britain and Ireland. Guidelines for the management of colorectal cancer (2001). London: The Association of Coloproctology of Great Britain and Ireland; 2001.
52. Guenaga KF, Matos D, Castro AA, et al. Mechanical bowel preparation for elective colorectal surgery. *Cochrane Database Syst Rev* 2005;(1):CD001544.
53. Nichols RL, Condon RE. Preoperative preparation of the colon. *Surg Gynecol Obstet* 1971;132:323–37.
54. Bucher P, Gervaz P, Soravia C, et al. Randomized clinical trial of mechanical bowel preparation versus no preparation before elective left-sided colorectal surgery. *Br J Surg* 2005;92:409–14.
55. Contant CM, Hop WC, van't Sant HP, et al. Mechanical bowel preparation for elective colorectal surgery: a multicentre randomised trial. *Lancet* 2007;370:2112–7.
56. Jung B, Pahlman L, Nystrom PO, Nilsson E. Multicentre randomized clinical trial of mechanical bowel preparation in elective colonic resection. *Br J Surg* 2007;94:689–95.
57. Bucher P, Gervaz P, Morel P. Should preoperative mechanical bowel preparation be abandoned? *Ann Surg* 2007;245:662.
58. Nichols RL, Gorbach SL, Condon RE. Alteration of intestinal microflora following preoperative mechanical preparation of the colon. *Dis Colon Rectum* 1971;14:123–7.
59. Jimenez JC, Wilson SE. Prophylaxis of infection for elective colorectal surgery. *Surg Infect (Larchmt)* 2003;4:273–80.
60. Thomas C, Stevenson M, Riley TV. Antibiotics and hospital-acquired *Clostridium difficile*-associated diarrhoea: a systematic review. *J Antimicrob Chemother* 2003;51:1339–50.
61. McFarland LV, Surawicz CM, Stamm WE. Risk factors for *Clostridium difficile* carriage and *C. difficile*-associated diarrhea in a cohort of hospitalized patients. *J Infect Dis* 1990;162:678–84.
62. Chang VT, Nelson K. The role of physical proximity in nosocomial diarrhea. *Clin Infect Dis* 2000;31:717–22.
63. Millikan KW, Szczerba SM, Dominguez JM, et al. Superior mesenteric and portal vein thrombosis following laparoscopic-assisted right hemicolectomy. Report of a case. *Dis Colon Rectum* 1996;39:1171–5.
64. Bozzetti F. Perioperative nutrition of patients with gastrointestinal cancer. *Br J Surg* 2002;89:1201–2.
65. Carty NJ, Keating J, Campbell J, et al. Prospective audit of an extramucosal technique for intestinal anastomosis. *Br J Surg* 1991;78:1439.
66. Munck A, Guyre PM, Holbrook NJ. Physiological functions of glucocorticoids in stress and their relation to pharmacological actions. *Endocr Rev* 1984;5:25–44.
67. Matsusue S, Walser M. Healing of intestinal anastomoses in adrenalectomized rats given corticosterone. *Am J Physiol* 1992;263(1 Pt 2):R164–8.
68. Quan ZY, Walser M. Effect of corticosterone administration at varying levels on leucine oxidation and whole body protein synthesis and breakdown in adrenalectomized rats. *Metabolism* 1991;40:1263–7.
69. Sorensen LT, Jorgensen T, Kirkeby LT, et al. Smoking and alcohol abuse are major risk factors for anastomotic leakage in colorectal surgery. *Br J Surg* 1999;86:927–31.
70. Getzen LC. Intestinal suturing. I. The development of intestinal sutures. *Curr Probl Surg* 1969;3:48.
71. Kratzer GL, Onsanit T. Single layer steel wire anastomosis of the intestine. *Surg Gynecol Obstet* 1974;139:93–4.
72. Ravitch MM, Steichen FM. Technics of staple suturing in the gastrointestinal tract. *Ann Surg* 1972;175:815–37.
73. Brunius U, Zederfeldt B. Effects of antiinflammatory treatment on wound healing. *Acta Chir Scand* 1965;129:462–7.
74. Goligher JC, Morris C, McAdam WA, et al. A controlled trial of inverting versus everting intestinal suture in clinical large bowel surgery. *Br J Surg* 1970;57:817.
75. Burg R, Geigle CF, Faso JM, Theuerkauf FJ Jr. Omission of routine gastric decompression. *Dis Colon Rectum* 1978;21:98–100.
76. Reasbeck PG, Rice ML, Herbison GP. Nasogastric intubation after intestinal resection. *Surg Gynecol Obstet* 1984;158:354–8.
77. Argov S, Goldstein I, Barzilai A. Is routine use of the nasogastric tube justified in upper abdominal surgery? *Am J Surg* 1980;139:849–50.
78. Merad F, Yahchouchi E, Hay JM, et al. Prophylactic abdominal drainage after elective colonic resection and suprapromontory anastomosis: a multicenter study controlled by randomization. *French Associations for Surgical Research. Arch Surg* 1998;133:309–14.
79. Yates JL. An experimental study of the local effects of peritoneal drainage. *Surg Gynecol Obstet* 1905;1:473.
80. Berliner SD, Burson LC, Lear PE. Use and abuse of intraperitoneal drains in colon surgery. *Arch Surg* 1964;89:686–9.

81. Merad F, Hay JM, Fingerhut A, et al. Is prophylactic pelvic drainage useful after elective rectal or anal anastomosis? A multicenter controlled randomized trial. French Association for Surgical Research. *Surgery* 1999;125:529–35.
82. Manz CW, LaTendresse C, Sako Y. The detrimental effects of drains on colonic anastomoses: an experimental study. *Dis Colon Rectum* 1970;13:17–25.
83. Sailer M, Fuchs KH, Fein M, Thiede A. Randomized clinical trial comparing quality of life after straight and pouch coloanal reconstruction. *Br J Surg* 2002;89:1108–17.
84. Ashraf SQ, Burns EM, Jani A, et al. The economic impact of anastomotic leakage after anterior resections in English NHS hospitals: are we adequately remunerating them? *Colorectal Dis* 2013;15:e190–8.
85. Semm N. Enteroraphy: its history, technic and present status. *JAMA* 1893;21:215.

*Acknowledgments*

Figure 1 Carol Donner  
Figures 2, 5, 6, 7, and 9 through 12 Tom Moore  
Figures 3, 4, and 8 Christine Kenney  
Figure 13 Courtesy of Martijn Gosselink, Oxford Colorectal Centre, Oxford, UK.