

# Group B Streptococcal Cellulitis-Adenitis Syndrome in Infants: Insights From 24 Years of Experience

Ana Del Valle Penella,<sup>1</sup> Christopher C. Pretorius,<sup>2</sup> Carol J. Baker,<sup>3</sup> Marcia A. Rench,<sup>1</sup> Catherine Mary Healy,<sup>1</sup> and Morven S. Edwards<sup>1</sup>

<sup>1</sup>Department of Pediatrics, Baylor College of Medicine, Houston, Texas, USA,

<sup>2</sup>Department of Pediatrics, Kaiser Permanente Medicine, Mid-Atlantic Permanente Medical Group, Washington, DC, USA, and <sup>3</sup>Department of Pediatrics, University of Texas Health Science Center, McGovern Medical School, Houston, Texas, USA

This series of 28 infants with group B streptococcal (GBS) cellulitis-adenitis from a single institution over 24 years offers insights important to the early recognition, spectrum of findings, and optimal management of this rare manifestation of invasive GBS disease.

**Key words:** bacteremia; cellulitis-adenitis; group B *Streptococcus*; neonatal sepsis.

Group B *Streptococcus* (GBS) remains the most common pathogen causing invasive bacterial infection and its associated substantial morbidity in early infancy [1]. Cellulitis-adenitis syndrome is a rare manifestation of GBS infection that usually presents as late-onset disease. The cutaneous findings often are the initial sign of invasive infection and usually are associated with bacteremia and occasionally with meningitis [2–4]. The syndrome presents as cellulitis with or without adenitis and as isolated adenitis, most often affecting the head and neck, possibly due to its proximity to colonized mucosa [3, 4].

We present two infants with rapidly progressive cellulitis-adenitis and a 24-year review of the syndrome at a single referral hospital to offer insights into the early recognition and optimal management of this rare but clinically important entity.

## METHODS

Infants diagnosed with GBS cellulitis-adenitis syndrome who were hospitalized at Texas Children's Hospital, Houston, TX,

Received 1 February 2022; editorial decision 6 April 2022; accepted 18 April 2022; published online 10 May 2022.

Corresponding Author: Morven S. Edwards, MD, Texas Children's Hospital, Feigin Tower, 1102 Bates Street, Suite 1120, Houston, TX 77030, USA. E-mail: [morvene@bcm.edu](mailto:morvene@bcm.edu)

**Journal of the Pediatric Infectious Diseases Society** 2022;11(8):375–8

© The Author(s) 2022. Published by Oxford University Press on behalf of The Journal of the Pediatric Infectious Diseases Society. All rights reserved. For permissions, please e-mail: [journals.permissions@oup.com](mailto:journals.permissions@oup.com).

<https://doi.org/10.1093/jpids/piac033>

USA from January 1997 through December 2020 were identified by review of the Streptococcal Immunology Laboratory GBS database. Hospital microbiology and Infectious Disease consultation records were reviewed to confirm that all cases were included in the database. Permission to conduct the study was obtained from the Baylor College of Medicine Institutional Review Board for Human Research.

Invasive GBS disease was defined as isolation of GBS from blood or cerebrospinal fluid (CSF). The GBS serotype was determined using a modification of the Lancefield capillary precipitin method [5] and the Strep-B-Latex rapid agglutination method (Statens Serum Institut, Copenhagen, Denmark) according to the manufacturer's instructions.

## ILLUSTRATIVE CASES

### Case 1

A 3-week-old infant born at 35 weeks' gestation presented with 6 hours of erythema of the suprapubic and inguinal area. He was mottled, with erythema with purplish hue, tenderness, and induration of the skin of the lower abdomen, the left labia, and proximal thigh without palpable adenopathy. Abdominal ultrasound revealed prominent lymph nodes in the left inguinal region. Ampicillin, gentamicin, and vancomycin were initiated.

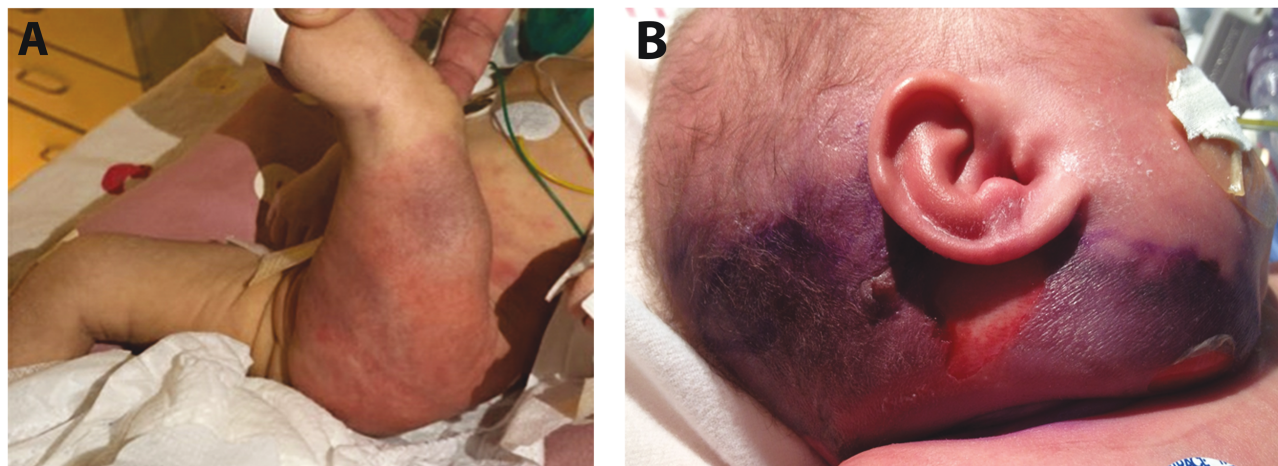
Several hours after admission, the erythema involved the entire left buttock with areas of delayed capillary refill, prompting concern for necrotizing fasciitis (Figure 1A). Antibiotics were modified to include coverage for gram-negative and anaerobic pathogens. The surgery service, consulted to assess for possible intervention, recommended ongoing medical therapy.

Marked improvement of skin findings was apparent 24 hours after initiation of therapy. The blood culture grew GBS, type IV; CSF was sterile. Ampicillin monotherapy was initiated on hospital day 3. All signs of illness were resolved by hospital day 6 and the infant was discharged after completing 10 days of antibiotics.

### Case 2

A 10-week-old former 27 weeks' gestation infant had been home for 2 weeks when he developed fussiness and, several hours later, right submandibular erythema and apnea. Upon evaluation, he was hypoxemic with an area of swelling, ecchymosis, and denuded skin inferior to the right mandible (Figure 1B). No adenitis was appreciated. He required endotracheal intubation and fluid and pressure support. Vancomycin, cefepime, and acyclovir were initiated.

On hospital day 2, upon confirmation of GBS in blood and CSF, therapy was changed to ampicillin and gentamicin,



**Figure 1.** Extensive cellulitis involving the left thigh and buttock (A) and submandibular and postauricular areas (B).

and then to penicillin (450 000 units/kg/day) to complete a 21-day course that was complicated by renal failure and cerebral infarct. The neck wound developed an eschar that improved with local care. He was discharged home after a 9 weeks' hospitalization.

## RESULTS

Twenty-eight infants had GBS cellulitis-adenitis syndrome. All had GBS bacteremia. Fifteen were male and 12 (43%) were Hispanic, 11 (39%) Caucasian, 4 (14%) Black, and 1 Asian (4%) (Table 1). The median age at presentation was 43 (mean 51,

**Table 1. Features of GBS Cellulitis-Adenitis Syndrome**

Location	Clinical Expression	Year	Age (days)	Gender	GA (weeks)	GBS Serotype	Definitive Therapy	Duration of Therapy (days)
Face	C	2017	39	F	36	ND	PCN G	14
Periorbital	C	1997	102	M	FT	III	PCN G	10
	C	2001	109	M	28	III	CTX	10
Periauricular	C	1998	21	M	36	Ia	PCN G	10
	C	2009	99	M	27	Ib	PCN G	10
	C-A	1998	34	M	36	Ia	PCN G	10
	C-A	2009	61	F	27	III	PCN G	21
Submandibular	C	1998	43	M	FT	III	PCN G	10
	C	1998	93	M	25	III	PCN G	10
	C	1999	50	F	FT	III	AMP/gentamicin	10
	C	2013	75	M	27	ND	PCN G	21 <sup>a</sup>
	C-A	2000	85	M	27	Ia	PCN G	10
	C-A	2008	34	M	37	III	PCN G	10
	C-A	2008	51	M	33	III	PCN G	10
	C-A	2009	84	F	29	III	PCN G	10
	C-A	2013	26	M	39	III	PCN G	10
Cervical	A	1997	27	F	FT	Ia	PCN G	10
	C-A	2001	71	M	38	III	CTX/amoxicillin clavulanate	10
	C-A	2009	42	F	33	III	PCN G	10
	C-A	2014	34	M	39	ND	PCN G	10
	C-A	2016	48	M	FT	III	PCN G	11
Inguinal/abdomen	C	1999	34	F	32	III	PCN G	14
	C	2020	21	F	36	IV	AMP	10
Inguinal	C	2002	55	F	31	Ib	AMP	21 <sup>a</sup>
	C	2019	38	F	38	III	PCN G	10
	C-A	2002	16	F	FT	III	PCN G	10
	C-A	2015	37	F	40	Ia	PCN G	10
	C-A	2020	2	F	37	IV	PCN G	21 <sup>a</sup>

Abbreviations: A, adenitis; AMP, ampicillin; C, cellulitis; C-A, cellulitis-adenitis; CTX, cefotaxime; FT, full-term; GA, gestational age; ND, not determined; PCN, penicillin.

<sup>a</sup>Patients treated for confirmed or suspected meningitis.

range 2-109) days. Fifteen infants were premature, including 10 born at 28-36 weeks' and 5 at <28 weeks' gestation. Eleven infants had low birth weight, with 5 weighing <2500 g, 5 <1500 g, and 1 weighing <1000 g. Of the 21 mothers who had GBS colonization status determined, 10 were positive.

Twenty-three (82%) infections were late-onset, 4 (14%) late, late-onset, and 1 (4%) early-onset. Most infants (89%) had signs of infection for less than 24 hours before the presentation, with irritability (86%) most often reported. Additional findings reported are summarized in the [Supplemental table](#).

At initial evaluation, 18 infants had fever and 2 were hypothermic. Cellulitis was identified for 25 infants while 2 developed cutaneous findings during hospitalization and one had adenitis alone. A WBC within normal range was noted in 18 infants and leukopenia in 8. Volume resuscitation was required in 13 infants and 4 required pressor support.

Fourteen infants were diagnosed with cellulitis-adenitis, 13 with cellulitis alone, and 1 with adenitis alone. The face or neck were most often affected (75%) with the submandibular region (43%) predominating, followed by cervical (24%), periauricular (19%), periorbital (10%), and facial (5%) areas. The inguinal area was involved in 25% of infants, with or without abdominal extension. Twenty-six infants had CSF obtained and 2 had meningitis. Of 25 infants for whom the serotype of GBS was identified, type III (64%) was the most common, followed by Ia (20%), Ib (8%), and IV (8%).

All infants initially received broad-spectrum antibiotics. Definitive therapy in most infants was penicillin G (82%) or ampicillin (7%) monotherapy for a median duration of 10 days. Among the 4 infants treated for 21 days, 2 had confirmed and 1 had suspected meningitis. Cellulitis resolved within a median of 4 (range 2-10) days after initiation of antimicrobials. At the time of discharge, all except one infant who did not have meningitis (case 2) had fully recovered without apparent sequelae. One infant with meningitis suffered a cavernous venous thrombosis and two suffered strokes, one with resultant left hemiparesis.

## DISCUSSION

Our experience with GBS cellulitis-adenitis syndrome over 24 years at a single institution reveals insights important to enhancing recognition of this rare entity and to optimizing outcomes. The entity was initially designated "facial cellulitis" and "submandibular cellulitis" in 1981 [6, 7], and Baker in 1982 [4] first described inguinal site involvement. The rarity of this entity is apparent in the small number of infants identified at our quaternary referral hospital. The number of infants identified varied from year to year, with a gap as long as 4 years with no cases to as many as 4 per year.

GBS cellulitis-adenitis syndrome occurs more commonly in males, premature and low birthweight infants and as late-onset disease. Most infections are not as severe as our two illustrative cases. Regardless of severity, infants almost uniformly presented

within 24 hours of developing nonspecific signs of systemic infection, mainly irritability and often but not always fever. Fewer than one-half of caregivers noted swelling and/or redness of the infants' skin before the presentation. In most infants, these findings were noted during the initial evaluation, but cutaneous findings were not evident until subsequent evaluation in two. Frequent and complete physical examinations should be conducted in infants presenting with fever and/or irritability with no apparent focal findings.

The most common presentation of the cellulitis-adenitis syndrome is cellulitis with adenitis, with only one infant in our series having adenitis alone. Adenitis alone is uncommon but is reported [4]. Our determination of adenitis was by the physical finding of palpably enlarged lymph nodes. Even so, and as in our first case, infants without adenitis clinically can have enlarged regional lymph nodes upon imaging. Necrotizing fasciitis was a concern in both our illustrative cases; however, surgical intervention was not required and the infants recovered, confirming lack of fascial involvement. We identified no cases of necrotizing fasciitis over 24 years; however, this is reported and should be considered [3]. We believe that the spectrum of this syndrome is a continuum that ranges from a mild erythema to extensive or hemorrhagic cellulitis and, rarely, to necrotizing fasciitis. Adenitis is invariably present but, in many infants, not appreciated by clinical examination.

The most often affected site is the face, especially the submandibular region. The inguinal region was affected in one-fourth of our infants, emphasizing the importance of careful examination of this area. Colonization of the nasopharyngeal mucosa with its proximity to the face and neck is a potential source for the development of bacteremia and subsequent involvement of the soft tissue [6, 8]. Ipsilateral otitis media could also serve as an initial source of infection [4], as could a gastrointestinal source, with bacterial translocation, in infants with gastrointestinal symptoms [9].

To our knowledge, only two cases are reported of an infant with cellulitis-adenitis without associated bacteremia [4, 10]. Our infants all had bacteremia and two had confirmed meningitis. Therefore, it is imperative for optimal management to obtain CSF studies. Blood culture allows for prompt identification of the organism and for narrowing of antimicrobial therapy while CSF evaluation helps to determine treatment duration. Therapy with penicillin alone is appropriate once culture results are available. A treatment duration of 10 days is sufficient for most infants without meningitis. Limiting antimicrobial duration as feasible is important to minimizing adverse effects, such as marrow suppression, development of resistance, and impact on the neonatal microbiome [11].

The most common GBS serotype was type III, consistent with a previous report [4]. Given the ability of GBS to horizontally transfer DNA among strains, the emergence of type IV as a cause of invasive infant disease is not surprising [12, 13]. Two

type IV isolates were identified in 2020, highlighting the importance of including this serotype in candidate GBS vaccines.

Although rare, invasive GBS disease can present as cellulitis-adenitis, occasionally associated with meningitis or necrotizing fasciitis. A high index of suspicion for this syndrome and its continuum of findings is key to properly identifying and optimally managing this infection.

### Supplementary Data

Supplementary materials are available at the *Journal of the Pediatric Infectious Diseases Society* online.

### Notes

**Acknowledgments.** The authors thank Dr. Charleta Guillory for allowing us to report her patient (case 1) and Robin D. Schroeder for her help with manuscript preparation.

**Financial support.** None.

**Potential conflicts of interest.** None of the authors report any conflict of interest. All authors have submitted the ICMJE Form for Potential Conflicts of Interest. Conflicts that the editors consider relevant to the content of the manuscript have been disclosed.

### References

1. Nanduri SA, Petit S, Smelser C, et al. Epidemiology of invasive early-onset and late-onset group B streptococcal disease in the United States, 2006 to 2015: multistate laboratory and population-based surveillance. *JAMA Pediatr* **2019**; 173:224–33.
2. Albany EA, Baker CJ. Is lumbar puncture necessary to exclude meningitis in neonates and young infants: lessons from the group B *Streptococcus* cellulitis-adenitis syndrome. *Pediatrics* **1998**; 102:984–6.
3. Wojtera M, Cheng H, Fiorini K, et al. Group B streptococcal cellulitis and necrotizing fasciitis in infants. A systematic review. *Pediatr Infect Dis J* **2018**; 37:e241–5.
4. Baker CJ. Group B streptococcal cellulitis-adenitis in infants. *Am J Dis Child* **1982**; 136:631–3.
5. Lancefield R. A serologic differentiation of specific types of bovine hemolytic streptococci (group B). *J Exp Med* **1934**; 59:441–58.
6. Patamasuon P, Siegel JD, McCracken GH Jr. Streptococcal submandibular cellulitis in young infants. *Pediatrics* **1981**; 67:378–80.
7. Hauger SB. Facial cellulitis: an early indicator of group B streptococcal bacteremia. *Pediatrics* **1981**; 67:376–7.
8. Pickett KC, Gallaher KJ. Facial submandibular cellulitis associated with late-onset group B streptococcal infection. *Adv Neonatal Care* **2004**; 4:20–5.
9. Kim DS, Agwu AV, Baker CJ. Neck swelling and fussiness in an 8-week-old infant. *Pediatr Rev* **2021**; 42:332–5.
10. Mittal MK, Shah SS, Friedlaender EY. Group B streptococcal cellulitis in infancy. *Pediatr Emerg Care* **2007**; 23:324–5.
11. Bender JM, Li F, Purswani H, et al. Early exposure to antibiotics in the neonatal intensive care unit alters the taxonomic and functional infant gut microbiome. *J Matern Fetal Neonatal Med* **2021**; 34:3335–43.
12. Teatero S, Ferrieri P, Fittipaldi N. Serotype IV sequence type 468 group B *Streptococcus* neonatal invasive disease, Minnesota, USA. *Emerg Infect Dis* **2016**; 22:1937–40.
13. Campisi E, Rinaudo CD, Donati C, et al. Serotype IV *Streptococcus agalactiae* ST-452 has arisen from large genomic recombination events between CC23 and the hypervirulent CC17 lineages. *Sci Rep* **2016**; 6:29799.