

## Efficacy of Continuous Cleansing with Teicoplanin on Post-CABG Methicillin-resistant Staphylococcus Aureus (MRSA) Mediastinitis: Report of a Case

Akira Sezai, MD, Motomi Shiono, MD, Tatsuya Inoue, MD, Mitsumasa Hata, MD, Mitsuru Iida, MD, Tetsuya Niino, MD, Akira Saito, MD, Tsutomu Hattori, MD, Shinji Wakui, MD, Masao Soeda, MD, Nanao Negishi, MD, and Yukiyasu Sezai, MD

**The patient was a 48-year-old male who was diagnosed with unstable angina. He had worsening cardiogenic shock during coronary angiography. Emergency coronary artery bypass grafting (CABG) was performed. He had a methicillin-resistant Staphylococcus aureus (MRSA) mediastinitis on day 22 after CABG. Drains were placed in the anterior mediastinum, left thoracic cavity, and abscess cavity, and another drain was placed in the mediastinal space for continuous cleansing with povidone iodine, oxydol. For antibiotics, teicoplanin (TEIC) was administered intravenously and to the local site via the cleansing drain for about one month. No MRSA was detected by culture in discharges from the mediastinal drain. Inflammatory findings were improved, and the patient was discharged and resumed everyday life without recurrence of inflammation as of eight months.**

**Although the number of cases of MRSA mediastinitis is small and accumulation of cases is necessary to investigate therapeutic methods and selection of antibiotics, our department will select closed continuous cleansing and TEIC for antibiotics as the first choice for MRSA mediastinitis, and accumulate cases to investigate its efficacy. (Ann Thorac Cardiovasc Surg 2004; 10: 191-4)**

**Key words:** teicoplanin, MRSA, mediastinitis, cardiac surgery

### Introduction

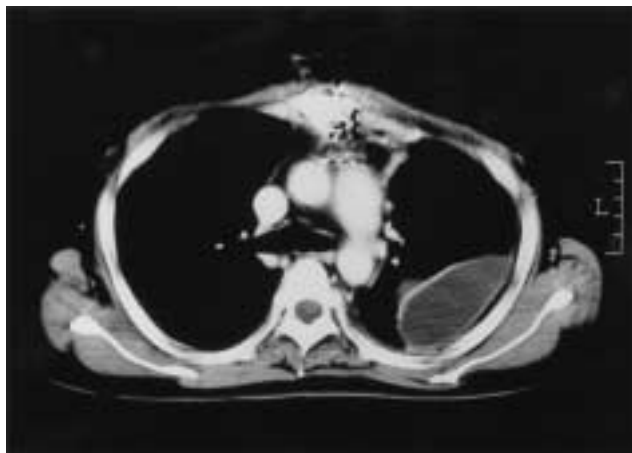
Although the frequency of developing mediastinitis after cardiac surgery is not high, it is still a serious complication. Particularly, methicillin-resistant Staphylococcus aureus (MRSA)-induced mediastinitis is resistant to drugs and intractable, affecting the prognosis.<sup>1,2)</sup> Here, we report a patient with MRSA mediastinitis that developed after coronary artery bypass grafting (CABG) who was treated with continuous cleansing with povidone iodine, oxydol, and teicoplanin (TEIC), and exhibited a good outcome.

*From Department of Cardiovascular Surgery, Nihon University School of Medicine, Tokyo, Japan*

Received July 7, 2003; accepted for publication December 22, 2003. Address reprint requests to Akira Sezai, MD: Department of Cardiovascular Surgery, Nihon University School of Medicine, 30-1 Oyaguchi-kamimachi, Itabashi-ku, Tokyo 173-8610, Japan.

### Case Report

The patient was a 48-year-old male who visited the cardiology department of our hospital with the chief complaint of chest pain. The patient was diagnosed with angina and admitted for examination. He had fever and cough for one month, and had been diagnosed with acute bronchitis and treated with an oral cephem, cefcapene pivoxil hydrochloride (CEPN-PI), 300 mg/day, by his doctor. The patient also received interferon therapy for chronic hepatitis C eight years ago. On coronary angiography (CAG), 99% stenosis of the left coronary artery main trunk (LMT) was recognized. Since systolic aortic pressure dropped 90 mmHg during the CAG, the patient was supported by intra-aortic balloon pumping (IABP) and referred to our department. Emergency CABG (left anterior descending artery; left internal thoracic artery, diagonalis; radial artery, high lateral; saphenous vein) was performed. Intravenous administration of a penicillin com-



**Fig. 1.** Chest CT at the time of the onset of mediastinitis and pyothorax.

bination, sulbactam (SBT)/ampicillin (ABPC) (3.0 g/day), and a first generation cephem, cefazolin (CEZ) (2.0 g/day), began on the day of surgery. The postoperative course was uneventful. IABP was removed on the first day after surgery and the ventilator was weaned on day 2 after surgery. However, severe coughing occurred after weaning from the respirator and coughing could not be controlled by antitussives. Sternal separation and serous discharges from the wound were noted after day 10 and 11 after surgery, respectively. No bacteria were detected in the discharges. Since chest CT showed remarkable separation of the sternum, the sternum was re-sutured on day 16 after surgery. A third generation cephem, ceftazidime (CAZ) (2.0 g/day), and SBT/ABPC (3.0 g/day) were administered intravenously after surgery. The respiratory condition was stable after surgery, but a fever of 38°C to 39°C developed. Blood culture, stool, sputum and wound discharges detected MRSA. Vancomycin hydrochloride (VCM) (2.0 g/day) was administered intravenously from day 6 after the second surgery. Chest CT on day 7 after the second surgery showed low-density areas in the mediastinal space and left thoracic cavity (Fig. 1). A diagnosis of mediastinitis and pyothorax was made, and thoracic cavity drainage was performed for pyothorax. MRSA was detected in discharges from the thoracic drainage. On day 13 after the second surgery, debridement of the mediastinum was performed and cleaned with povidone iodine and oxydol, and 1.0 g of VCM was dispersed for mediastinitis in the operation room. For pyothorax, the abscess cavity was debrided, cleaned with povidone iodine and oxydol, and 1.0 g of VCM was dispersed. Drains were placed in the anterior mediastinum, left thoracic cavity, and an abscess cavity, and a drain for

continuous cleansing was placed in the mediastinal space. Closure of the sternum using a metal wire was difficult due to inflammatory liquefaction of the sternum, and the sternum was closed using a sternal band. MRSA was detected in the mediastinum and sternum, but not in the abscess cavity or left thoracic cavity. For continuous cleansing, 500 ml of physiological saline supplemented with 2 ml of 10% povidone iodine and 500 ml of physiological saline supplemented with 2 ml of a peroxide product, oxydol, were used at 40 ml/hr every six hours each. For antibiotics, VCM (2.0 g/day) and arbekacin (ABK) (200 mg/day) were administered intravenously. Drains for drainage were continuously aspirated with negative pressure at 10 cmH<sub>2</sub>O, and the volumes of cleansing and drainage were strictly managed. In addition, the absence of accumulation of cleansing solution in the mediastinum and thoracic cavity was confirmed at any time by chest X-ray examination. Although WBC and CRP decreased, MRSA was still detected in discharges from the mediastinal drainage, and the drug was changed to intravenous administration of TEIC (400 mg/day) on day 15 after the third surgery. In addition, 100 ml of physiological saline containing 200 mg of TEIC was administered to the local site via the cleansing drain for 15 minutes twice a day, and the drain was clamped for 30 minutes after administration. Since the thoracic cavity drain was obstructed on day 28 after the third surgery, the drain was removed and continuous cleansing with povidone iodine and oxydol was discontinued, but local administration of TEIC was continued. MRSA was not detected by culture of discharges from the mediastinal drain obtained on days 38 and 41 after the third surgery. Local administration of TEIC was continued, and the mediastinal drain was removed on day 45 after the third surgery. No MRSA was detected by culture in discharges from the mediastinal drain at the time of removal. TEIC, 400 mg/day, was administered intravenously for 12 days after removal of the drain. No thyroid dysfunction was detected during the course. Creatinine (Cr) was increased to 1.5 mg/dl during administration of VCM, but renal function did not decrease after TEIC administration. Inflammatory findings were improved, and the patient was discharged on day 70 after the third surgery. The patient resumed everyday life without recurrence of inflammation as of eight months (Fig. 2).

## Discussion

The frequency of MRSA infection has rapidly increased

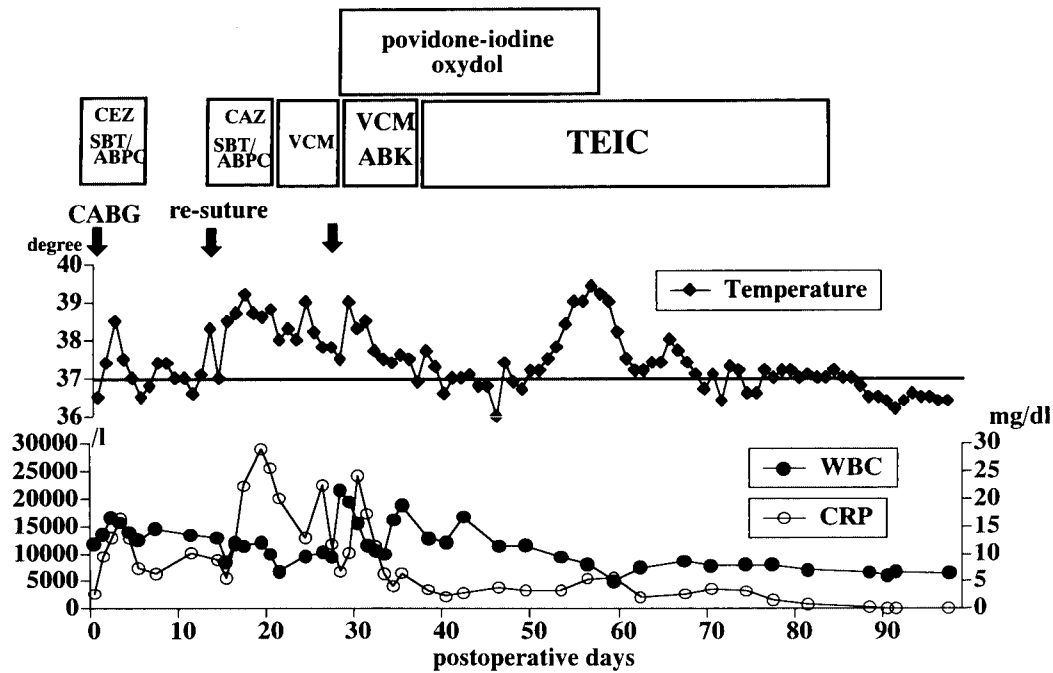


Fig. 2. Course after coronary artery bypass grafting (CABG).

since the latter half of the 1980's due to overuse of cepems. A vancomycin-resistant enterococci (VRE) with low sensitivity to VCM has been reported in recent years. The cause of MRSA mediastinitis in this patient was considered as follows: an oral cephem, CEPN-PI, was administered for one month before surgery, coughing intractable by antitussives continued after CABG and separated the sternum, disseminating inflammation, and the sternum was re-closed due to sternal separation, thus these events may have lead to MRSA mediastinitis and pyothorax.

Therapy for mediastinitis includes closed continuous cleansing, open continuous cleansing, and pedicle flap with the major pectoral muscle and omentum. Since the omentum is rich in blood vessels and lymph vessels, an omental flap is very effective for infected lesions. However, the omental flap is selected only for intractable cases in our institution because reaching the heart is difficult when heart surgery is repeated and inflammation may disseminate to the abdominal region. Since this patient was young and CABG may be repeated in the future, closed continuous cleansing was selected in consideration of difficulty in repeated CABG and use of the gastroepiploic artery. The drain for cleansing was inserted from the lower region in consideration of possible injury of the right internal thoracic artery, which is used in the second surgery, and the left internal thoracic artery used for CABG in this surgery.

MRSA severely destroys tissues and is intractable. The sternum was severely destroyed during the short period after the onset in this patient, showing the importance of early appropriate therapy. In continuous cleansing with Isodine, the concentration is considered important because of problems of Isodine-induced shock and hypothyroidism,<sup>3,4)</sup> and a low concentration was selected for this patient. Other than cleansing with Isodine, cleansing with super acidic water has been reported in recent years, but the effect does not persist, and it is readily converted to water when coming in contact with blood components. Therefore, the continuous cleansing effect of super acidic water is considered due to water rather than super acidic water itself. Oxydol is less toxic and exhibits a cleansing effect by releasing oxygen bubbles upon degradation. In addition, the antibacterial spectrum of oxydol is wide and effective for MRSA. Therefore, Isodine and oxydol were concomitantly used for continuous cleansing in this case.

Antibiotics should be carefully selected because it closely related to complication and the prognosis. Three types of antibiotics; VCM, ABK, and TEIC, are reported to be effective for MRSA. Mediastinitis requires long-term administration of antibiotics, and MRSA infection requires further longer administration, increasing the risk of developing renal dysfunction, auditory disorder, and red man syndrome, which are reported to be adverse effects of VCM. TEIC is a glycopeptide antibiotic with antibacterial activity for gram-positive bacteria includ-

ing MRSA. Compared to VCM with a similar chemical structure, the half-life of TEIC is longer and adverse events such as red man syndrome occur less frequently.<sup>5,6)</sup> To our knowledge, there has been no report of the efficacy of TEIC for MRSA mediastinitis. There are some reports of local administration of VCM,<sup>7)</sup> but no report of local cleansing with TEIC was found. It is difficult to conclude whether the intravenous administration of TEIC or the local administration was effective as it is unknown whether or not only the intravenously administered TEIC treated the infected tissue. However the combination with the local administration is considered more effective. In the future, we will accumulate cases to investigate.

Continuous cleansing with povidone iodine and oxydol and intravenous administration of VCM during the early stage after the onset of MRSA mediastinitis improved inflammation. However, negative conversion of MRSA could not be obtained, and mild renal dysfunction (Cr: 1.5 mg/dl) was recognized. Therefore, the drug was changed to intravenous administration of TEIC and cleansing of the mediastinum with TEIC was additionally performed, and a good outcome was obtained.

Although the number of cases of MRSA mediastinitis is small and accumulation of cases is necessary to investigate therapeutic methods and selection of antibiotics, our facility will select closed continuous cleansing and

TEIC for antibiotics as the first choice for MRSA mediastinitis, and accumulate cases to investigate its efficacy.

## References

1. Borger MA, Rao V, Weisel RD, et al. Deep sternal wound infection: risk factors and outcomes. *Ann Thorac Surg* 1998; **65**: 1050–6.
2. Baskett RJF, MacDougall CE, Ross DB. Is mediastinitis a preventable complication? A 10-year review. *Ann Thorac Surg* 1999; **67**: 462–5.
3. Glick PL, Guglielmo BJ, Tranbaugh RF, Turley K. Iodine toxicity in a patient treated by continuous povidone-iodine mediastinal irrigation. *Ann Thorac Surg* 1985; **39**: 478–80.
4. Aiba M, Ninomiya J, Furuya K, et al. Induction of a critical elevation of povidone-iodine absorption in the treatment of a burn patient: report of a case. *Surg Today* 1999; **29**: 157–9.
5. Sahai J, Healy DP, Shelton MJ, Miller JS, Ruberg SJ, Polk R. Comparison of vancomycin- and teicoplanin-induced histamine release and “red man syndrome”. *Antimicrob Agents Chemother* 1990; **34**: 765–9.
6. Verbist L, Tjandramaga B, Hendrickx B, et al. In vitro activity and human pharmacokinetics of teicoplanin. *Antimicrob Agents Chemother* 1984; **26**: 881–6.
7. Vander Salm TJ, Okike ON, Psaque MK, et al. Reduction of sternal infection by application of topical vancomycin. *J Thorac Cardiovasc Surg* 1989; **98**: 618–22.